

Evaluation of the Outcomes of One-Site Combined Phacotrabeculectomy Using Sutureless Tunnel Technique Without Peripheral Iridectomy in Open Angle Glaucoma Patients

Yadollah Eslami, MD¹ • Massood Mohammadi, MD² • Ghasem Fakhraie, MD¹
Sajad Eslami, BSc³ • Reza Zarei, MD¹ • Sasan Moghimi, MD¹

Abstract

Purpose: To evaluate the results of one-site phacotrabeculectomy using sutureless tunnel technique without peripheral iridectomy (no-PI) in glaucoma patients with cataract

Methods: A retrospective study of cases which has been recorded of patients who have had one-site no-PI phacotrabeculectomy using sutureless tunnel technique. We collected pre- and postoperative data in all patients including best corrected visual acuity (BCVA), intraocular pressure (IOP) and the number of anti-glaucoma medications. Surgical success was defined as the final IOP < 21 mmHg and ≥ 20% reduction from preoperative IOP for criteria A, and final IOP < 18 mmHg and ≥ 30% reduction from baseline for criteria B. Success was further divided into incomplete when anti-glaucoma medications were needed postoperatively and complete when no anti-glaucoma medications were used).

Results: Forty eight eyes of 48 patients were recruited into the study. Mean (SD) age of the patients was 70.1 (8.8) years. Mean value of IOP before surgery was 27.1 (SD=6.4), and it decreased significantly at all follow-up visits after surgery (p<0.001). At final follow-up, mean IOP was 15.8 (SD=3.7) mmHg (p<0.001). Mean number of anti-glaucoma medications decreased from 2.6 (SD=1.2) preoperatively to 0.7 (SD=1.4) at the last follow-up visit (p<0.001). Mean logMAR BCVA improved from preoperative level of 0.97 to 0.33 at the final follow-up visit (p<0.001). For criteria A, qualified and complete success rates were 81.2% and 64.6%, and for criteria B these rates were 66.7% and 56.2%, respectively.

Conclusion: One-site no-PI sutureless tunnel phacotrabeculectomy leads to a significant reduction in IOP and helps to improve visual acuity in glaucoma patients with cataract.

Keywords: Phacotrabeculectomy, Sutureless Tunnel Technique, Peripheral Iridectomy, Glaucoma, Cataract

Iranian Journal of Ophthalmology 2014;26(3):150-4 © 2014 by the Iranian Society of Ophthalmology

1. Associate Professor of Ophthalmology, Department of Ophthalmology, Eye Research Center, Farabi Eye Hospital, Tehran University of Medical Sciences, Tehran, Iran
2. Assistant Professor of Ophthalmology, Department of Ophthalmology, Eye Research Center, Farabi Eye Hospital, Tehran University of Medical Sciences, Tehran, Iran
3. Glaucoma Service, Farabi Eye Hospital, Tehran University of Medical Sciences, Tehran, Iran

Received: October 22, 2014

Accepted: November 22, 2014

Correspondence to: Massood Mohammadi, MD

Assistant Professor of Ophthalmology, Department of Ophthalmology, Eye Research Center, Farabi Eye Hospital, Tehran University of Medical Sciences, Tehran, Iran, Email: massood.m@gmail.com

"We state that our only interest is academic and we have no financial interest in this publication."

Introduction

Cataract and glaucoma are both age-related diseases, so concurrent existence of cataract and glaucoma is common in the elderly population.

Combined phacoemulsification and trabeculectomy is an option in the management of concurrent cataract and glaucoma.¹⁻³ It is performed either with the two procedures (phacoemulsification and trabeculectomy) through the same incision (one-site) or through separate incisions (two-sites).

Several modifications of the phacotrabeculectomy procedure have been introduced.⁴⁻⁸ One of these modifications, one-site sutureless tunnel (no-stitch) technique, has been reported to be effective and comparable to other techniques of phacotrabeculectomy.⁸

It has been suggested that in trabeculectomy and phacotrabeculectomy surgeries eliminating peripheral iridectomy (PI) may decrease the inflammation and hyphema associated with these procedures.⁹⁻¹³ The published studies have not shown any adverse effect of avoiding PI on the outcome of the phacotrabeculectomy or trabeculectomy.⁹⁻¹³ On the other hand, in sutureless tunnel technique, performing PI through a scleral tunnel is somewhat difficult and requires manipulation of the scleral flap.¹³

In this study, we report on the results of one-site no-PI phacotrabeculectomy using the sutureless tunnel technique in our patients with concurrent cataract and glaucoma.

Methods

From September 2009 to September 2011, patients with concomitant glaucoma and cataract that underwent phacotrabeculectomy using sutureless tunnel technique without PI were recruited into the study. Only patients with at least six months of postoperative follow-up were included in the study. All participants gave written informed consent for inclusion in the study. The study protocol was approved by the local Medical Ethics Committee and adhered to the tenets of the declaration of Helsinki.

Consecutive patients with chronic open-angle glaucoma [primary open-angle glaucoma (POAG) and exfoliative glaucoma (XFG)] that underwent combined one-site

phacotrabeculectomy using a sutureless tunnel technique without PI. Exclusion criteria were as follows: any previous conjunctival or intraocular surgery, secondary open-angle glaucoma other than XFG.

Preoperatively all patients underwent a complete ophthalmic examination including best corrected visual acuity (BCVA) measurement, slit-lamp biomicroscopy and funduscopy using a +78- diopter lens, Goldmann applanation tonometry and gonioscopy using a Volk 4-mirror gonioscopes under standard conditions. Baseline data were recorded as following: BCVA, intraocular pressure (IOP), the number of anti-glaucoma medications used by the patient. Other information collected before surgery included age, gender, and the diagnostic type of glaucoma.

Postoperative examinations were performed at one day, one week, one month, three months, six months and one year after surgery. Data were collected at each postoperative visit including: BCVA, IOP, number of anti-glaucoma medications and occurrence of any complications.

Surgical success was defined as final IOP <21 mmHg and >20% reduction in IOP from preoperative level (criterion A) without further glaucoma surgery. Criterion B for surgical success was defined as final IOP of <18 mmHg and >30% reduction in IOP from preoperative level without further glaucoma surgery. Success was further defined as complete when these criteria were obtained without any anti-glaucoma medications and incomplete with medical therapy.

Surgical technique

All procedures were performed by one surgeon (Y.E.). Under topical anesthesia with tetracaine 0.5% eyedrops, 0.2 mL of unpreserved lidocaine 2% solution was injected subconjunctivally over the superior rectus insertion, and then superior rectus traction was placed with 4-0 silk suture. Limbal conjunctival peritomy performed at the 12 o'clock position for five mm, and a fornix-based conjunctival flap was fashioned. Two millimeters posterior to the limbus at 12 o'clock position, a partial-thickness tangential scleral incision was made for 3.2 mm. Then with a 2.6-mm crescent knife a half-thickness

scleral tunnel which extended 1 mm into clear cornea was dissected. No antimetabolite was applied. Two limbal paracenteses were made at 10 and 2 o'clock positions. Anterior chamber was entered with 3.2 keratome and anterior chamber was filled by methylcellulose, and then a 5-mm anterior continuous curvilinear capsulorrhexis was performed. The nucleus was removed by phacoemulsification using the chop technique, and a soft acrylic intraocular lens was placed in the bag. Corneoscleral block excision was performed by Kelly punch. The scleral incision was not sutured and watertight suturing of the conjunctiva was performed by two 10-0 nylon wing sutures.

Routine postoperative treatment included ciprofloxacin 0.3% eye drop four times daily and betamethasone 0.1% eye drop (initially every two hours). Ciprofloxacin eye drop was discontinued after 1-2 weeks. Topical betamethasone was tapered over 8-12 weeks.

Statistical analysis

Statistical analysis was performed with SPSS software (version 17; SPSS Inc.). Continuous data were presented in mean and standard deviation (SD) and compared using the Student paired *t*-test or Wilcoxon Signed Ranks test as appropriate. A *p* value of <0.05 was considered statistically significant.

Results

Forty-eight eyes of 48 patients were recruited into the study. Mean age and SD of the patients was 70.1 (8.8) years and they were followed for the average of 11.2 months after surgery. The demographic and clinical characteristics of patients before surgery are shown in table 1.

The mean IOP decreased significantly from baseline of 27.1 (SD=6.4) mmHg at all

postoperative follow-up visits (Figure 1). At the last follow-up visit mean IOP was 15.8 (SD=3.7) (*p*<0.001) that was 41.7% lower from a preoperative level. The mean number of anti-glaucoma medications decreased from baseline [2.6 (SD=1.2)] at all visits after surgery (Figure 2), and reached to 0.7 (SD=1.1) at the final follow-up visit (*p*<0.001).

The mean logMAR BCVA improved from preoperative level of 0.97 (²⁰/₁₈₆ Snellen equivalent) to 0.33 (²⁰/₄₂ Snellen equivalent) at the final follow-up visit, *p*<0.001 (Wilcoxon signed rank test).

Postoperative complications as following were seen: three patients (6.2%) presented early bleb leakage; two patients (4.1%) hyphema; three patients (6.2%) choroidal effusion, and five patients (10.4%) shallow anterior chamber.

During the follow-up period, 11 patients (22.9%) needed needling bleb revision. Needling was not considered as reoperation for glaucoma in the definition of success.

According to our definition of surgical success, the qualified success rate was ³⁹/₄₈ (81.2%) and ³¹/₄₈ (64.6%) using criterion A and B, respectively. The complete success rate was ³²/₄₈ (66.7%) and ²⁷/₄₈ (56.2%) for criteria A and B, respectively.

Of all eyes which were considered failures by the study criteria, one eye had a history of iris incarceration into the sclerostomy. This patient had an early postoperative shallow anterior chamber, and after resolution of shallow AC it was noted that the iris was incarcerated in the sclerostomy. Iris was successfully released from sclerostomy by Nd:YAG laser. This patient needed a needling bleb revision which was not successful for IOP control. Finally this eye needed second trabeculectomy.

Table 1. Demographic and baseline characteristics of the patients

Characteristics	
Gender	
Male (%)	31(64.6)
Female (%)	17(35.4)
Glaucoma diagnosis	
POAG (%)	22(45.8%)
XFG (%)	26(54.2%)
logMAR BCVA (Mean±SD)	0.97±0.6
IOP (Mean±SD) [mmHg]	27.1±6.4
Number of medications (Mean±SD)	2.6±1.2
Vertical cup-disc ratio (Mean±SD)	0.8±0.19
POAG: Primary open-angle glaucoma, XFG: Exfoliation glaucoma, BCVA: Best-corrected visual acuity, IOP: Intraocular pressure	

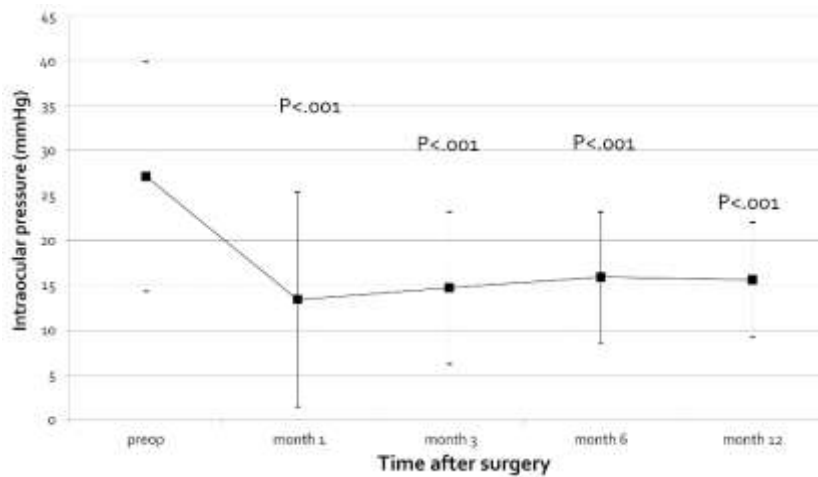


Figure 1. Intraocular pressure before and after surgery. The box and whiskers represent the mean ± 2 SD. The p values (paired *t* test) are for comparison of the intraocular pressure at each postoperative visit with the preoperative visit.

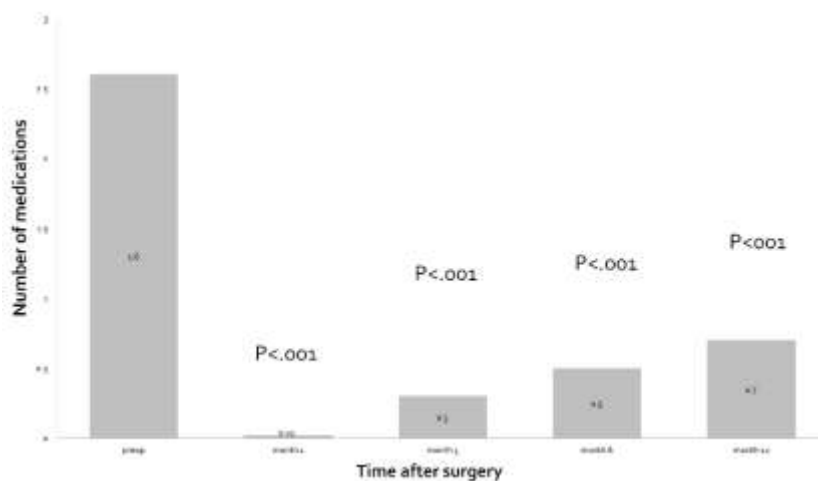


Figure 2. Number of medications before and after surgery. The number within each bar is number of medications in the corresponding visit. The p values (Wilcoxon Signed Ranks test) are for comparison of the mean number of medications at each postoperative visit with the preoperative baseline.

Discussion

Our study showed that no-PI phacotrabeculectomy using the sutureless tunnel technique without antimetabolites is relatively safe and effective in controlling IOP and improving vision of glaucoma patients with cataract.

There are several surgical variations for combined phacoemulsification and trabeculectomy.⁴⁻⁸

Rao et al reported on the results of one-site phacotrabeculectomy without mitomycin C in

glaucoma patients. Trabeculectomy was performed with triangular sutured scleral flaps and PI. Their one-year success (IOP < 21 mmHg without further surgeries) rate was 75% in POAG patients. Mean final IOP was 14.9 mmHg on the average of 0.6 medications in POAG group (average follow-up: 41.7 months).¹⁴ In another study, Budenz et al compared the results of phacotrabeculectomy without antimetabolites, with mitomycin C and with 5-fluorouracil. The trabeculectomy in their

combined procedures was performed with sutured scleral flaps and PI. Last IOP in the no-antimetabolite group was 14.8 mmHg on 0.9 medications (average of 18.4 months of follow-up). According to their definition of failure 10.5% of combined procedures in the no-antimetabolite group 10.3% in the mitomycin C group were considered failed.¹⁵

Comparison of these studies with the results of ours shows that regardless of the surgical technique, no-PI phacotrabeculectomy using sutureless tunnel technique without antimetabolite has comparable success and IOP control rates.

In phacotrabeculectomy avoiding PI may reduce some complications like hyphema and postoperative inflammation and also allowing a shorter surgical time.⁹⁻¹³

In a retrospective study, Shingleton et al reported on the results of no-PI combined phacotrabeculectomy in comparison with PI group. They found no difference in postoperative IOP and visual acuity between the two groups.¹⁰ Other studies found similar outcomes with no-PI phacotrabeculectomy.^{9,11}

In previous no-PI studies, no case of postoperative iris prolapse into the sclerostomy was reported.⁹⁻¹³ In our study, iris incarceration developed in one patient after an episode of shallow anterior chamber. Although incarcerated iris was successfully released with Nd: YAG laser from sclerostomy site, the trabeculectomy finally failed.

We think that in no-PI techniques, to prevent iris incarceration, the fistula should be created in clear cornea as anteriorly as possible to increase the distance between the ostium and the iris.

Our study has several limitations. It is a retrospective chart review study with no control group. Furthermore, the follow-up of our patients was relatively short so the long-term efficacy and safety of the procedure cannot be assessed.

Conclusion

Our study showed that no-PI one-site phacotrabeculectomy using sutureless tunnel technique without antimetabolites effectively reduces IOP and improves vision in patients with concomitant cataract and glaucoma.

References

1. Park HJ, Weitzman M, Caprioli J. Temporal corneal phacoemulsification combined with superior trabeculectomy. A retrospective case-control study. *Arch Ophthalmol* 1997;115(3):318-23.
2. Yu CB, Chong NH, Caesar RH, Boodhoo MG, Condon RW. Long-term results of combined cataract and glaucoma surgery versus trabeculectomy alone in low-risk patients. *J Cataract Refract Surg* 1996;22(3):352-7.
3. Wedrich A, Menapace R, Radax U, Papapanos P. Long-term results of combined trabeculectomy and small incision cataract surgery. *J Cataract Refract Surg* 1995;21(1):49-54.
4. Gregg FM. Phacoemulsification and modified trabeculectomy for managing combined cataracts and glaucoma. *J Cataract Refract Surg* 1992;18(4):362-5.
5. Pasquale LR, Smith SG. Surgical outcome of phacoemulsification combined with the Pearce trabeculectomy in patients with glaucoma. *J Cataract Refract Surg* 1992;18(3):301-5.
6. Gous PN, Roux P. Preliminary report of sutureless phacotrabeculectomy through a modified self-sealing scleral tunnel incision. *J Cataract Refract Surg* 1995;21(2):160-9.
7. Shingleton BJ, Kalina PH. Combined phacoemulsification, intraocular lens implantation, and trabeculectomy with a modified scleral tunnel and single-stitch closure. *J Cataract Refract Surg* 1995;21(5):528-32.
8. Arnold PN. No-stitch phacotrabeculectomy. *J Cataract Refract Surg* 1996;22(2):253-60.
9. Manners TD, Mireskandari K. Phacotrabeculectomy without peripheral iridectomy. *Ophthalmic Surg Lasers* 1999;30(8):631-5.
10. Shingleton BJ, Chaudhry IM, O'Donoghue MW. Phacotrabeculectomy: peripheral iridectomy or no peripheral iridectomy? *J Cataract Refract Surg* 2002;28(6):998-1002.
11. Kaplan-Messas A, Cohen Y, Blumenthal E, Avni I. Trabeculectomy and phaco-trabeculectomy with and without peripheral iridectomy. *Eur J Ophthalmol* 2009;19(2):231-4.
12. de Barros DS, Da Silva RS, Siam GA, Gheith ME, Nunes CM, Lankaranian D. Should an iridectomy be routinely performed as a part of trabeculectomy? Two surgeons' clinical experience. *Eye (Lond)* 2009;23(2):362-7.
13. Eslami Y, Mohammadi M, Khodaparast M, Rahmanikhah E, Zarei R, Moghimi S, et al. Sutureless tunnel trabeculectomy without peripheral iridectomy: a new modification of the conventional trabeculectomy. *Int Ophthalmol* 2012;32(5):449-54.
14. Rao HL, Maheshwari R, Senthil S, Prasad KK, Garudadri CS. Phacotrabeculectomy without mitomycin C in primary angle-closure and open-angle glaucoma. *J Glaucoma* 2011;20(1):57-62.
15. Budenz DL, Pyfer M, Singh K, Gordon J, Piltz-Seymour J, Keates EU. Comparison of phacotrabeculectomy with 5-fluorouracil, mitomycin-C, and without antifibrotic agents. *Ophthalmic Surg Lasers* 1999;30(5):367-74.