

# Efficacy of Autologous Fibrin Glue for Primary Pterygium Surgery with Conjunctival Autograft

Alireza Foroutan, MD<sup>1</sup> • Fariba Beigzadeh, MD<sup>2</sup> • Mohammad Jafar Ghaempanah, MD<sup>3</sup>  
Peyman Eshghi, MD<sup>4</sup> • Naser Amirizadeh, PhD<sup>5</sup> • Hamed Sianati, MD<sup>6</sup> • Pooria Foroutan, MD<sup>7</sup>

---

## Abstract

**Purpose:** To evaluate the efficiency and safety of using autologous fibrin glue for attachment of a conjunctival autograft in primary pterygium surgery

**Methods:** In this prospective interventional case series, 15 eyes from 13 patients with primary nasal pterygium were included for conjunctival autograft surgery. On the operation day, thrombin and fibrinogen were prepared from the patient's own blood in two separate sealed tubes in the blood transfusion center. Autologous fibrin glue was applied over the bare sclera for attachment of the free conjunctival autograft to the surrounding conjunctiva and sclera. The anatomic outcomes of flap, surgical time, recurrence rate, and other complications were evaluated on days 1, 3, and 7 and at months 1, 6, and 9 and 3 year after operation. A patient's pain was evaluated using a 5-point scale from Lim-Bon-Siong et al grading at all visits.

**Results:** Of the 13 patients, 76.9% were male. The mean age of the patients was 37.26±12.61 (SD) years (range 23-60). The mean follow-up period was 34.67±2.96 months (range 25-36). Three eyes (20%) developed autograft retraction that resolved completely with continued eye patching. Two eyes (13.33%) developed total graft dehiscence, and sutures were used for reattachment of the graft in its correct position. Two eyes (13.33%) developed recurrence of pterygium, one of them had already a total graft dehiscence. In 13 eyes (86.66%), the conjunctival grafts were appropriately adhered to the bed and surrounding conjunctiva without suturing in the final visit. In the first postoperative day, ocular pain was recorded as grade 1 in 11 eyes (73.3%), grade 2 in 3 eyes (20%), and grade 3 in 1 eye (6.6%). In all patients, ocular pain disappeared during the 5 days after operation, except for two patients who needed suturing for graft reattachment, in whom ocular pain continued for 2 weeks. No other complications were found during follow-up.

**Conclusion:** This case series suggests that autologous fibrin glue is a safe and useful alternative method for graft fixation in pterygium surgery.

**Keywords:** Autologous Fibrin Glue, Pterygium, Conjunctival Autograft

*Iranian Journal of Ophthalmology 2011;23(1):39-47 © 2011 by the Iranian Society of Ophthalmology*

---

1. Associate Professor of Ophthalmology, Department of Ophthalmology, Eye Research Center, Rassoul Akram Hospital, Tehran University of Medical Sciences
2. Fellowship in Anterior Segment, Department of Ophthalmology, Eye Research Center, Rassoul Akram Hospital, Tehran University of Medical Sciences
3. Assistant Professor of Ophthalmology, Department of Ophthalmology, Eye Research Center, Rassoul Akram Hospital, Tehran University of Medical Sciences
4. Department of Pediatric Hematology and Oncology, Shahid Beheshti University of Medical Sciences
5. Department of Hematology and Blood Bank, Iranian Blood Transfusion Organization-Research Center
6. Ophthalmologist, Department of Ophthalmology, Eye Research Center, Rassoul Akram Hospital, Tehran University of Medical Sciences
7. Medical Student, Scientific Research Center, Tehran University of Medical Sciences

Received: July 1, 2010

Accepted: January 20, 2011

Correspondence to: Alireza Foroutan, MD

Associate Professor of Ophthalmology, Department of Ophthalmology, Eye Research Center, Rassoul Akram Hospital, Tehran University of Medical Sciences, Tehran, Iran, Tel:+98 21 66558811, Email: arforoutan@yahoo.com

The authors have no financial interest in any materials discussed in this article.

© 2011 by the Iranian Society of Ophthalmology  
Published by Otagh-e-Chap Inc.

## Introduction

Pterygium is a common ocular surface disorder in many parts of the world, with reported prevalence rates ranging from 0.3% to 29%.<sup>1,2</sup>

The main challenge in pterygium surgery is prevention of recurrence. The reports of recurrence rate have discrepancies, but the recurrence rate of primary pterygium after simple excision is reported to be 25-45%.<sup>3</sup> Subsequently, some techniques currently used to prevent recurrence of pterygium are beta-radiation, excimer laser, argon laser, Thio-Tepa and anti-metabolite drugs, conjunctivolimbal autograft and amniotic membrane graft.<sup>4-11</sup> But procedures such as mitomycin C, Beta-radiation, or excimer laser, can induce serious complications such as corneal necrosis, scleral necrosis, or even phthisis bulbi.<sup>12</sup>

Conjunctival autografting after pterygium excision has been reported to be associated with lower recurrence rate (2% to 9%) and relatively less sight-threatening complications.<sup>13,14</sup> The current option for attaching a conjunctival autograft is the use of suture, which is time consuming and increases the operating time. Also, suturing can induce postoperative discomfort and complications such as buttonholes, suture abscesses, granuloma formation, tissue necrosis, and giant papillary conjunctivitis.<sup>13-20</sup>

Hence it seems reasonable to try to replace the current use of sutures with the use of tissue adhesives that may shorten operating time, improve postoperative comfort, and avoid suture-related complications.<sup>21</sup> Several studies<sup>22-27</sup> have considered using commercial fibrin glue in ophthalmic procedures, but studies about autologous fibrin glue<sup>28-31</sup> are few. We conducted a prospective study to evaluate the efficacy and safety of the use of the autologous fibrin glue in the attachment of a conjunctival autograft in primary pterygium surgery.

## Methods

This prospective interventional noncomparative case series included 15 eyes from 13 consecutive patients with primary nasal pterygium from September 2007 to October 2010. The study was approved by the Institutional Research Ethics Committee at the Eye Research Center, affiliated with the

Tehran University of Medical Sciences in Tehran. Informed consent was obtained from all patients after explanation of the surgical procedure and discussion about off-label uses of autologous fibrin glue.

A comprehensive medical and ophthalmic history, including gender, age, weight, previous eye surgery, and hypersensitivity to any blood components, were obtained from each patient. Exclusion criteria were recurrent pterygium, glaucoma, retinal pathologies necessitating intervention, history of previous ocular surgery or trauma, history of hypersensitivity to any blood components, coagulopathies and positive serology for HIV, hepatitis A, hepatitis B, hepatitis C, or syphilis. After systemic viral infections were ruled out by serologic laboratory examination, the patients were sent to the blood transfusion center for plasmapheresis and the preparation of fibrinogen and thrombin in two separate tubes from the patient's own blood.

In this study, at first, 16 eyes from 14 patients with primary nasal pterygium were enrolled, but later, one was excluded because of the positive serology test for hepatitis B. Preoperative ophthalmic evaluations included uncorrected and best corrected visual acuity (BCVA), digital anterior segment photography, slit-lamp exam, funduscopy, and tonometry.

### **Fibrin sealant preparation**

Patients with a body weight of over 40 kg, without any clinical restriction for plasmapheresis according to the national standards of the Iranian Blood Transfusion Organization,<sup>32</sup> were selected for obtaining autologous fibrin sealant. On the operation day, protamine (Sigma Chemical, St. Louis, MO) was added to the cryoprecipitates to precipitate the fibrinogen content, followed by centrifugation. Mean final fibrinogen concentration was 73±8 mg/ml. For the thrombin part, 10 ml plasma and 4 ml reagent (calcium chloride and ethanol) were added and mixed in a glass tube and incubated for 30 min. Finally, the supernatant was used as recovered human thrombin with 59.6±0.6 NIH activity.<sup>33</sup> Volume of fibrinogen was 5 cc and volume of thrombin was 5 cc (total volume of fibrin glue was 10 cc). All the aforementioned processes were done in a standard clean

room, and the products were delivered to the operation room in two separate, sealed tubes.

### **Surgical technique**

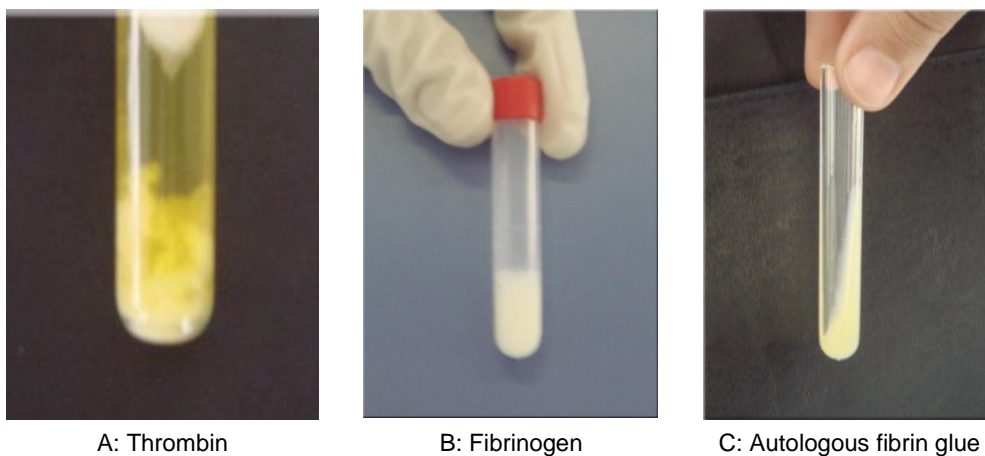
All surgical procedures were performed by the same surgeon (A.F.) to ensure consistency. Operations were carried out under general anesthesia. The involved eye was prepared with standard aseptic techniques and sterile draping. After lid speculum inserted, Blunt and sharp dissection by Westcott scissors (Geuder, Germany) was done for separation of fibrovascular tissue from the underlying sclera and surrounding conjunctiva, about 5 mm from the limbus (near to the medial rectus). The pterygium was removed from the cornea (superficial keratectomy) using a surgical blade (no. 15). Additional tenon tissue and subconjunctival scar was removed from under the conjunctiva with Westcott scissors. The wound bed was scraped to clean the cornea and sclera. Any bleeding source in the surgical wound was cauterized. Mitomycin C was not used for any patients. The dimensions of the bare scleral bed were measured with a caliper.

For harvesting the free conjunctival autograft, we followed Starck et al<sup>15</sup> technique. The donor autograft site in the suprot temporal bulbar conjunctiva was marked on all sides with skin marker (Kendall. Devon, Tokyo, Japan) to outline an oversized graft with an additional 1.0 mm of length and width relative to the dimensions of the bare sclera. The

conjunctiva, including the limbal edge, was carefully dissected away from Tenon's capsule, and care was taken to prevent buttonholes.

On the operation day, the thrombin and fibrinogen, prepared in two separate, sealed tubes in the blood transfusion center, were sent to the operating room (Figure 1). After drying the bare sclera with a wet sponge (Eye-Tech, England), 1.0 cc thrombin and 1.0 cc fibrinogen components with equal volumes were applied on the scleral bed by syringe (no. 27) over the joint of the graft edges and the healthy conjunctiva and cornea. After the mixing of the two components, the fibrinogen was converted to fibrin by thrombin. The free autograft was immediately spread over the bare sclera containing the glue, with care taken to maintain the original orientation of the juxtalimbal border toward the cornea and to prevent graft rollover. Excess glue was removed, and the graft was trimmed, if necessary.

The free conjunctival autograft was held in position for 5-10 min, until firm setting of the fibrin glue had occurred, to prevent tissue displacement. The lid speculum was removed, and the surgeon closed and opened the eye several times to ensure that the graft had adhered. An occlusive patch with exerting mild pressure was applied for 24 hours. The patient was advised not to rub the affected eye.



**Figure 1.** For preparation of autologous fibrin glue equal volumes of fibrinogen and thrombin was mixed together

After operation, oral tranexamic acid 250 mg (Caspian, Rasht, Iran) 4 times daily was given for 3 days. Topical medication was started on the first day after operation. Tranexamic acid eyedrops 100 mg/ml, made by diluting the tranexamic acid ampoules 500 mg/5 ml (Caspian, Rasht, Iran) with artificial tear (Sina Darou), were administered 3 times daily for 3 days. Topical chloramphenicol and betamethasone (Sina Darou) were postoperatively administered 4 times daily, the chloramphenicol eyedrops were discontinued 1 week after operation, and the betamethasone eyedrops were tapered and discontinued during the next 6 weeks, according to conjunctival injection.

All patients were visited on 1, 3, and 7 days and at 1, 6, and 9 months and 3 years after operation. In each visit, visual acuity (VA) and tonometry were checked. Slit-lamp examination was performed and a digital anterior segment photograph was taken to monitor autograft attachment, carefully looking for any evidence of graft retraction, graft dehiscence, recurrence, chemosis (yellowish graft edema), or development of complications such as corneal epithelial defects, symblepharon formation and giant papillary conjunctivitis, dellen, or allergic dermatitis.

The subjective symptoms of patients, such as pain, were recorded at every follow-up examination. Pain was evaluated using a 5-point scale from Lim-Bon-siong et al<sup>34,35</sup> as follows: 0, was none, no pain; 1, very mild, presence of pain but easily tolerated; 2, mild, pain causing some discomfort; 3, moderate, pain that partially interferes with usual activity or sleep; 4, severe, pain that completely interferes with usual activity or sleep.

Graft success was defined as an intact graft by the end of 1 month after operation, without need for sutures. Recurrence was defined as any regrowth of conjunctiva exceeding 1 mm onto the cornea.<sup>36</sup>

## Results

The mean age of the 13 treated patients was  $37.26 \pm 12.61$  years (range 23-60); <sup>10</sup>/<sub>13</sub>

(76.9%) were male. Two patients had bilateral pterygium. The mean follow-up period was  $34.67 \pm 2.96$  months (range 25-36) after operation.

Table 1 summarizes patients' characteristics, outcomes, and complications of using autologous fibrin glue following primary pterygium surgery by conjunctival autograft. Figures 2A and 2B show the outcome of pterygium autograft surgery with autologous fibrin glue.

Total graft dehiscence developed in two eyes (13.33%) 1 day after operation; these grafts were replaced and secured successfully with sutures at their correct position in the operating room.

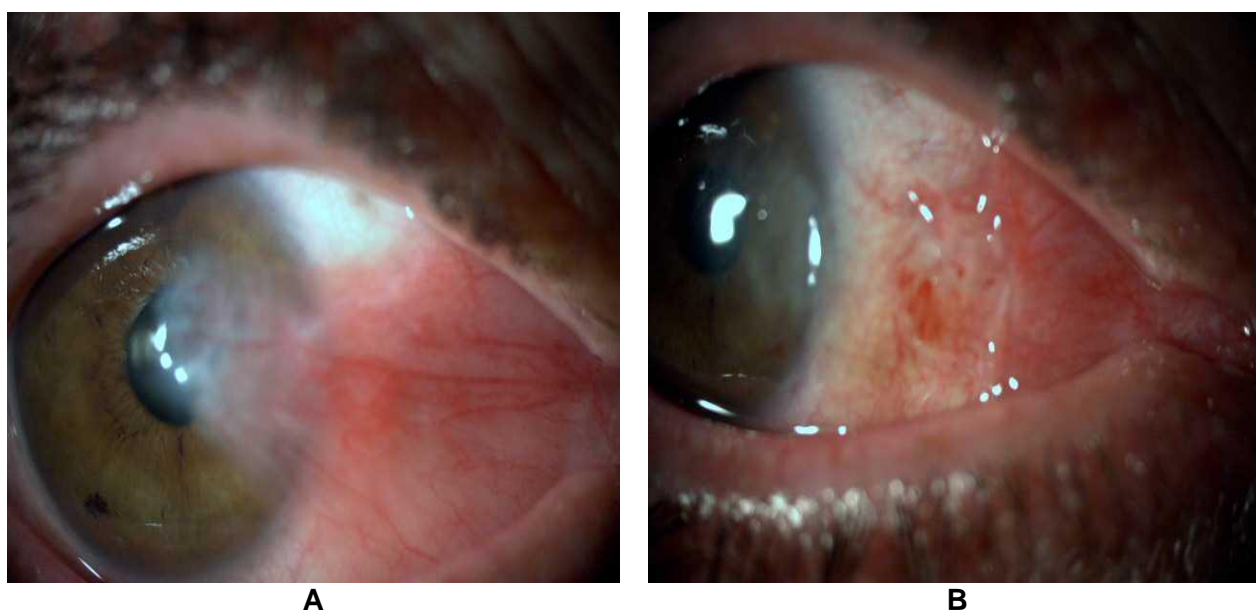
In this study, graft retraction (0.5-1.0 mm) occurred in 3 eyes (20%) (Figure 3), and these patients were treated completely with a continuation of patch therapy (48-72 hours) until secondary reepithelialization of the defect occurred without suturing. Chemosis was observed in 3 eyes (20%) with graft retraction that disappeared gradually and spontaneously during the first postoperative week. In this study, 2 eyes (13.33%) developed a recurrence of pterygium, and one of them had total graft dehiscence after operation.

In the first postoperative day, ocular pain was recorded in 73.33% of patients at grade 1, in 20% of patients at grade 2, and in 6.66% of patients at grade 3. Ocular pain in 86.66% of patients disappeared within 5 days postoperation. In two eyes (13.33%) with total graft dehiscence that needed sutures for graft attachment, the ocular pain continued for 2 weeks, until suture removal.

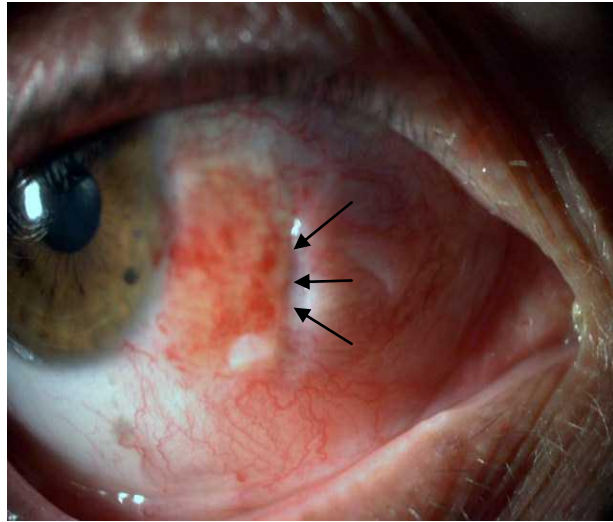
Before operation, mean intraocular pressure (IOP) was  $14 \pm 1.6$  mmHg, and after operation, at the last visit, was  $14.8 \pm 2.3$  mmHg and before operation, mean BCVA was logMAR 0.10, and after operation, at the last visit, mean VA was logMAR 0.10, no patient lost any line of his or her preoperative VA. None of the patients developed corneal ulcer, scleral melting, conjunctivitis, dellen, hypersensitivity to fibrin adhesives, symblepharon formation.

**Table 1.** Patient characteristics, outcomes, and complications using autologous fibrin glue following primary pterygium surgery by conjunctival autograft

Number of eyes	Sex	Age (yrs)	Total graft dehiscence	Graft retraction	Chemosis	Ocular pain	Recurrence
1	male	36	yes	no	no	1	no
2	male	36	no	no	no	1	no
3	male	23	no	no	no	1	no
4	male	41	no	no	no	2	no
5	male	51	no	no	no	1	no
6	female	31	no	no	no	1	yes
7	male	28	no	yes	yes	2	no
8	male	23	yes	no	no	3	yes
9	male	52	no	no	no	1	no
10	male	27	no	no	no	1	no
11	male	25	no	no	no	2	no
12	male	25	no	no	no	1	no
13	female	50	no	yes	yes	1	no
14	female	51	no	yes	yes	1	no
15	male	60	no	no	no	1	no



**Figure 2.** Shows outcome of pterygium autograft surgery with autologous fibrin glue: (A) Nasal pterygium before operation and (B) Image of autograft by autologous fibrin glue 24 hours after operation with full attachment of the graft to the bare sclera and adjacent conjunctiva



**Figure 3.** Autograft retraction and chemosis 1 day after operation; the patient completely improved after ocular patching and medical therapy. Arrows show the site of graft retraction.

## Discussion

The most concerning problem in pterygium surgery is the prevention of recurrence. Results of transplant of a free conjunctival autograft show a lower recurrence rate and are associated with fewer complications.<sup>17</sup> The most common method of autograft fixation is suturing, with the drawbacks of prolonged operating time, postoperative discomfort, suture abscesses, buttonholes, and granuloma formation which usually requires a second operation for removal.<sup>15</sup>

Commercial fibrin adhesive has been used widely in neurosurgery, plastic surgery, and ear, nose, and throat surgery. It is also reported that fibrin adhesive is useful in ophthalmology for conjunctival wound closure,<sup>22</sup> perforated corneal ulcer,<sup>23</sup> ocular plastic and orbital surgery,<sup>24,25</sup> repair of leaking glaucoma filtering blebs,<sup>26</sup> lamellar keratoplasty, and sealing of perforations in the lens capsule.<sup>27</sup>

Koranyi et al<sup>37</sup> in a randomized clinical trial, reported that fibrin glue TISSEEL Duo Quick (Baxter, Vienna, Austria) could be used to attach the conjunctival autograft instead of sutures, with reduced operating time and postoperative discomfort. The authors demonstrated a pterygium recurrence rate of 5.3% with glue versus 13.5% with sutures. Many studies compare fibrin sealant and

sutures for attaching grafts and demonstrate better results with fibrin glue.<sup>38,39</sup>

Vanitha Ratnalingam and et al<sup>40</sup> reported 175 eyes with primary pterygium (68 eyes by fibrin adhesive and 69 eyes by sutures) during 1 year follow-up and the results of fibrin adhesive was better than sutures in recurrence rate (4.41% versus 15.9%) and duration of the surgery (16.93±2.85 versus 29.84±5065 minutes). Other studies confirm this issue.<sup>35,21</sup>

The safety record of fibrin glue is of considerable importance because commercial fibrin glue is made from pooled blood product. The main issue in using commercial fibrin glue, despite viral inactivation techniques, is transmission of infectious agents.

Human infection of parvovirus B19 (HPV B19) has been reported after use of fibrin glue products from different manufacturers.<sup>41</sup> In thoracic surgery, epidemiological evidence suggests that more than 20% of uninfected people were subsequently infected with HPV B19 by use of fibrin during a surgical procedure.<sup>42</sup> Prions are also of concern. The direct application of any of the apparently effective methods of prion decontamination to plasma products is inappropriate because the methods are harsh and denaturing.<sup>43</sup> So autologous fibrin glue in comparison with

commercial products eliminates the potential risk of infection transmission and hypersensitivity reactions.

In addition, after use of TISSEEL fibrin sealant, three cases of anaphylactic reaction were reported, one of which resulted in death. The allergen was believed to be bovine protein aprotinin, which was induced in the product as an antifibrinolytic to slow the dissolution of the fibrin clot.<sup>44</sup> In this study, for antifibrinolytic effect, we used a tranexamic acid capsule and drop so that we did not have any hypersensitivity reactions.

Recently, Sharma and Moore<sup>45</sup> reported four cases using autologous fibrin glue for pterygium surgery. In their study, they showed well position grafts in all four cases after 6 weeks' follow-up, whereas in this study, we evaluated the efficacy and safety of autologous fibrin glue in 15 eyes during a mean follow-up period of  $34.67 \pm 2.96$  months.

In this study, total graft dehiscence occurred in two eyes (13.33%); one of these was our first case, and it may therefore be that this complication occurred due to inexperience and technical factors. This complication may also have resulted from a low concentration of thrombin and fibrinogen in the autologous fibrin glue compared to commercial types. Also, graft dehiscence is a recognized complication of using tissue glue and has been previously reported.<sup>35,46</sup>

In this study, concentration of thrombin and fibrinogen in the autologous fibrin glue was  $59.6 \pm 0.6$  NIH and  $73 \pm 8$  mg/ml, respectively; in comparison to commercial fibrin glue, which has 500 NIH and 120 mg/ml, respectively. It seems that in making autologous fibrin glue, we should use more appropriate methods with more concentration products.

In this study, all patients with graft retraction had chemosis, and it may be that conjunctival edema induced graft retraction. After control of chemosis by medical therapy,

retractions disappeared and grafts were placed in position.

The pain was mainly attributable to the presence of edema in the graft and adjacent conjunctiva; this discomfort improved with decrease in edema, after treatment with topical steroids and a pressure patch.

## Conclusion

In this study two patients developed recurrence during the mean follow-up period of  $34.67 \pm 2.96$  months and one of the recurrence had a total graft dehiscence that may be due to the ocular manipulation and reoperation in one patient with a total graft dehiscence.

No severe complications were found during the follow-up. According to the results of this study, some advantages are obtained using autologous fibrin glue. First is the elimination of infection transmission because all patients undergo full serologic laboratory examinations to rule out viral infections. Second is elimination of hypersensitivity reactions because the fibrin glue was prepared from the patient's own blood, and we do not use bovine protein aprotinin as an antifibrinolytic effect. Third, with the use of fibrin glue, there is no need for the suture removal that entails considerable extra time and additional pain and discomfort for patients. Finally, the fibrin glue product is very easy to use by any surgeon, and the technique has a short learning curve.

Limitations of this study were the small sample size and low concentration of thrombin and fibrinogen. A large-sized, prospective randomized study is being planned to determine efficacy, and recurrence rates in pterygium surgery with the use of autologous fibrin glue. Further study is needed to determine the best formula for preparation of autologous fibrin glue with greater concentration.

## References

1. Moran DJ, Hollows FC. Pterygium and ultraviolet radiation: a positive correlation. *Br J Ophthalmol* 1984;68(5):343-6.
2. Taylor HR, West S, Muñoz B, et al. The long-term effects of visible light on the eye. *Arch Ophthalmol* 1992;110(1):99-104.
3. Allan BDS, Short P, Crawford GJ, et al. Pinguecula and pterygia. *Surv Ophthalmol* 1988;33:41-9.

4. Amano S, Motoyama Y, Oshika T, et al. Comparative study of intraoperative mitomycin C and beta irradiation in pterygium surgery. *Br J Ophthalmol* 2000;84(6):618-21.
5. Talu H, Taşındı E, Ciftci F, Yildiz TF. Excimer laser phototherapeutic keratectomy for recurrent pterygium. *J Cataract Refract Surg* 1998;24(10):1326-32.
6. Na KS, Kim JY, Choi GJ. A clinical observation on the argon laser effect of the pterygium. *J Korean Ophthalmol Soc* 1996;37(7):1120-5.
7. Joselson GA, Muller P. Incidence of pterygium recurrence in patients treated with thio-tepa. *Am J Ophthalmol* 1966;61(5 Pt 1):891-2.
8. Panda A, Das GK, Tuli SW, Kumar A. Randomized trial of intraoperative mitomycin C in surgery for pterygium. *Am J Ophthalmol* 1998;125(1):59-63.
9. Rubinfeld RS, Pfister RR, Stein RM, et al. Serious complications of topical mitomycin-C after pterygium surgery. *Ophthalmology* 1992;99(11):1647-54.
10. Ma DH, See LC, Liau SB, Tsai RJ. Amniotic membrane graft for primary pterygium: comparison with conjunctival autograft and topical mitomycin C treatment. *Br J Ophthalmol* 2000;84(9):973-8.
11. Sánchez-Thorin JC, Rocha G, Yelin JB. Meta-analysis on the recurrence rates after bare sclera resection with and without mitomycin C use and conjunctival autograft placement in surgery for primary pterygium. *Br J Ophthalmol* 1998;82(6):661-5.
12. Hirst LW. The treatment of Pterygium. *Surv Ophthalmol* 2003;48(2):145-80.
13. Kenyon KR, Wagoner MD, Hettlinger ME. Conjunctival autograft transplantation for advanced and recurrent Pterygium. *Ophthalmology* 1985;92(11):1461-70.
14. Allan BD, Short P, Crawford CJ, et al. Pterygium excision with conjunctival autografting: an effective and safe technique. *Br J Ophthalmol* 1993;77(11):698-701.
15. Starck T, Kenyon KR, Serrano F. Conjunctival autograft for primary and recurrent pterygia: surgical technique and problem management. *Cornea* 1991;10(3):196-202.
16. Chen PP, Ariyasu RG, Kaza V, et al. A randomized trial comparing mitomycin C and conjunctival autograft after excision of primary pterygium. *Am J Ophthalmol* 1995;120(2):151-60.
17. Prabhasawat P, Barton K, Burkett G, Tseng SC. Comparison of conjunctival autografts, amniotic membrane grafts, and primary closure for pterygium excision. *Ophthalmology* 1997;104(6):974-85.
18. Tan DT, Chee SP, Dear KB, Lim AS. Effect of pterygium morphology on pterygium recurrence in a controlled trial comparing conjunctival autografting with bare sclera excision. *Arch Ophthalmol* 1997;115(10):1235-40.
19. Ti SE, Chee SP, Dear KB, Tan DT. Analysis of variation in success rates in conjunctival autografting for primary and recurrent pterygium. *Br J Ophthalmol* 2000;84(4):385-9.
20. Sridhar MS, Bansal AK, Rao GN. Surgically induced necrotizing scleritis after pterygium excision and conjunctival autograft. *Cornea* 2002;21(3):305-7.
21. Cohen RA, McDonald MB. Fixation of conjunctival autografts with an organic tissue adhesive. *Arch Ophthalmol* 1993;111(9):1167-8.
22. Zauberman H, Hemo I. Use of fibrin glue in ocular surgery. *Ophthalmic Surg* 1988;19(2):132-3.
23. Lagoutte FM, Gauthier L, Comte PR. A fibrin sealant for perforated and preperforated corneal ulcers. *Br J Ophthalmol* 1989;73(9):757-61.
24. Mandel MA. Closure of blepharoplasty incisions with autologous fibrin glue. *Arch Ophthalmol* 1990;108(6):842-4.
25. Bartley GB, McCaffrey TV. Cryoprecipitated fibrinogen (fibrin glue) in orbital surgery. *Am J Ophthalmol* 1990;109(2):227-8.
26. Kajiwara K. Repair of a leaking bleb with fibrin glue. *Am J Ophthalmol* 1990;109(5):599-601.
27. Kaufman HE, Insler MS, Ibrahim-Elzembely HA, Kaufman SC. Human fibrin tissue adhesive for sutureless lamellar keratoplasty and scleral patch adhesion: a pilot study. *Ophthalmology* 2003;110(11):2168-72.
28. Ozcan AA. Autologous human fibrin glue in multilayered amniotic membrane transplantation. *Ann Ophthalmol (Skokie)* 2008;40(2):107-9.



29. Gammon RR, Prum BE Jr, Avery N, Mintz PD. Rapid preparation of small-volume autologous fibrinogen concentrate and its same day use in bleb leaks after glaucoma filtration surgery. *Ophthalmic Surg Lasers* 1998;29(12):1010-2.
30. Asrani SG, Wilensky JT. Management of bleb leaks after glaucoma filtering surgery. Use of autologous fibrin tissue glue as an alternative. *Ophthalmology* 1996;103(2):294-8.
31. Mandel MA. Minimal suture blepharoplasty: closure of incisions with autologous fibrin glue. *Aesthetic Plast Surg* 1992;16(3):269-72.
32. Rezvan H, Ahmadi J, Mirbod V. The Iranian Blood Transfusion, Donor Safety Program: effect of long-term plasmapheresis on plasma proteins. *Iranian Journal of Medical Science* 2003;28(1):33-6.
33. Hashemi Teir A, Amirzadeh N, Eshghi P, et al. Study of in vitro properties of fibrin sealant prepared from single donor plasma. *Blood (Khoon)* 2009;6(3):181-9.
34. Lim-Bon-siong R, Valluri S, Gordon M, Pepose JS. Efficacy and safety of the ProTek (Vifilcon A) therapeutic soft contact lens after photorefractive keratectomy. *Am J Ophthalmol* 1998;125(2):169-76.
35. Uy HS, Reyes JM, Flores JD, Lim-Bon-Siong R. Comparison of fibrin glue and sutures for attaching conjunctival autografts after pterygium excision. *Ophthalmology* 2005;112(4):667-71.
36. Ang LP, Chua JL, Tan DT. Current concepts and techniques in pterygium treatment. *Curr Opin Ophthalmol* 2007;18(4):308-13.
37. Koranyi G, Seregard S, Kopp ED. Cut and paste: a no suture, small incision approach to pterygium surgery. *Br J Ophthalmol* 2004;88(7):911-4.
38. Jiang J, Yang Y, Zhang M, et al. Comparison of fibrin sealant and sutures for conjunctival autograft fixation in pterygium surgery: one-year follow-up. *Ophthalmologica* 2008;222(2):105-11.
39. Gallardo MJ, Johnson D, Trujillo F, Starek T. Sutureless pterygium surgery, an alternative method of fibrin sealant application. *Invest Ophthalmol Vis Sci* 2005;46:E-Abstract 954.
40. Ratnalingam V, Eu AL, Ng GL, et al. Fibrin adhesive is better than sutures in pterygium surgery. *Cornea* 2010;29(5):485-9.
41. Hino M, Ishiko O, Honda KI, et al. Transmission of symptomatic parvovirus B19 infection by fibrin sealant used during surgery. *Br J Haematol* 2000;108(1):194-5.
42. Kawamura M, Sawafuji M, Watanabe M, et al. Frequency of transmission of human parvovirus B19 infection by fibrin sealant used during thoracic surgery. *Ann Thorac Surg* 2002;73(4):1098-100.
43. Taylor DM. Inactivation of TSE agents: safety of blood and blood-derived products. *Transfus Clin Biol* 2003;10(1):23-5.
44. Oswald AM, Joly LM, Gury C, et al. Fatal intraoperative anaphylaxis related to aprotinin after local application of fibrin glue. *Anesthesiology* 2003;99(3):762-3.
45. Sharma A, Moore J. Autologous fibrin glue for pterygium surgery with conjunctival autograft. *Cont Lens Anterior Eye* 2009;32(5):209.
46. Srinivasan S, Slomovic AR. Eye rubbing causing conjunctival graft dehiscence following pterygium surgery with fibrin glue. *Eye (Lond)* 2007;21(6):865-7.