

Retrobulbar Hemorrhage after Blowout Fracture Reconstruction: A Case Report

Bahram Eshraghi, MD¹ • Alireza Keshtcar Jafari, MD² • Babak Masomian, MD³

Abstract

Purpose: To report a case of total blindness a few hours after orbital blowout fracture repair; the visual acuity (VA) returned to normal after immediate reoperation.

Case report: A 21-year-old man with obvious enophthalmos in the left side, 2 weeks after car accident, was candidate for orbital floor reconstruction surgery. Anterior orbitotomy from subciliary incision was done and at the end of the surgery, titanium medpore inserted in orbital floor. Three hours after surgery patient complained of severe pain and a significant proptosis was noticed. VA was no light perception (NLP) and relative afferent pupillary defect (RAPD) was positive. The patient reoperated and medpore plate was removed. There was significant blood in orbital cavity that was totally removed. Three hours after reoperation proptosis disappeared and VA improved to 3M count finger. One week after the surgery the VA was raised to ²⁰/₂₀.

Conclusion: Acute severe pain in the early postoperative period, may be a sign of the orbital hemorrhage. Awareness of the potential severity of this complication and execution of appropriate treatment with minimal delay, may result in rapid and complete visual recovery.

Keywords: Blowout Fracture, Retrobulbar Hemorrhage, Blindness

Iranian Journal of Ophthalmology 2011;23(2):69-71 © 2011 by the Iranian Society of Ophthalmology

Introduction

Retrobulbar hemorrhage is an uncommon complication after blowout fracture.^{1,2} Retrobulbar hemorrhage after blowout fracture surgery is even rarer and can occur immediately after operation.^{2,5} If it happens, patient may experience total blindness in the damaged eye.^{2,3,5}

The following report concerns a patient who suffered almost total loss of vision in one eye after orbital floor reconstruction surgery and obtained excellent response to immediately surgical decompression. At the follow-up the visual acuity (VA) was improved significantly and the eye had no detectable abnormality.

-
1. Assistant Professor of Ophthalmology, Eye Research Center, Farabi Eye Hospital, Tehran University of Medical Sciences, Tehran, Iran
 2. Associate Professor of Ophthalmology, Eye Research Center, Farabi Eye Hospital, Tehran University of Medical Sciences, Tehran, Iran
 3. Fellowship in Pediatric Ophthalmology, Eye Research Center, Farabi Eye Hospital, Tehran University of Medical Sciences, Tehran, Iran

Received: February 5, 2011

Accepted: June 14, 2011

Correspondence to: Babak Masomian, MD

Fellowship in Pediatric Ophthalmology, Eye Research Center, Farabi Eye Hospital, Tehran University of Medical Sciences, Tehran, Iran, Tel:+98 21 55414941-6, Email: bmpk2001@yahoo.com

Case report

A 21-year-old man who experienced car accident 2 weeks prior to examination; was visited in our oculoplastic clinic. The VA was $20/20$ in both eyes, relative afferent pupillary defect (RAPD) was negative, slit-lamp and funduscopy examination was normal. There was obvious enophthalmos (about 3 mm) in the left side; but the patient didn't have any symptom of diplopia or hyposthesia. In orbital CT scan, inferiolateral wall fracture was reported and orbital content herniation into maxillary sinus cavity was obvious (Figure 1).

Anterior orbitotomy via subciliary incision was done and all of the herniated orbital content was released from the fracture site. After exploration of orbital floor, posterior margin of fracture site was completely exposed. At the end of the operation one piece of titanium medpore (0.85 mm thickness and 20×20 mm Diameter) without suturing was inserted in subperiosteal space above the orbital floor. All of the fracture site was buried under medpore plate. There wasn't any bleeding in the operation field and at the end of surgery periosteum and skin were repaired routinely.

Three hours after surgery the patient made a complaint of a severe pain in the operated eye. There was proptosis, frozen globe, diffuse subconjunctival hemorrhage and chemosis. VA was no light perception (NLP) and RAPD was positive in the left eye.

Intraocular pressure (IOP) was 42 mmHg and funduscopy showed retinal paleness.

Immediately, patient was reoperated (in less than 4 hours after the first surgery) and under general anesthesia all sutures were cut and medpore plate removed from orbital floor. There was significant blood in orbital cavity that was totally removed. We couldn't distinguish the site of active bleeding, but oozing discharge was visible. Doubtful sites were gently cauterized. Periosteum layer was abandoned without suturing, and some parts of skin layers were left without suturing. However oozing discharge from the wound was detectable until midnight. Finally at the end of the reoperation, there wasn't significant proptosis. Intravenous methylprednisone was prescribed (1 gr/d) for three days. In evaluation hematologic laboratory report was normal.

Three hours after reoperation, there wasn't any proptosis and VA was improved to 3M count finger. Four days after surgery, best corrected visual acuity (BCVA) was nearly $7/10$ and one week after surgery it reached to $10/10$ in both eyes. RAPD was negative and there wasn't any diplopia or misalignment. Four months after surgery VA was $10/10$ in both eyes. We proposed to do another surgery for orbital reconstruction; but patient refused reoperation.

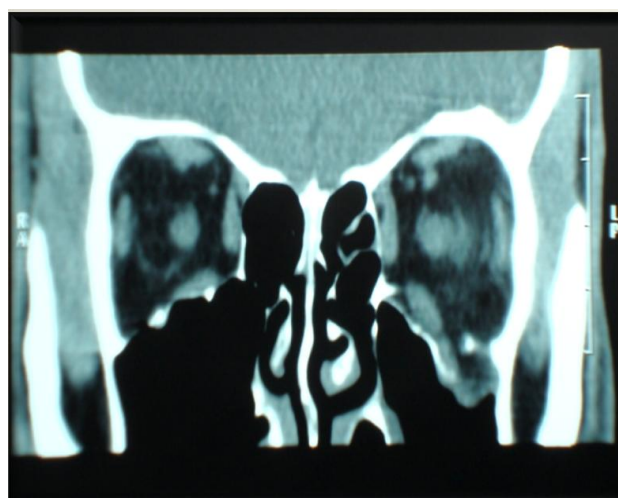
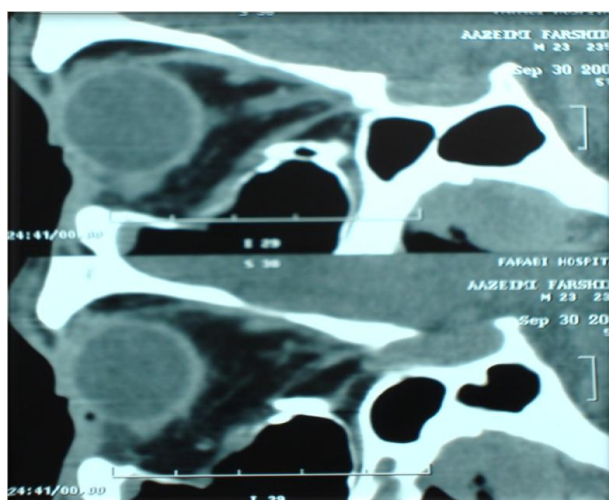


Figure 1. Patients orbital CT scan in sagittal (left picture) and coronal (right picture) view show significant hinge type orbital floor fracture in OS and herniation of orbital content to maxillary sinus

Discussion

Retrobulbar hemorrhage is an uncommon complication of orbital floor fracture.^{1,2} It is a potentially blinding complication which may occur at any time over the first few days following orbital trauma.^{2,3} Retrobulbar hemorrhage after blowout fracture surgery are even rarer and can occur immediately.^{2,5} The axial proptosis and presence of conjunctival chemosis and injection demonstrate an intraconal bleeding.⁴ The source of the hemorrhage is generally the infra-orbital artery or one of its branches. This condition increased orbital pressure causing a "compartment syndrome".^{1,4,6} A bleeding into the muscle cone would compress long and short posterior ciliary artery, producing an ischemic optic neuropathy which is the most likely mechanism of visual loss in these cases.^{1,4,5} With "critically" raised pressure, irreversible optic and retinal ischemia can occur within 60 minutes, and permanent visual loss within 1.5-2 hours.⁶ So, it is generally accepted that outcome are usually better if the treatment to be done as soon as possible.^{2,3,5-7}

In the time of first surgery for orbital floor reconstruction; there wasn't active bleeding, so we suggest hemorrhage from the fine vessels of herniated fat tissue, might be the reason for the hemorrhage and compression of optic nerve, causing complete blindness. On the other hand complete covering of the fracture site (with medpore) may have eliminated free drainage of blood into sinus cavity.

Conclusion

Acute severe pain in the early postoperative period, may be a sign of orbital hemorrhage.^{1-3,6} Awareness of the potential severity of this complication and execution of appropriate treatment with minimal delay, could result in rapid and complete visual recovery.^{3,6,7} Early management is very important in such cases, and after orbital reconstruction and any orbital surgery, patient must be visited in appropriate intervals.

References

1. Wood CM. The medical management of retrobulbar haemorrhage complicating facial fractures: a case report. *Br J Oral Maxillofac Surg* 1989;27(4):291-5.
2. Holt JE, Holt GR, Blodgett JM. Ocular injuries sustained during blunt facial trauma. *Ophthalmology* 1983;90(1):14-8.
3. Nicholson DH, Guzak SW. Visual loss complicating repair of orbital floor fractures. *Arch Ophthalmol* 1971;86(4):369-75.
4. Ord RA, Awty MD, Pour S. Bilateral retrobulbar haemorrhage: a short case report. *Br J Oral Maxillofac Surg* 1986;24(1):1-6.
5. Liu D. Blindness after blow-out fracture repair. *Ophthal Plast Reconstr Surg* 1994;10(3):206-10.
6. Perry M. Acute proptosis in trauma: retrobulbar hemorrhage or orbital compartment syndrome—does it really matter? *J Oral Maxillofac Surg* 2008;66(9):1913-20.
7. Burkat CN, Lemke BN. Retrobulbar Hemorrhage: inferolateral anterior orbitotomy for emergent management. *Arch Ophthalmol* 2005;123(9):1260-2.