

# Dermoid Cyst of the Frontal Bone: A Case Report

Ali Sadeghi Tari, MD<sup>1</sup> • Bahram Eshraghi, MD<sup>2</sup> • Hamid Reza Torabi, MD<sup>3</sup>

---

---

## Abstract

**Purpose:** To report an unusual case of dermoid cyst of the frontal bone

**Case report:** We report a case of 28-year-old man with a history of painless progressive proptosis of the left eye. CT-Scan was showed a hypodense lesion that mainly located within the frontal bone with only a small intraorbital involvement. Excisional biopsy was performed and histopathologic examination was compatible with dermoid cyst. Dermoid cysts are the most common orbital cystic lesions in childhood which commonly present as a painless palpable mass in the superotemporal aspect of the orbit. Typically, orbital dermoids involved the orbital cavity and may compress the nearby structures or erode the orbital walls. Here we report an unusual case of dermoid cyst that mainly involved a bony orbital wall with only a small intraorbital extension.

**Conclusion:** Appropriate diagnosis of unusual cases of dermoid cysts can lead to proper therapeutic approaches and prevention of complications.

**Keywords:** Dermoid Cyst, Frontal Bone, Orbital Wall

*Iranian Journal of Ophthalmology 2011;23(3):57-59 © 2011 by the Iranian Society of Ophthalmology*

---

---

## Introduction

Dermoid cysts are developmental choristomas (anomalies composed of abnormal type of cells not normally found at the involved site)<sup>1</sup> that originate from aberrant primordial tissues and composed of dermal and epidermal cells which are trapped into embryonic lines of fusion.<sup>2</sup>

Approximately 7% of all dermoid cysts affect the head and neck region and within this region, about 50% of tumors are found in or adjacent to orbit.<sup>3</sup> They are found most commonly in the lateral upper eyelid adjacent to the frontozygomatic suture.<sup>4,5</sup> Depending on their locations, clinical presentation can be very different; they are usually visible at birth or early in life as a solitary slow-growing asymptomatic mass

unless inflamed or infected.<sup>6,7</sup>

The presentation as an intraosseous dermoid cyst with an intraorbital extension is rare. Here we report an unusual case of dermoid cyst that primarily involved the frontal bone with a small portion of intraorbital involvement.

## Case report

A 28-year-old man was referred to oculoplastic and orbital surgery service, Farabi Eye Hospital, Tehran, Iran with a painless and gradually progressive proptosis of the left eye. The patient's complaint has been started since 6 months earlier. No headache, seizures, visual impairment or diplopia was noted.

- 
1. Professor of Ophthalmology, Eye Research Center, Farabi Eye Hospital, Tehran University of Medical Sciences, Tehran, Iran
  2. Assistant Professor of Ophthalmology, Eye Research Center, Farabi Eye Hospital, Tehran University of Medical Sciences, Tehran, Iran
  3. Ophthalmologist, Eye Research Center, Farabi Eye Hospital, Tehran University of Medical Sciences, Tehran, Iran

Received: June 18, 2011  
Accepted: August 4, 2011

Correspondence to: *Hamid Reza Torabi, MD*  
*Ophthalmologist, Eye Research Center, Farabi Eye Hospital, Tehran University of Medical Sciences, Tehran, Iran,*  
*Tel:+98 21 55414941-6, Email: dr\_hamidrezatorabi@yahoo.com*

On physical examination, mild proptosis (2 mm) on the left side was detected. Visual acuity (VA) was  $20/20$  in both eyes. There was no globe displacement or restricted ocular motility. On slit-lamp examination, the anterior segment findings were within normal limits. Intraocular pressure (IOP) and fundus were also normal. Systemic examination didn't reveal any abnormality.

The computed tomography (CT-Scan) of the orbit was done and revealed a well demarcated cystic lesion within the orbital roof. This lesion involved the frontal bone and extending to the greater wing of the sphenoid bone with a stalk extending down to the orbital cavity through a well-defined bony defect in the orbital roof (Figures 1, 2).



Figure 1. Orbital CT-scan (coronal view)

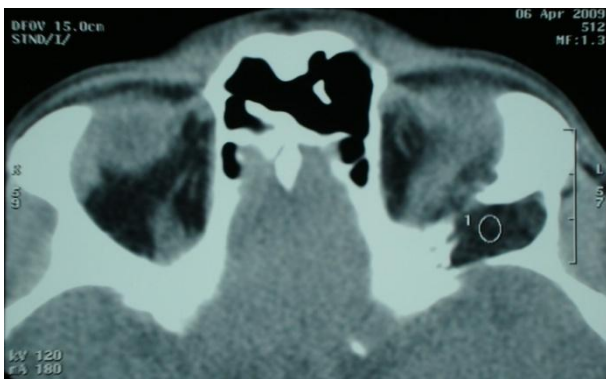


Figure 2. Orbital CT-scan (axial view)

Lateral orbitotomy was performed and superficial portion of the cyst was removed. Then following excision of the superolateral aspect of the orbital rim, intraosseous cyst was exposed and the cyst content was excised and the cystic walls were removed completely.

Histopathologic examination showed the cyst containing keratin, hair, and sebaceous glands. These findings were compatible with dermoid cyst.

Postoperative period was uneventful. Visual function and eye movements were normal after operation.

## Discussion

Dermoid cysts are the most common orbital cystic lesions in childhood which constitute about 40% of orbital lesions in that age group.<sup>4</sup> Bartlett et al have classified the orbitofacial dermoids into three subgroups, namely brow (frontotemporal), orbital, and nasolabial. The frontotemporal dermoids are the most common type, accounting for 64 percent of the total.<sup>8</sup>

Superficial cysts often become symptomatic in childhood but deeper cysts remain asymptomatic until adulthood.<sup>4</sup> They usually present as a palpable, painless mass with gradual enlargement.<sup>3-5</sup> Rarely orbital inflammation may occur because of leakage of oil and keratin from the cyst.<sup>1</sup> Detailed radiographic studies are mandatory for suspected orbitofacial dermoids.<sup>2</sup> CT-scan or MRI can provide reliable assessment in the diagnosis of these lesions.<sup>9</sup> It can show the tumor contents and also, the contiguous structure involvement.

The differential diagnosis of a solitary mass in the orbital region including, epidermoid cysts, eosinophilic granulomas, hemangiomas, osteomas, osteogenic sarcomas, and metastatic tumors.<sup>10</sup>

Histopathologically, dermoid cysts are well defined masses that are covered by keratinized epidermis and dermal appendages such as hair follicles and sebaceous glands and they contain oil and keratin.<sup>5</sup>

Surgical excision of dermoid cysts is a common intervention. The surgeon must try to maintain the cyst wall intact during the surgical excision, since the inflammatory process may occur if its contents remain within the orbit.<sup>5</sup> Also, total removal of the entire epithelial lining and the stalk or tract attached to the wound base is necessary to ensure no recurrence.

Our case is unusual because of the lesion mainly involved the bony orbital walls and there was only a small intraorbital extension. Usually, orbital dermoids located primarily in

the orbital cavity and may compress the nearby structures or erode the orbital walls. Accurate diagnosis and effective treatment are essential to avoid craniofacial skeletal deformity, cyst rupture, and infection resulting in cutaneous, ocular, or intracranial complications.<sup>9</sup>

There are few reports on dermoid cysts that primarily located in the frontal bone. Fujimaki et al reported a 9-month-old girl with dermoid cyst of the frontal bone.<sup>11</sup> Generally dermoid cysts are found in the orbit and they may have an extension to the adjacent bones

or may have a dumbbell-shaped appearance. In our case the major part of the cyst was located in the frontal bone and only had a small intraorbital extension, which represent an unusual presentation for dermoid cyst.

### **Conclusion**

Dermoid cysts of the frontal bone are rare and preoperative diagnosis is difficult. CT and MRI can suggest a dermoid cyst and leading to appropriate surgical approach.

### **References**

1. Abou-Rayyah Y, Rose GE, Konrad H, et al. Clinical, radiological and pathological examination of periocular dermoid cysts: evidence of inflammation from an early age. *Eye (Lond)* 2002;16(5):507-12.
2. Chuang CJ, Chen TM, Wang HJ. Reconstruction of bony compression deformity resulting from deep frontotemporal dermoid cysts. *J Med Sci* 2003;23(6):333-6.
3. Srivastava U, Dakwale V, Jain A, Singhal M. Orbital dermoid cyst with intracranial extension. *Indian J Ophthalmol* 2004;52(3):244-6.
4. Eibl KH, Kampik A, Hintschich C. Upper eyelid oedema from a dumbbell-shaped dermoid cyst. *Acta Ophthalmol Scand* 2005;83(1):126-7.
5. Liesegang TJ, Skuta GL, Cantor LB. Orbital neoplasms. In: Kersten RC, Codere F, Dailey RA, et al, eds. *Basic and Clinical Science Course: Orbit, Eyelids and Lacrimal System* (section 7). San Francisco, CA: American Academy of Ophthalmology, 2007:157-200.
6. Bonavolontà G, Tranfa F, de Conciliis C, Strianese D. Dermoid cysts: 16-year survey. *Ophthalm Plast Reconstr Surg* 1995;11(3):187-92.
7. Steele MH, Suskind DL, Moses M, et al. Orbitofacial masses in children: an endoscopic approach. *Arch Otolaryngol Head Neck Surg* 2002;128(4):409-13.
8. Bartlett SP, Lin KY, Grossman R, Katowitz J. The surgical management of orbitofacial dermoids in the pediatric patient. *Plast Reconstr Surg* 1993;91(7):1208-15.
9. Posnick JC, Bortoluzzi P, Armstrong DC, Drake JM. Intracranial nasal dermoid sinus cysts: computed tomographic scan findings and surgical results. *Plast Reconstr Surg* 1994;93(4):745-54.
10. Baldwin HE, Berck CM, Lynfield YL. Subcutaneous nodules of the scalp: preoperative management. *J Am Acad Dermatol* 1991;25(5 Pt 1):819-30.
11. Fujimaki T, Miyazaki S, Fukushima T, et al. Dermoid cyst of the frontal bone away from the anterior fontanel. *Childs Nerv Syst* 1995;11(7):424-7.