

Serum Homocysteine Levels in Pseudoexfoliative Glaucoma and Primary Open Angle Glaucoma

Fahimeh Asadi Amoli, MD¹ • Arefeh Ghobadi, MD² • Ghasem Fakhraie, MD³

Abstract

Purpose: To compare the serum homocysteine (Hcy) level in healthy control individuals and in patient with primary open angle glaucoma (POAG) and pseudoexfoliative glaucoma (PEXG)

Methods: In this cross sectional study, 79 subjects including 36 patients with PEXG, 23 patients with POAG, and 20 matched healthy control individuals were recruited. Those who used alcohol and medications affecting Hcy levels were excluded. The level of serum Hcy was measured by Enzyme Immunoassay (EIA) method. Analysis of variance (ANOVA) was used to compare Hcy levels among PEXG, POAG and control groups.

Results: The mean ages were 68.9, 63.3, and 64.7 years in PEXG, POAG, and control groups, respectively (P=0.053); and 64%, 52%, and 60% were male in three study groups, respectively (P=0.67). The mean Hcy levels in PEXG, POAG and control groups were 12.21±4.93, 10.20±5.25, and 11.59±3.87 µmol/l, respectively (P=0.293; ANOVA). There was not a significant correlation between Hcy levels and diabetes, hyperlipidemia (HLP), hypertension (HTN), and cigarette smoking among diagnostic groups.

Conclusion: No significant difference was found in Hcy levels among PEXG, POAG, and normal control group.

Keywords: Pseudoexfoliative Glaucoma, Primary Open Angle Glaucoma, Homocysteine

Iranian Journal of Ophthalmology 2012;24(1):19-24 © 2012 by the Iranian Society of Ophthalmology

-
1. Associate Professor of Pathology, Department of Pathology, Tehran University of Medical Sciences
 2. Resident in Pathology, Tehran University of Medical Sciences, Tehran, Iran
 3. Associate Professor of Ophthalmology, Eye Research Center, Farabi Eye Hospital, Tehran University of Medical Sciences, Tehran, Iran

Received: August 28, 2011

Accepted: December 29, 2011

Correspondence to: *Ghasem Fakhraie, MD*
Associate Professor of Ophthalmology, Eye Research Center, Farabi Eye Hospital, Tehran University of Medical Sciences, Tehran, Iran, Email: *dfakhraee@yahoo.com*

None of the authors has any proprietary or financial interest in the products mentioned in this article.
This study was supported by a grant from the Tehran University of Medical Sciences (TUMS).

Introduction

Glaucoma, which is characterized by progressive optic neuropathy resulting in visual field disturbance, is the prominent cause of blindness. The pathogenesis of optic nerve damage in glaucoma has not been clearly understood, yet. Even though, intraocular pressure (IOP) has been known to be the most important risk factor, many evidences support the role of ischemia and vascular risk factors.¹ Inadequate perfusion due to arteriosclerosis or vascular dysregulation may lead to glaucomatous damage of optic nerve.¹⁻³ Also retinal ganglion cell apoptosis (seen in glaucoma) may be the result of either reduced optic nerve perfusion or direct toxic effect of cytotoxic agents.⁴⁻⁵

Homocysteine (Hcy) is an amino acid known to be vasculopathic and cytotoxic.⁶⁻⁹ Recently, many studies have been conducted to assess the association of hyperhomocysteinemia and cardiovascular diseases. High levels of Hcy seems to be a possible risk factor for arteriosclerosis in coronary artery, cerebral artery and peripheral vessels.¹⁰⁻¹⁵

Compared with healthy subjects, there is about a 30% higher Hcy concentration in patients with vascular diseases.¹² Although the association between retinal vascular diseases and hyperhomocysteinemia has been demonstrated in a number of studies,¹⁶⁻²⁴ evaluation of Hcy and glaucoma has yielded conflicting results, some implicating an association with primary open angle glaucoma (POAG) and pseudoexfoliative glaucoma (PEXG),²⁵⁻²⁹ Whilst others have not.³⁰ On the other hand, there is no study evaluating this association in our country. In this regard, we studied the level of Hcy in groups of PEXG and POAG patients and compared them with a healthy control group.

Methods

In this cross sectional study, 36 patients with PEXG, 23 patients with POAG, and 20 control healthy subjects were recruited. All participants were thoroughly explained about the purpose of the study and signed an informed consent. The study was approved by the Institutional Review Board at Farabi Eye Hospital and was conducted in compliance with the tenets of the Declaration of Helsinki.

All glaucoma patients were recruited from the Glaucoma Clinic, Farabi Eye Hospital, Tehran, Iran.

For each subject, a comprehensive ophthalmic examination including slit-lamp biomicroscopy, measurement of IOP (Goldman applanation tonometer), evaluation of visual field (Humphrey Visual Field Analyzer), funduscopy examination, and gonioscopy was performed by the same examiner (Gh.F.).

Criteria to be identified as POAG were: evidence of glaucomatous optic nerve head damage, an open angle on gonioscopy, and typical glaucomatous visual field defects on perimetry. PEXG group had above features plus typical pseudoexfoliative material deposits on pupillary margin and/or anterior lens capsule. Control group was selected from the referred patients to the hospital without any history of glaucoma. Based on the published data, and for a study power of 80%, a sample size of at least 20 cases was estimated for each group.

A complete medical history was obtained to identify any other vascular risk factors affecting perfusion of the optic nerve; including hypertension (HTN), diabetes mellitus (DM), hyperlipidemia (HLP), and cigarette smoking. Age, gender, and abovementioned risk factors were matched between patients and control groups. Those with a history of chronic alcohol abuse and taking medications that may affect serum Hcy levels, such as anticonvulsant therapy, lipid lowering drugs, psychiatric illness, recent exposure to nitrous oxide, methotrexates and other folate antagonists, L-Dopa, cholestyramine, and niacin were excluded from our study.

Specimen collection

Blood samples were collected into tubes. After 30 minutes and complete coagulation of blood, centrifugation at 3,500 rpm for 6 minutes was performed. Serum was separated from clot and immediately frozen at -20° C. Thereafter, all specimens were stored at -70° C and kept there until Hcy level was measured.

The level of serum Hcy was measured by Enzyme Immunoassay (EIA) method. The assay principles in this method were reduction

of protein-bound Hcy to free Hcy and enzymatic conversion to S-adenosyl -L-homocysteine (SAH) in a separate procedure prior to immunoassay. Standard curves according to calibrator concentration were obtained. Quality control samples were also run with our batch. Normal range for Hcy level was considered between 5 and 20 $\mu\text{mol/L}$.

Statistical method

Statistical analysis was performed using SPSS for Windows version 11.5 (SPSS Inc., Chicago, IL). Analysis of variance (ANOVA) was used to compare age and Hcy levels among PEXG, POAG and control groups. Mann-Whitney test was performed to demonstrate differences in Hcy level among glaucoma (totally) and control groups. χ^2 test was used to assess differences in sex and vascular risk factors between our diagnostic groups. Analysis of Covariance (ANCOVA) test was performed to assess differences in Hcy levels among the study groups according to the mentioned vascular risk factors. For all measurements, a two-tailed test was used and a P value of <0.05 was considered significant for measured variables.

Results

Patients' demographics and characteristics are summarized in Table 1. Patients' mean age and gender were matched among our groups and had no statistically significant differences (ANOVA; $P=0.053$ and χ^2 test; $P=0.67$, respectively).

The mean \pm SD of Hcy levels in PEX, POAG and control groups were 12.21 ± 4.93 , 10.20 ± 5.25 , and 11.59 ± 3.87 $\mu\text{mol/L}$, respectively (Figure 1). There was no statistically significant differences among these groups (ANOVA; $P=0.293$). Furthermore, when we considered all glaucoma patients (PEXG and POAG) together, there was no statistically significant difference in Hcy levels between glaucoma and control groups (Mann-Whitney; $P=0.640$).

All vascular risk factors such as diabetes, HLP, HTN, and smoking had no significant differences among our diagnostic groups (χ^2 test; all $P>0.05$) (Table 1).

Among our diagnostic groups and in a univariate analysis, no significant differences in Hcy levels between cases with diabetes, HTN, HLP, and smoking were identified (Table 2).

Table 1. Patients' characteristics and demographics

Variables	Study groups			P
	PEXG	POAG	Control	
Mean age (year)	68.97	63.3	64.75	0.053
Gender; male	23 (64 %)	12 (52%)	12 (60 %)	0.67
Diabetes	4 (11%)	6 (26%)	4 (20%)	0.324
Hypertension	6 (17%)	5 (22%)	3 (15%)	0.825
Hyperlipidemia	3 (8%)	3 (13%)	3 (15%)	0.721
Smoking	7 (19%)	3 (13%)	4 (20%)	0.783
Total vascular risk factors	10 (28%)	11 (48%)	7 (35%)	0.291

PEXG: Pseudoexfoliative glaucoma
POAG: Primary open angle glaucoma

Table 2. Serum homocysteine level differences in the groups according to vascular risk factors (ANCOVA; univariate analysis)

Vascular risk factors	P
Diabetes mellitus	0.388
hypertension	0.281
hyperlipidemia	0.316
Smoking	0.338
Total risk Factor	0.367

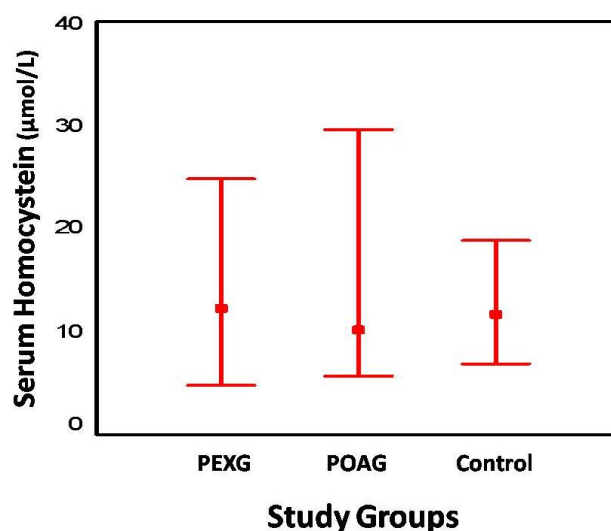


Figure 1. Serum homocysteine levels in pseudoexfoliative glaucoma, primary open angle glaucoma, and control groups

Discussion

In this study we found no significant differences in Hcy levels among our diagnostic groups (PEXG, POAG and control). This finding is in contrast with some previous reports indicating higher levels of Hcy in PEXG and POAG in comparison with healthy control group. For example, in Vessani et al study, including 25 patients with pseudoexfoliation syndrome, 50 with PEXG, 25 with normal tension glaucoma (NTG) and 24 healthy control individuals, higher levels of Hcy in pseudoexfoliation syndrome and PEXG was noted.²⁸ Finding of increased Hcy level, specially in PEXG patients, in several studies has led some authors to suggest that deposited material of PEX may be a product of elastolysis induced by toxic effect of Hcy.³¹

Also, increased values of Hcy level in aqueous humor of PEXG patients has been reported.³² Evaluation of Hcy level in a number of studies comparing this value in PEXG, POAG and NTG patients with control groups, demonstrated significant correlation between increased levels of Hcy and PEXG but not POAG or NTG.^{33,34} In one case control study; using high performance liquid chromatography (HPLC) method, no significant differences was found in Hcy values between POAG, non-POAG and control group ($P=0.93$ ANOVA).³⁰

Bleich et al reported only borderline increased levels of Hcy in Caucasians with PEXG.²⁷ Considering these results and our findings, and also, another study performed in Turkey, which showed no significant difference in Hcy levels in PEX and control groups³⁵; we hypothesized that ethnic variation may have some impact on the Hcy levels in different populations. Another example for ethnic group differences is Vermaak et al report on a group of black South Africans who had been exposed to the same environment and western diet for at least 2 years. They reported a significantly lower Hcy concentration (46% differences) than a comparable group of age-matched whites.³⁶ Additionally we should remember that different population characteristics such as nutritional status and presence of associated illness may account for the conflicting results. Renal failure, hypothyroidism, diseases that may be associated with impaired folate status and so with an increased concentration of Hcy (leukemia and solid tumors), psoriasis, and hepatic insufficiency may be accompanied by hyperhomocysteinemia in different populations.³⁷ In our study we matched possible confounding factors such as diabetes, HTN, HLP, and cigarette smoking among our groups. No significant correlation

in Hcy levels according to these confounding factors was identified.

And finally, we should emphasize that conflicting results in experiments evaluating Hcy level as a risk factor in cardiovascular disease, have also been reported.³⁸ So, it is not clear whether Hcy is a causative factor or only a marker of vascular diseases.

One of the shortcomings of our study was a relatively small samples size in each cases and control groups that could affect our results. Conducting a study with a larger

sample size may provide more conclusive results.

Conclusion

We concluded that, the Hcy level does not have any correlation with POAG and PEXG. Also, we found no correlation in Hcy levels between our diagnostic groups. We recommend conducting a study with a larger sample size, which considers all clinical conditions and nutritional status that may have influence on Hcy levels, so that more confident results could be obtained.

References

1. Flammer J, Orgül S, Costa VP, et al. The impact of ocular blood flow in glaucoma. *Prog Retin Eye Res* 2002; 21(4):359-93.
2. Weinreb RN, Cioffi GA, Harris A. Optic nerve blood flow. In: Van Buskirk EM, Shields B, eds. 100 years of progress in glaucoma. Philadelphia: Lippincott Raven Healthcare, 1997:59-78.
3. Hayreh SS. Blood flow in the optic nerve head and factors that may influence it. *Prog Retin Eye Res* 2001;20(5):595-624.
4. Broadway D, Drance SM. Glaucoma and vasospasm. *Br J Ophtalmol* 1998;82(8):862-70.
5. Feldman F, Sweeney V, Drance SM. Cerebro-vascular studies in chronic simple glaucoma. *Can J Ophtalmol* 1969;4(4):358-64.
6. Mujumdar VS, Aru GM, Tyagi SC. Induction of oxidative stress by homocyst(e)ine impairs endothelial function. *J Cell Biochem* 2001;82(3):491-500.
7. Ramarkrishnan S, Sulochana KN, Lakshmi S, et al. Biochemistry of homocysteine in health and disease. *Indian J Biochem Biophys* 2006;43(5):275-83.
8. Ritch R. Exfoliation syndrome: beyond glaucoma. *Arch Ophthalmol* 2008;126(6):859-61.
9. Carroll JF, Tyagi SC. Extracellular matrix remodeling in the heart of the homocysteinemic obese rabbit. *Am J Hypertens* 2005;18(5 Pt 1):692-8.
10. McCully KS. Vascular pathology of homocysteinemia: implications for the pathogenesis of arteriosclerosis. *Am J Pathol* 1969;56(1):111-28.
11. Perry IJ, Refsum H, Morris RW, et al. Prospective study of serum total homocysteine concentration and risk of stroke in middle-aged British men. *Lancet* 1995;346(8987):1395-8.
12. Ueland PM, Refsum H, Brattstrom L. Plasma homocysteine and cardiovascular disease. In: Francis RBJ, ed. *Atherosclerotic cardiovascular disease, hemostasis, and endothelial function*. New York: Marcel Dekker, 1992:183-236.
13. Clarke R, Daly L, Robinson K, et al. Hyperhomocysteinemia: an independent risk factor for vascular disease. *N Engl J Med* 1991;324(17):1149-55.
14. Selhub J, Jacques PF, Bostom AG, et al. Association between plasma homocysteine concentrations and extracranial carotid-artery stenosis. *N Engl J Med* 1995;332(5):286-91.
15. Nygard O, Nordrehaug JE, Refsum H, et al. Plasma homocysteine levels and mortality in patients with coronary artery disease. *N Engl J Med* 1997;337(4):230-6.
16. Biousse V, Newman NJ, Sternberg P Jr. Retinal vein occlusion and transient monocular visual loss associated with hyperhomocystinemia. *Am J Ophthalmol* 1997;124(2):257-60.
17. Cahill M, Karabatzaki M, Meleady R, et al. Raised plasma homocysteine as a risk factor for retinal vascular occlusive disease. *Br J Ophthalmol* 2000;84(2):154-7.
18. Salomon O, Moisseiev J, Rosenberg N, et al. Analysis of genetic polymorphisms related to thrombosis and other risk factors in patients with retinal vein occlusion. *Blood Coagul Fibrinolysis* 1998;9(7):617-22.

19. Pianka P, Almog Y, Man O, et al. Hyperhomocystinemia in patients with nonarteritic anterior ischemic optic neuropathy, central retinal artery occlusion, and central retinal vein occlusion. *Ophthalmology* 2000;107(8):1588-92.
20. Loewenstein A, Goldstein M, Winder A, et al. Retinal vein occlusion associated with methylenetetrahydrofolate reductase mutation. *Ophthalmology* 1999;106(9):1817-20.
21. Loewenstein A, Widner A, Goldstein M, et al. Bilateral retinal vein occlusion associated with 5, 10-methylenetetrahydrofolate reductase mutation. *Am J Ophthalmol* 1997;124(6):840-1.
22. Weger M, Stanger O, Deutschmann H, et al. The role of hyperhomocysteinemia and methylenetetrahydrofolate reductase (MTHFR) C677T mutation in patients with retinal artery occlusion. *Am J Ophthalmol* 2002;134(1):57-61.
23. Brown BA, Marx JL, Ward TP, et al. Homocysteine: a risk factor for retinal venous occlusive disease. *Ophthalmology* 2002;109(2):287-90.
24. Biousse V, Kerrison JB, Newman NJ. Is non-arteritic anterior ischemic optic neuropathy related to homocysteine? *Br J Ophthalmol* 2000;84(5):555.
25. Vine AK, Stader J, Branham K, et al. Biomarkers of cardiovascular disease as risk factors for age-related macular degeneration. *Ophthalmology* 2005;112(12):2076-80.
26. Roedl JB, Bleich S, Schlötzer-Schrehardt U, et al. Increased homocysteine levels in tear fluid of patients with primary open-angle glaucoma. *Ophthalmic Res* 2008;40(5):249-56.
27. Bleich S, Jünemann A, von Ahsen N, et al. Homocysteine and risk of open-angle glaucoma. *J Neural Transm* 2002;109(12):1499-504.
28. Vessani RM, Ritch R, Liebmann JM, Jofe M. Plasma homocysteine is elevated in patients with exfoliation syndrome. *Am J Ophthalmol* 2003;136(1):41-6.
29. Biousse V, Newman NJ, Sternberg P. Retinal vein occlusion and transient monocular visual loss associated with hyperhomocystinemia. *Am J Ophthalmol* 1997;124(2):257-60.
30. Wang G, Medeiros FA, Barshop BA, Weiner RN. Total plasma homocysteine and primary open-angle glaucoma. *Am J Ophthalmol* 2004;137(3):401-6.
31. Leibovitch I, Kurtz S, Shemesh G, et al. Hyperhomocystinemia in pseudoexfoliation glaucoma. *J glaucoma* 2003;12(1):36-9.
32. Bleich S, Roedl J, Von Ahsen N, et al. Elevated homocysteine levels in aqueous humor of patients with pseudoexfoliation glaucoma. *Am J Ophthalmol* 2004;138(1):162-4.
33. Altıntaş O, Maral H, Yüksel N, et al. Homocysteine and nitric oxide level in plasma of patients with pseudoexfoliation syndrome, pseudoexfoliation glaucoma and primary open-angle glaucoma. *Graefes Arch Clin Exp Ophthalmol* 2005;243(7):677-83.
34. Cumurcu T, Sahin S, Aydin E. Serum homocysteine, vitamin B 12 and folic acid levels in different types of glaucoma. *BMC Ophthalmol* 2006;6:6.
35. Turaçlı ME, Tekeli O, Ozdemir F, Akar N. Methylenetetrahydrofolate reductase 677 C-T and homocysteine levels in Turkish patients with pseudoexfoliation. *Clin Experiment Ophthalmol* 2005;33(5):505-8.
36. Vermaak WJ, Ubbink JB, Delport R, et al. Ethnic immunity to coronary heart disease? *Atherosclerosis* 1991;89(2-3):155-62.
37. Rasmussen K, Møller J. Total homocysteine measurement in clinical practice. *Ann Clin Biochem* 2000;37(Pt 5):627-48.
38. Ford ES, Smith SJ, Stroup DF, et al. Homocyst(e)ine and cardiovascular disease: a systematic review of the evidence with special emphasis on case-control studies and nested case-control studies. *Int J Epidemiol* 2002;31(1):59-70.