

## Brief report

---

# External Eye Resurfacing through Conjunctival-limbal-corneal Allograft: A Surgical Technique

Mehdi HosseiniTehrani, MD; Professor of Ophthalmology\*  
S-Farzad Mohammadi, MD, FICO; Assistant Professor of Ophthalmology\*  
Asou AliMahmoudi, MD\*  
Vandad Farhady, BSc\*  
\* Eye Research Center, Farabi Eye Hospital, Tehran University of Medical Sciences

Correspondence to: Dr S-Farzad Mohammadi; sfmohamm@razi.tums.ac.ir

### **Abstract**

We are describing a new surgical approach in the management of advanced ocular surface cicatrization through a single procedure conjunctival-limbal-corneal allograft in which the external eye is resurfaced; it involves a lamellar corneolimbal keratoplasty, 360° limbal stem cell transfer (on a “bipedicle” conjunctival-corneal carrier), and conjunctival tissue transplantation - all in a single continuous sheet but with two edges for suturing: donor corneal-limbal edge to recipient’s scleral-limbal edge (avoiding overlying stem cell element of the donor tissue) and donor’s and recipient’s conjunctival edges; fornices would be reconstructed if needed.

Keywords: Corneal Limbal Allograft, Limbal Stem Cell Deficiency, Ocular Surface Reconstruction

### **Introduction**

One of the most challenging situations in ophthalmology is (bilateral) ocular surface cicatrization associated with limbal stem cell deficiency, conjunctival loss, symblepharon formation and fornix obliteration, and corneal opacity and vascularization due to severe external eye chemical and/or thermal injury. The purpose of this article is to introduce a novel reconstructive procedure for this condition.

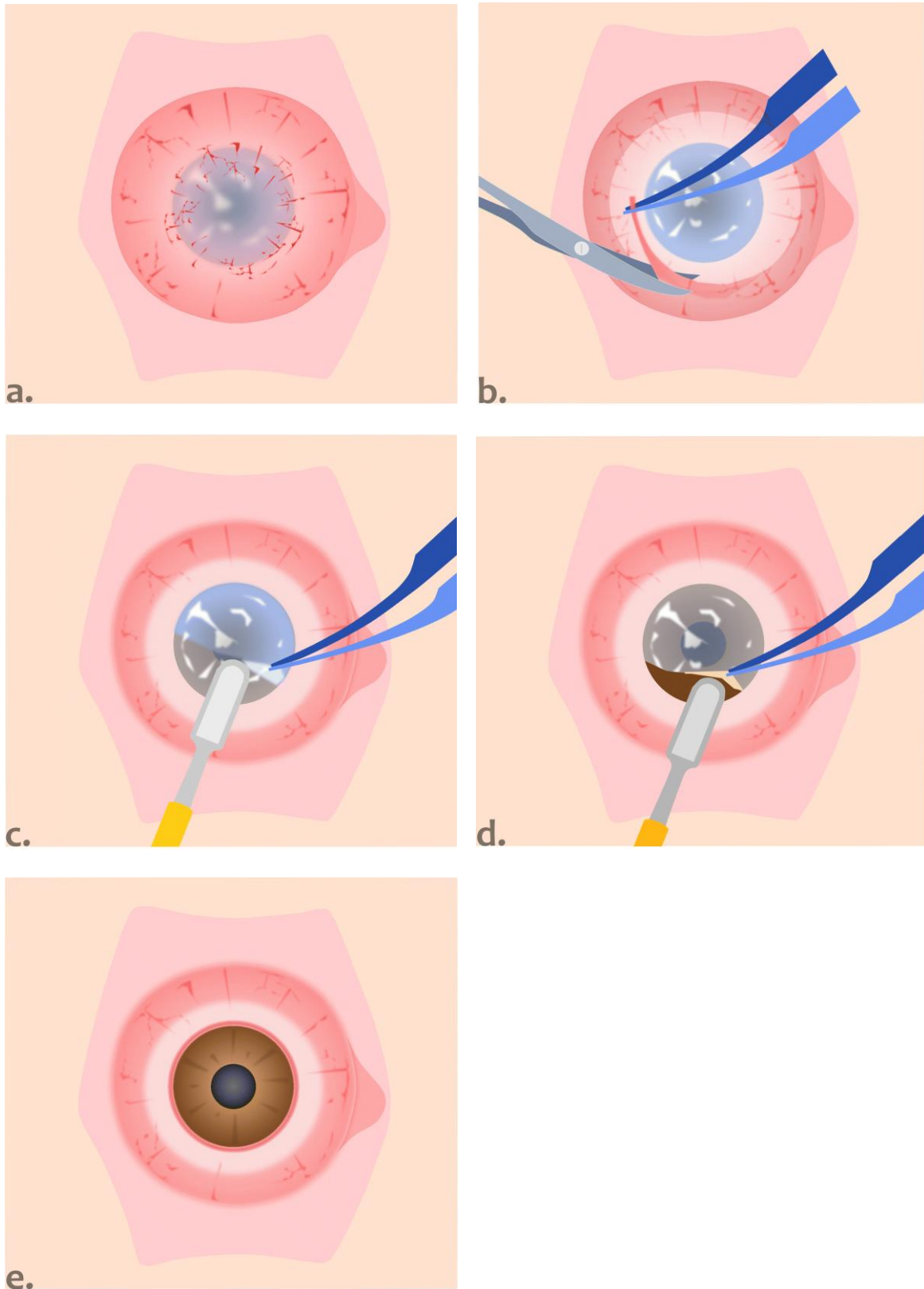
### **Technique**

It involves a single-procedure conjunctival-limbal-corneal allograft as follows (Figures 1 to 3):

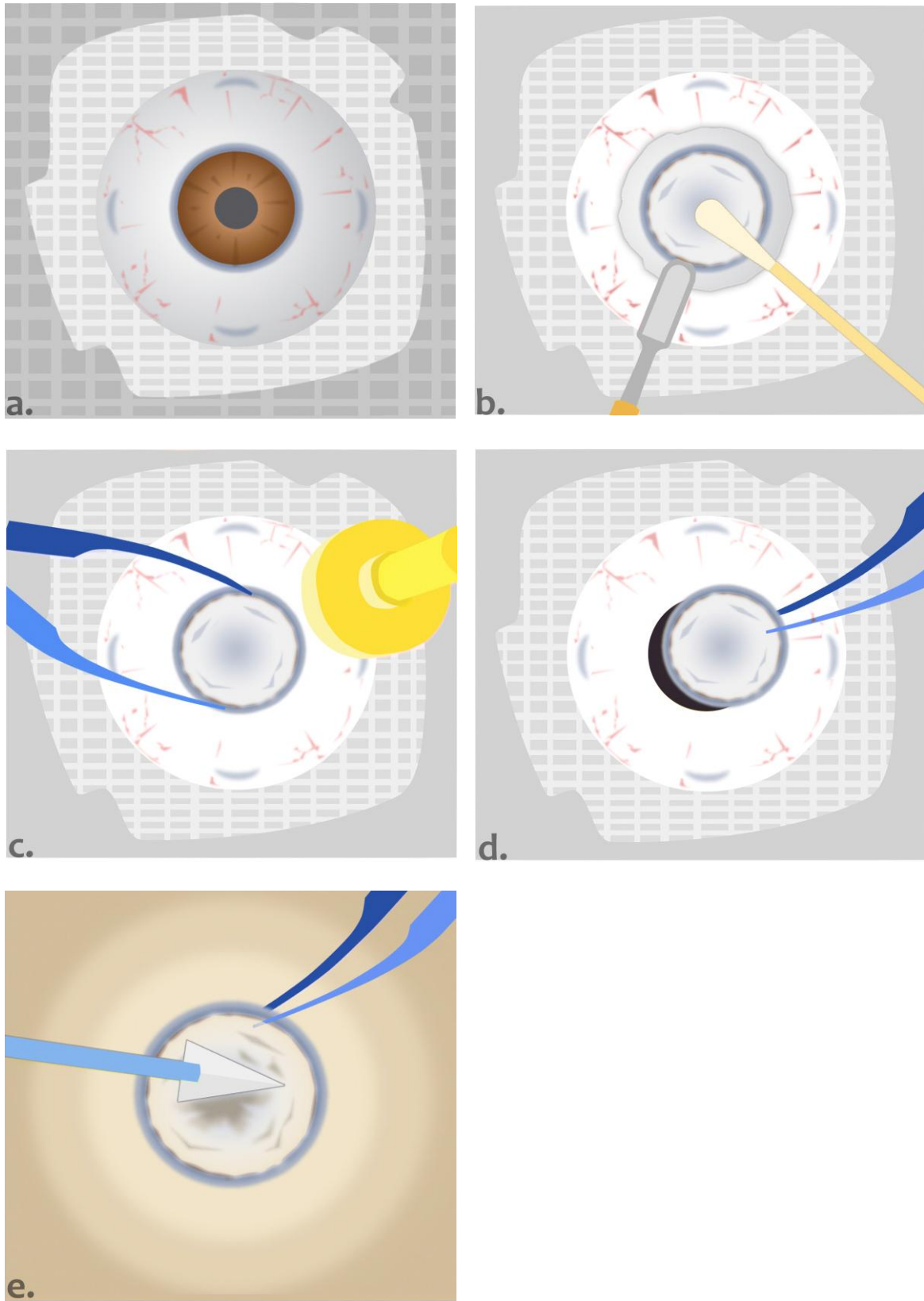
- Bed preparation: fibrovascular tissue and scarred conjunctiva are dissected centripetally from cornea to the fornices. Bipolar cautery is applied to the bed for hemostasis and coagulation of remaining neovascularizations. Partial thickness corneolimbal trephination is carried out and followed by a deep and extensive anterior lamellar dissection to obtain a clear bed – ideally a bare Descemet’s membrane.
- Donor preparation: fresh globe is harvested along with bulbar conjunctiva (within 6 hours of death; to be transplanted within 24 hours post-mortem). Dissection is carried out anteriorly in the conjunctival-Tenon’s capsule plane undermining beyond limbal stem cell zone to anterior limbus. The conjunctiva is then kept rolled over the corneal surface and a limbal epithelial side trephination sparing the rolled conjunctiva is performed. The donor endothelium-Descemet’s membrane is scraped off next.
- Suturing: the donor conjunctiva is maintained on the corneal top while suturing the donor’s corneal-limbal edge to the bed’s scleral-limbal edge. Conjunctiva is then rolled back and sutured to the recipient’s conjunctival free edge to reconstruct the fornices.

### **Perioperative management**

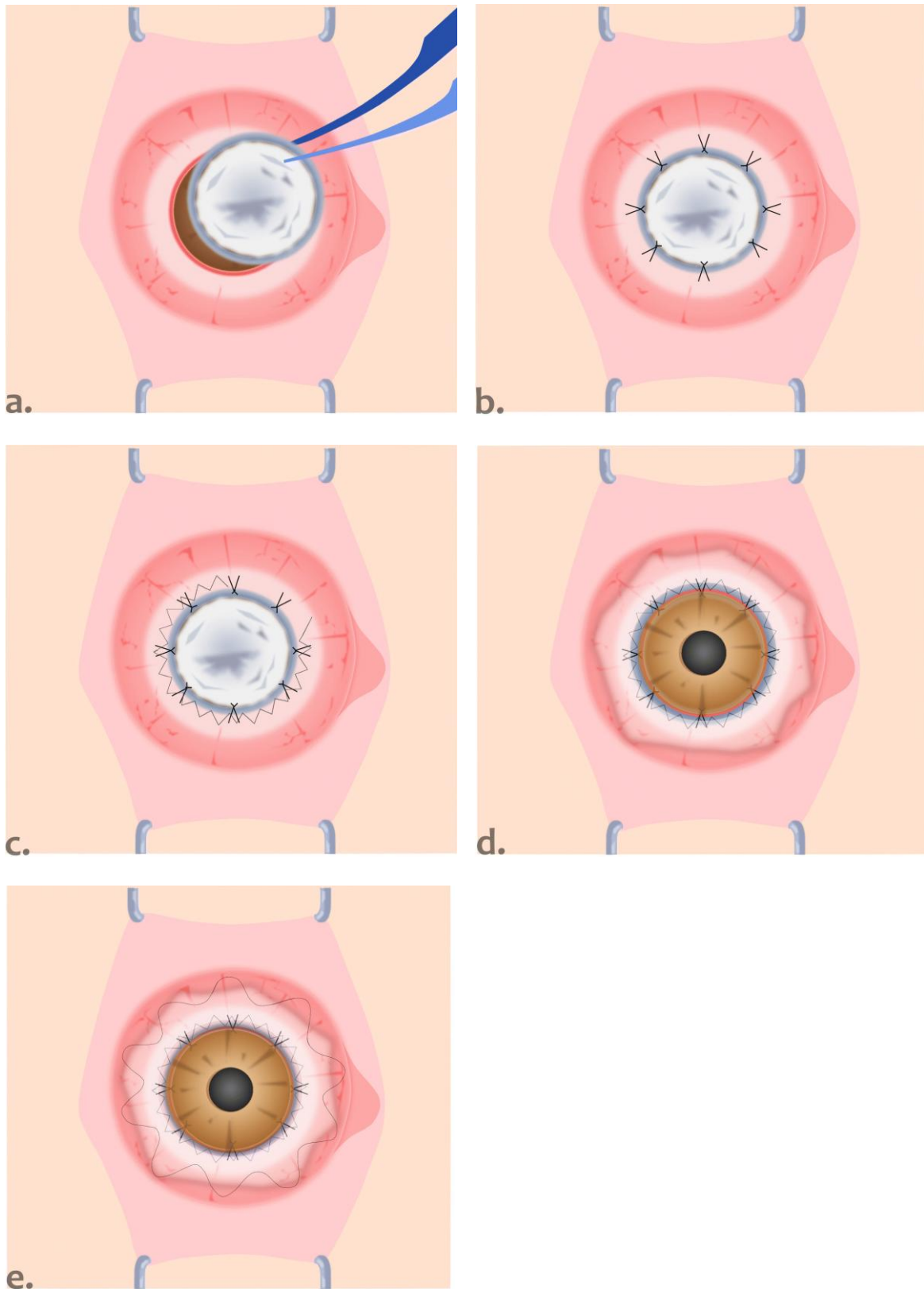
Prior to surgery the eyes would be treated by various combinations of topical steroids, lubricants (conventional or preservative-free), 10% N-acetylcysteine, and prophylactic antibiotics, and systemic vitamin C and tetracycline. Systemic cyclosporine 3-5 mg/Kg (minimum of 100 mg to a maximum of 300 mg) would be instituted one week before surgery which would be continued for 6 months; a dose of 100 mg/day would be maintained beyond 12 months. Sub-Tenon’s steroid (along with antibiotic) would be injected at the end of the operation and a bandage contact lens be fitted. Oral prednisolone 1-2 mg/Kg would be administered postoperatively to be tapered and discontinued in three months. Topical antibiotic, steroid, and lubricant should be prescribed.



**Figure 1.** Bed preparation; a. vascularized stem cell deficient external eye surface and corneal opacity (conjunctival shortage and scarring is not shown); b. dissection and removal of fibrovascular scar; c. & d. lamellar keratectomy; e. clear deep cornea of the recipient.



**Figure 2.** Donor preparation; a. fresh globe along with bulbar conjunctiva; b. dissection in the conjunctival-Tenon's capsule plane anteriorly beyond stem cell zone to anterior limbus; c & d. sizing and epithelial side trephination sparing the rolled over conjunctiva; e. scraping endothelium-Descemet's membrane.



**Figure 3.** Suturing; a. graft transfer; b & c. suturing donor's corneal-limbal edge to recipient's scleral-limbal edge while donor conjunctiva and stem cell sheet are rolled over; d. rolling back the conjunctiva and suturing donor's and recipient's conjunctival edges (forniceal reconstruction is not shown).

Schematic illustration of single procedure conjunctival-limbal-corneal allograft to re-surface the external eye (for detailed description of the procedure, see the text.)

### Discussion

Coster et al reported transplantation of the entire ocular surface in 1995<sup>1</sup> through different donor and recipient's bed preparation and suturing technique. Currently recommended procedure for a bilateral condition is combined living-related conjunctival-limbal allograft plus kerato-limbal allograft followed by penetrating or lamellar keratoplasty<sup>2</sup> or keratoprosthesis.

Large-diameter lamellar keratoplasty (incorporating donor limbal tissue) has been advocated to restore corneal clarity as well as limbal stem cells in a single procedure.<sup>3</sup> Deep anterior lamellar keratoplasty combined with conjunctival limbal autograft has been described (for unilateral cases).<sup>4,5</sup>

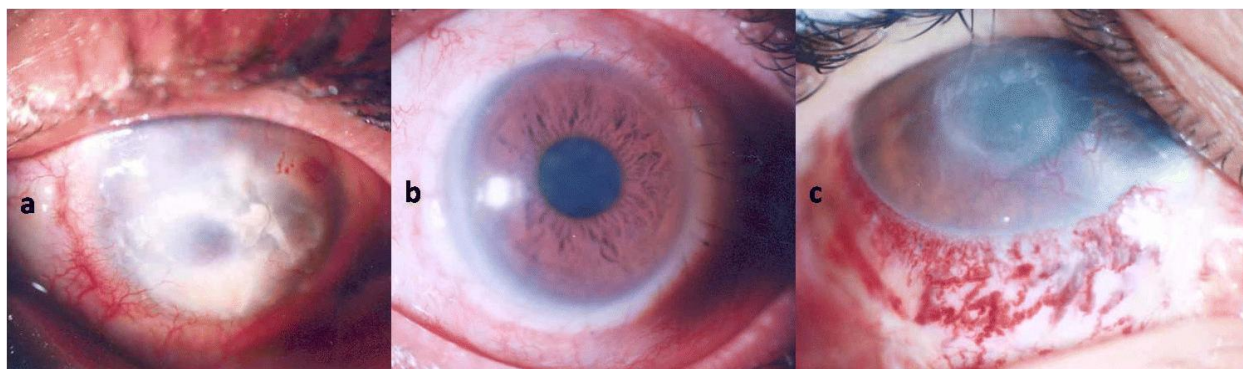
The approach described here carries several theoretical advantages namely, a single-procedure for reconstitution of limbal and conjunctival stem cells and restoration of corneal clarity; it potentially transfers a whole eye limbal stem cell population on a solid conjunctival-corneal carrier (analogous to a bipedicle graft) which should maximize stem cell preservation intraoperatively and viability postoperatively. Lamellar approach circumvents the risk for endothelial rejection and at the same time necessitates an intact deep corneal stroma and endothelium.

The technique is innovative in two respects (Figures 1 to 3):

- 1- Undermining the stem cell zone of the donor subconjunctivally to anterior limbus and rolling over the conjunctiva and limbal tissue prior to corneolimbal trephination. This yields a graft with two edges at donor conjunctiva and donor limbus.
- 2- Suturing of donor limbus to scleral-limbal recipient bed while donor conjunctival and limbal stem cell tissue are rolled over the donor cornea. This is followed by suturing the donor conjunctiva edge to recipient's fornix conjunctiva.

It should be noted that the preparation of donor material is time consuming and suturing of the corneolimbal button to the recipient bed while keeping conjunctival-stem cell elements of the graft protected and away is challenging. The harvested donor tissue should be that of a fresh globe along with bulbar conjunctiva. Cadaveric source of donor tissue may imply a lower growth potential.<sup>6</sup>

Authors believe that the approach can be considered as a last but versatile resort in the reconstruction of end-stage ocular surface (Figure 4) conditions but the viability of the technique should be formally studied in future trials; specifically, immunosuppression protocol have to be scrutinized as there is a massive allograft antigen transfer and exposure.



**Figure 4.** Outcome of external eye re-surfacing; a & b. successful outcome with its pre-op and 9 months post-op photo slit images. c. graft rejection at conjunctiva and cornea resulted in corneal opacity and vascularization.

\* No proprietary interest or financial support is involved in this work.

### References

1. Coster DJ, Aggarwal RK, Williams KA. Surgical management of ocular surface disorders using conjunctival and stem cell allografts. *Br J Ophthalmol* 1995;79(11):977-82.
2. Holland EJ. Epithelial transplantation for the management of severe ocular surface disease. *Trans Am Ophthalmol Soc* 1996;94:677-743.
3. Vajpayee RB, Thomas S, Sharma N, et al. Large-diameter lamellar keratoplasty in severe ocular alkali burns: A technique of stem cell transplantation. *Ophthalmology* 2000;107(9):1765-8.
4. Fogla R, Padmanabhan P. Deep anterior lamellar keratoplasty combined with autologous limbal stem cell transplantation in unilateral severe chemical injury. *Cornea* 2005;24(4):421-5.
5. Yao YF, Zhang B, Zhou P, Jiang JK. Autologous limbal grafting combined with deep lamellar keratoplasty in unilateral eye with severe chemical or thermal burn at late stage. *Ophthalmology* 2002;109(11):2011-7.
6. Vemuganti GK, Kashyap S, Sangwan VS, Singh S. Ex-vivo potential of cadaveric and fresh limbal tissues to regenerate cultured epithelium. *Indian J Ophthalmol* 2004;52(2):113-20.