

Idiopathic Retinal Vasculitis, Aneurysm, Neuroretinitis: A Significant Increase in Visual Acuity after Treatment with One Session of Panretinal Photocoagulation, Retinopexy and Three Consecutive Intravitreal Bevacizumab (Avastin) Injection

Hooshang Faghihi, MD¹ • Mona Seyed Safizadeh, MD²
Shahin Faghihi, MD³ • Houman Faghihi, MD⁴

Abstract

Purpose: To report an idiopathic retinal vasculitis, aneurysm, neuroretinitis (IRVAN) case treated with one session of panretinal photocoagulation (PRP) and intravitreal bevacizumab (Avastin)

Case report: A 13-year-old boy was diagnosed as an IRVAN syndrome. Systemic examination, fundus angiography, brain MRI were performed to evaluate the patient. Treatment with one session of PRP, retinopexy and 3 consecutive monthly intravitreal injection of 1.25 mg Bevacizumab was performed. After the second Bevacizumab injection, complete regression of neovascularizations and improvement of visual acuity (VA) to $3/10$ for right eye and $6/10$ for left eye was noted. By the other 2 additional monthly intravitreal injection of Bevacizumab, VA improved to $6/10$ and $8/10$ for right and left eye. The Aneurysms became smaller. After 6 months of his treatment, his VA was remained stable.

Conclusion: We reported a successful treatment effect of Bevacizumab as an adjunctive therapy in combination with PRP and retinopexy, for stage 3 IRVAN. Bevacizumab seems to have promising effects in the treatment of IRVAN.

Keywords: Idiopathic Retinal Vasculitis, Aneurysm, Neuroretinitis, Bevacizumab

Iranian Journal of Ophthalmology 2012;24(2):65-71 © 2012 by the Iranian Society of Ophthalmology

-
1. Professor of Ophthalmology, Eye Research Center, Farabi Eye Hospital, Tehran University of Medical Sciences, Tehran, Iran
 2. Resident in Ophthalmology, Eye Research Center, Farabi Eye Hospital, Tehran University of Medical Sciences, Tehran, Iran
 3. Researcher, Eye Research Center, Farabi Eye Hospital, Tehran University of Medical Sciences, Tehran, Iran
 4. DVM

Received: January 18, 2012

Accepted: May 10, 2012

Correspondence to: Hooshang Faghihi, MD

Professor of Ophthalmology, Eye Research Center, Farabi Eye Hospital, Tehran University of Medical Sciences, Tehran, Iran,
Email: hfaghihi@noorvision.com

© 2012 by the Iranian Society of Ophthalmology
Published by Otagh-e-Chap Inc.

Introduction

Idiopathic retinal vasculitis, aneurysms, neuroretinitis (IRVAN) syndrome is a rare entity of retinal vasculitis with unknown etiology. It is characterized by multiple aneurysmal dilations, retinal vasculitis, peripheral retinal ischemia and or retinal neovascularization and exudation.

Retinal ischemia, macular exudation and proliferative changes are the main causes of severe visual loss. Different treatment modalities are mentioned such as deep vitrectomy, photocoagulation, retinopexy, anti-VEGF, corticosteroids, anti-tumor necrosis factor agents.

Here, we report a patient with IRVAN syndrome, and describing its differential diagnosis and our treatment combination.

Case report

A 13-year-old healthy Iranian boy presented with subacute onset of bilateral blurred vision from 3 months ago. He had no systemic disease and his past medical history was not remarkable. He did not use any specific medication. His best corrected visual acuity (BCVA) was 1/10 and 3/10, respectively for his right and left eye. On slit-lamp biomicroscopy examination, there was not any pathologic findings. Intraocular pressure (IOP) was 12 and 11 mmHg respectively for his right and left eye. The ocular media was clear. On fundus examination, there were aneurysmal

dilations along the arteriols, at the bifurcation sites. Optic disc swelling and tortuous disc vessels, star shape macular exudation and peripheral neovascularizations also existed in his both eyes (Figure 1).

Fluorescein angiography revealed the macroaneurysms along the arteriols with late staining of vessel walls. In addition, there was a significant capillary non-perfusion area with neovascularizations (like sea-fan pattern). Late phase of fluorescein angiography disclosed staining of optic nerve head (Figure 2). Macular exudation and edema was shown in optical coherence tomography (OCT) (Figure 3).

Systemic review was performed to rule out any associated systemic disease such as hypertension, diabetes mellitus, tuberculosis, sickle cell disease, collagen vascular disease. Except of borderline PPD of 16 mm and high triglyceride level of 250 mg/dl, the other tests including fasting blood sugar, VDRL, ANA, PANCA, ACE was in their normal limits. Chest X-ray had normal appearance and smear & culture of sputum was negative. Because of high prevalence of tuberculosis in our country, QuantiFeron¹³ was also checked for the confirmation.

In order to detect any associated cerebral aneurysms, brain MRI was also performed which was normal.

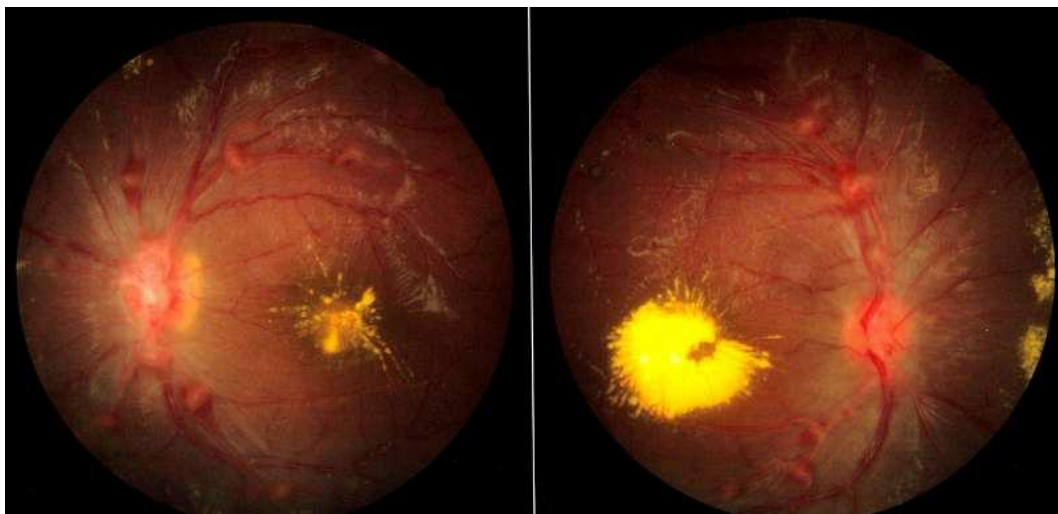


Figure1. Multiple aneurysmal dilations, optic disc swelling, macular exudation

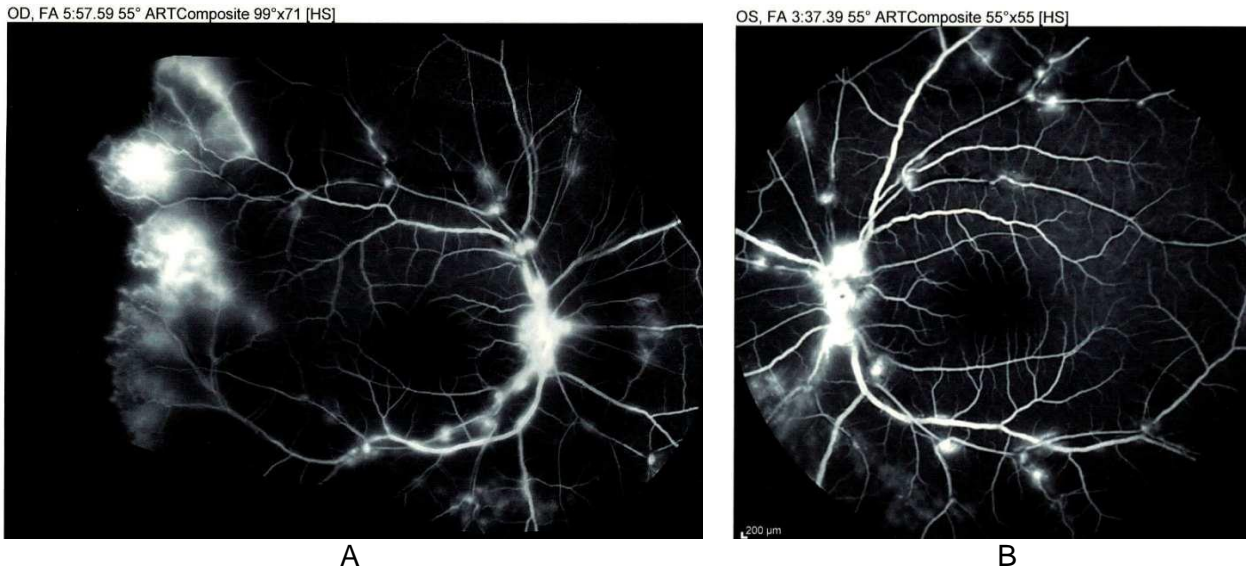


Figure 2. A) Right eye: aneurysmal dilations, capillary non-perfusion areas, late optic disc staining B) Left eye: aneurysmal dilations, late disc staining, capillary non-perfusion areas

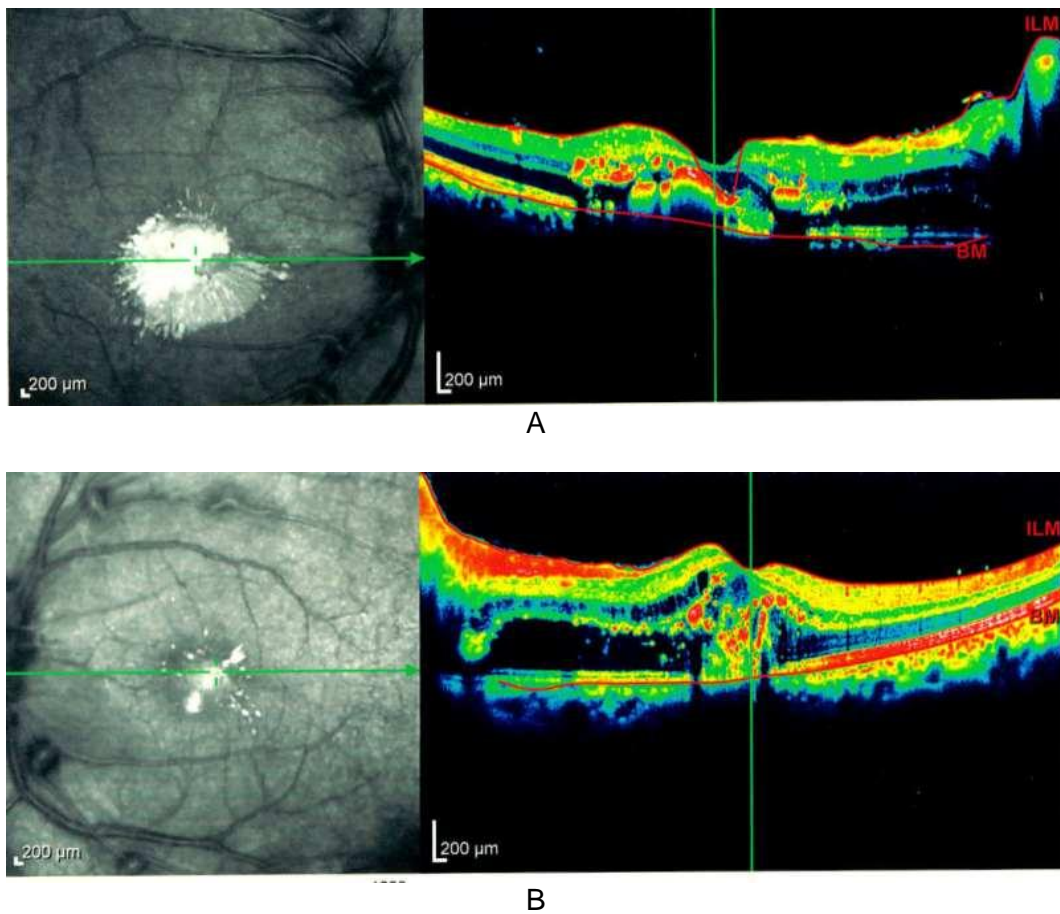


Figure 3. Macular exudation. A) Right eye B) Left eye

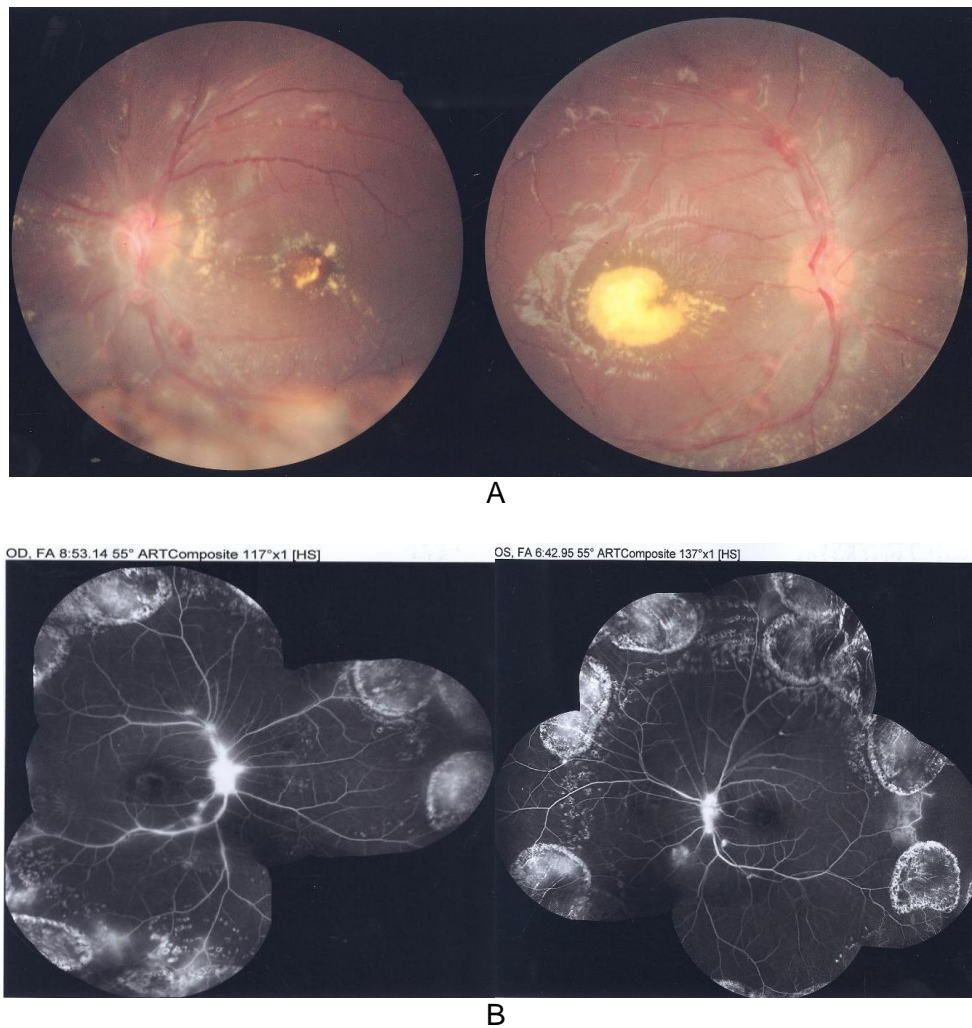


Figure 4. Three months after treatment. A) Fundus photograph B) Fluorescein angiography

Based on clinical examination, angiographic features and negative systemic work up, diagnosis of IRVAN was made. Neuroretinitis was diagnosed by late staining of the optic nerve head, tortuous disc vessels and retinal vasculitis. IRVAN is a clinical diagnosis and should be considered after excluding similar conditions. Because of proliferative retinal changes, our treatment includes retinal photocoagulation, retinopexy at the sites of capillary non-perfusion and 1.25 mg intravitreal bevacizumab (Avastin). We also gave oral prednisolone 50 mg daily to the patient, but because of the lack of strong evidence of its effects, it was tapered. After one month, his visual acuity (VA) was improved to $3/10$ and $6/10$, respectively for his right and left eye and there was a significant reduction in neovascularizations. We injected

additional 1.25 mg intravitreal Bevacizumab. One month after the second injection, the retinal neovascularizations was completely resolved and aneurysms became relatively smaller but VA was stable. For the third time, intravitreal injection of Bevacizumab was performed. One month after the third injection VA was improved to $6/10$ and $8/10$, for his right and left eye. In the follow-up period, no new aneurysm was formed and there was not any neovascular complication.

Discussion

As IRVAN is a rare syndrome, it is a diagnosis of exclusion.¹ It is not associated to any systemic findings.^{2,3} Differential diagnosis of retinal arterial aneurysm, peripheral capillary non-perfusion, exudative retinopathy and retinal neovascularizations include the

followings 1: Proliferative retinopathy^{1,2} such as diabetic proliferative retinopathy, sickle cell retinopathy, systemic vasculitis (systemic lupus erythematosus), hypercoagulopathy states. Another diagnosis is neuroretinitis,¹ due to both infectious and non-infectious causes such as tuberculosis, cat scratch disease, syphilis, hypertensive retinopathy, diabetes mellitus, AION, sarcoidosis. Our case has PPD of 16 mmHg with normal chest X-ray and smear & culture of sputum. We excluded tuberculosis by measuring QuantiFeron that was in the normal range. The other evaluations of this entity were not remarkable. Another differential diagnosis was Eales disease, an ischemic retinal vasculitis with progression to proliferative retinopathy and recurrent vitreous hemorrhage.^{1,3} It typically affected young male with bilateral involvement, like our patient. It is also associated with vestibule-auditory deficits and rarely cerebral infarctions.^{3,6} The differentiating aspects is more marked vascular inflammation of veins rather than arterioles^{1,6} and so the early staining of retinal vessels in Eales disease^{1,2} which is not existed in our case. Although capillary non-perfusion and retinal exudation are the prominent features of Coat's disease, retinal neovascularizations is rare. Coat's disease is mostly unilateral.¹

Our case is compatible with idiopathic retinal vasculitis as a component of the IRVAN syndrome. Exudative retinopathy, aneurysmal dilations and peripheral capillary non-perfusion are the aspects of inflammatory process in this syndrome. Neuroretinitis is diagnosed by late leakage of optic nerve head, tortuous disc vessels and retinal vasculitis.^{1,3} Fluorescein angiography clearly identified aneurysms, capillary non-perfusion, neovascularization, and late optic disc leakage.

IRVAN syndrome usually manifest in 3rd or 4th decade of life as bilateral involvement. It typically affects female, although it is also reported in males, as our patient.¹⁻³

For the first time, Kincaide & Cshaise⁴ reported two patients with bilateral retinal inflammation in which aneurysmal dilatations were a major manifestation. They named the syndrome "bilateral retinal arteritis with multiple aneurysmal dilatation". Chang et al³, in 1995 reported ten additional cases. They

defined three major criteria (retinal vasculitis, aneurysmal dilations at arterial bifurcations, and neuroretinitis) and 3 minor criteria (peripheral capillary nonperfusion, retinal neovascularizations, and macular exudation). They proposed the acronym IRVAN.

In 2006, Samuel et al² performed a retrospective interventional case series on 22 patients, 10 patients with additional follow-up of initial series and 12 additional patients identified since the first series. They suggested a classification scheme for staging retinal ischemia to determine treatment effects and natural history of the disease Table 1.

Table 1. A proposed staging by Samuel et al²

Stage	Findings
1	Macroaneurysms, exudation, neuroretinitis, retinal vasculitis
2	Capillary non-perfusion (F/A Evidence)
3	Posterior segment neovascularization of disc or elsewhere and/or vitreous hemorrhage
4	Anterior segment neovascularization (rubeosis iridis)
5	Neovascular glaucoma

The natural history of IRVAN is not predictable.³ Although Owens & Gregor⁵ reported a self-limiting course and spontaneous involution of arterial visual outcomes. Two factors are contributed in visual loss in these patients:¹⁻⁴ exudative maculopathy and the major factor, diffuse retinal ischemia and its neovascular sequelae: vitreous hemorrhage and neovascular glaucoma. Without any treatment it may lead to severe visual loss.^{2,3}

Based on classification of Samuel et al, our case is at stage 3. Samuel et al reported that most eyes that were treated in this stage, maintained VA $20/40$ or better. 25% of them progressed to VA $20/200$ or worse and 21% progressed to the development of anterior segment neovascularizations and neovascular glaucoma.² They used panretinal laser coagulation, corticosteroids, deep vitrectomy as their treatment modalities. Exact time of treatment initiation is controversial.² Central Vein Occlusion Study⁷ and Diabetic Retinopathy Study,⁸ proposed clear indications for initiating the treatment:

presence of rubeosis iridis in CRVO and high risk characteristics of proliferative retinopathy. In the second cohort study, Samuel et al² resulted that if panretinal photocoagulation is performed before or shortly after the development of neovascularizations, it would be more effective in maintaining visual outcomes and halting the progression of proliferative retinopathy. Once the neovascularizations has formed, there is a high rate of progressive neovascular complication despite of photocoagulation. Samuel et al,² proposed widespread retinal nonperfusion as an indication for early photocoagulation.

Steroids, in oral, topical and subtenon forms, did not show any significant effect on reducing the vasculitis and retarding the progression of neovascular complications in previous reports.³⁻⁵ Visual stability was reported just in 1 patient in Samuel et al's study.²

Cheema RA et al,¹² reported that intravenous Infliximab infusion had a very favorable treatment effect.

We treated our patient by photocoagulation and retinopexy for his diffuse retinal ischemia and neovascularizations to decrease the risk of sight threatening complications. We gave him 50 mg daily oral prednisolone, and since there was not any strong evidence of its effects in the literature, we tapered it in one month.

As anti-VEGF therapy has significant effect in angiogenic disease, like all subtypes of CNV, proliferative diabetic retinopathy and retinal vein occlusion.^{10,11} We injected 1.25 mg

intravitreal Bevacizumab (Avastin) monthly for 3 months, after stabilization of VA and regression of neovascularizations. We found no previous report of Bevacizumab injection in IRVAN syndrome. Dimitrios Karginias et al,⁹ in 2010 used Ranibizumab as an adjunctive treatment in their treatment modality for IRVAN at stage 3. Their patient had shown complete regression of retinal neovascularizations and significant improvement in VA.

In our case, one month after the treatment VA was improved to $3/10$ and $6/10$, respectively in right and left eye. Based on fluorescein angiography, neovascularizations was significantly regressed but not completely resolved. Based on clinical examination and OCT, macular exudation and edema was diminished. Final VA, one month after the 3rd Bevacizumab injection was $6/10$ for right eye and $8/10$ for left eye. Complete regression of retinal neovascularizations occurred after the 2nd injection and there was no enlargement of aneurysms. They became smaller after the 3rd injection. Intravitreal injection of Bevacizumab may have an encouraging role in halting the progression (Figure 3).

Conclusion

IRVAN is a diagnosis of exclusion. Early initiation of treatment in presence of any neovascularization have better visual prognosis. Intravitreal Bevacizumab, as an adjunctive therapy in stage 3, leads to a significant improvement of VA and regression of aneurysm.

References

1. McDonald HR. Diagnostics and therapeutics challenges. *Retina* 2003;23(3):392-9.
2. Samuel MA, Equi RA, Chang TS, et al. Idiopathic retinitis, vasculitis, aneurysms, and neuroretinitis (IRVAN): new observations and a proposed staging system. *Ophthalmology* 2007;114(8):1526-9.
3. Chang TS, Aylward GW, Davis JL, et al. Idiopathic retinal vasculitis, aneurysms, and neuroretinitis: Retinal Vasculitis Study. *Ophthalmology* 1995;102(7):1089-97.
4. Kincaid J, Schatz H. Bilateral retinal arteritis with multiple aneurysmal dilatations. *Retina* 1983;3(3):171-8.
5. Owens SL, Gregor ZJ. Vanishing retinal arterial aneurysms: a case report. *Br J Ophthalmology* 1992;76(10):637-8.
6. Renie WA, Murphy RP, Anderson KC, et al. The evaluation of patients with Eales' disease. *Retina* 1983;3(4):243-8.

7. A randomized clinical trial of early panretinal photocoagulation for ischemic central retinal vein occlusion. The Central Vein Occlusion Study Group N report. *Ophthalmology* 1995;102(10):1434-44.
8. Photocoagulation treatment of proliferative diabetic retinopathy: Clinical application of Diabetic Retinopathy Study (DRS) findings, DRS Report Number 8. The Diabetic Retinopathy Study Research Group. *Ophthalmology* 1981;88(7):583-600.
9. Karagiannis D, Soumplis V, Georgalas I, Kandarakis A. Ranibizumab for idiopathic retinal vasculitis, aneurysms, and neuroretinitis: favorable results. *Eur J Ophthalmol* 2010;20(4):792-4.
10. Cohen SY. Anti-VEGF drugs as the 2009 first-line therapy for choroidal neovascularization in pathologic myopia. *Retina* 2009;29(8):1062-6.
11. Ciulla TA, Rosenfeld PJ. Anti-vascular endothelial growth factor therapy for neovascular ocular diseases other than age-related macular degeneration. *Curr Opin Ophthalmol* 2009;20(3):166-74.
12. Cheema RA, Al-Askar E, Cheema HR. Infliximab therapy for idiopathic retinal vasculitis, aneurysm, and neuroretinitis syndrome. *J Ocul Pharmacol Ther* 2011;27(4):407-10.
13. Mazurek GH, Villarino ME; CDC. Guidelines for using the QuantiFERON-TB test for diagnosing latent Mycobacterium tuberculosis Infection. Centers for Disease Control and Prevention. *MMWR Recomm Rep* 2003;52(RR-2):15-8.