

A Case Report of Orbital Pseudotumor with Presentation like Orbital Cellulitis

Bahram Eshraghi, MD¹ • Alireza Keshtcar Jafari, MD²
Mohammad Reza Akbari, MD¹ • Babak Masoomian, MD³

Abstract

Purpose: To report a patient with orbital pseudotumor masquerading as orbital cellulitis

Case report: A 42-year-old woman was referred to orbit and oculoplastic clinic with 6 days history of left orbital pain, proptosis, lid edema and fever. Clinical finding included severe lid edema, chemosis, conjunctival injection and severe restriction in extraocular motility. She was diagnosed as orbital cellulitis and hospitalized for treatment with intravenous antibiotics. Because of no improvement, on the fifth day after admission, systemic corticosteroid, was prescribed. Diagnosis of orbital pseudotumor was made after significant response to systemic corticosteroids. Antibiotics were discontinued and systemic corticosteroid was tapered slowly during the 4 months.

Conclusion: Orbital pseudotumor is an ophthalmologic condition that may mimic a variety of pathologic processes. Despite complete physical examination and appropriate imaging, sometimes correct diagnosis of the disease would be difficult.

Keywords: Orbital Pseudotumor, Orbital Cellulitis

Iranian Journal of Ophthalmology 2012;24(3):58-61 © 2012 by the Iranian Society of Ophthalmology

Introduction

The current concept of inflammatory orbital pseudotumor is defined as an idiopathic tumor like inflammation made up of a pleomorphic inflammatory cellular response and a fibrovascular tissue reaction.^{1,2,4,8} Since it mimics a wide range of pathologic conditions, misdiagnosis and inappropriate treatment are likely.^{1,2,4,5} The potential for permanent visual dysfunction make orbital pseudotumor an ophthalmologic process that must not be overlooked.¹⁻³ We present a case of orbital pseudotumor that the patient under

the name of orbital cellulitis was admitted in our hospital and we started the medications for that purpose.

Case report

A 42-year-old woman with 6 days of left orbital pain and proptosis was referred to our hospital by another ophthalmologist. On arrival to our faculty, the patient complained of pain behind her left eye, proptosis, left side headache and fever. The pain was first noted 5 days ago and then progressed during that time.

-
1. Assistant Professor of Ophthalmology, Eye Research Center, Farabi Eye Hospital, Tehran University of Medical Sciences, Tehran, Iran
 2. Associate Professor of Ophthalmology, Eye Research Center, Farabi Eye Hospital, Tehran University of Medical Sciences, Tehran, Iran
 3. Fellowship in Pediatric Ophthalmology, Eye Research Center, Farabi Eye Hospital, Tehran University of Medical Sciences, Tehran, Iran

Received: December 22, 2011

Accepted: July 8, 2012

Correspondence to: Babak Masoomian, MD

Fellowship in Pediatric Ophthalmology, Eye Research Center, Farabi Eye Hospital, Tehran University of Medical Sciences, Tehran, Iran

Email: bmpk2001@yahoo.com

Her past medical history was positive for diabetes mellitus and she was treated with insulin since four years ago. She did not present history of thyroid dysfunction or orbital trauma. The previous laboratory tests which were taken by the patient showed good control of diabetes.

Visual acuity (VA) was $20/20$ in OD and $20/30$ in OS and relative afferent pupillary defect (RAPD) was negative. Ocular movement was limited in all directions and exacerbated the pain. The patient had 5 mm proptosis in the left eye and there was periorbital erythema, edema, indurations and warmth. There was no preauricular lymphadenopathy. Because of severe lid edema, slit-lamp examination was difficult, but there was +2 chemosis and +2 conjunctival injections with mild discharge in the left eye, cornea and anterior segment examination were normal (Figure 1). Fundoscopy examination after pupillary dilation showed +1 disc edema in OS, but there was good foveal reflex in both eyes.

Her vital signs included a temperature of 37.9°C , pulse of 83 beats/min, respiratory rate of 16 beats/min and blood pressure of $120/75$ mmHg.

In complete blood count test, white blood cell (WBC) was 12.7×10^9 /L with left ward shift and erythrocytes sedimentation rate (ESR) was 30 mm/h. Fasting blood sugar was controlled every morning and all the results were under 150 mg/dl.

Orbital CT scan showed no bony abnormalities and sinusal cavities were intact. There was significant proptosis and soft tissue thickening in the left eye. In retrobulbar cavity, increasing of soft tissue density was visible.

There was enlargement of superior rectus muscle and superior orbital vein that was significantly visible in axial view (Figure 2).

After visit in the emergency ward and according to the clinical patterns and radiological findings, the orbital cellulitis was diagnosed and the patient was hospitalized. The patient was treated with intravenous antibiotics (vancomycin 1 gr Bd, ceftazidime 1 g TDS and clindamycin 1 g BD). Three days after admission, there wasn't any improvement in the clinical manifestations, VA was reduced to $20/80$ in the left eye and ESR increased to 60 mm/h. On the fifth day after hospitalization, the patient was examined by our ophthalmologists, and because of the suspicion to orbital pseudotumor, oral prednisone (50 mg daily) was added to patient's drug list. After 24 hours, there was significant reduction in lid edema and ocular motility was improved. Two days after prednisone prescription, VA reached to $20/25$ in the left eye and proptosis significantly was reduced. Systemic antibiotic was discontinued completely.

Six days after prednisone administration; proptosis, lid edema and retrobulbar pain disappeared. She was discharged from hospital and after that she was managed for orbital pseudotumor (Figure 3). Systemic corticosteroid was tapered gradually during the next 4 months and the patient was visited in appropriated intervals. Two weeks after treatment we noticed mild to moderate ptosis in the left eye. With review of her previous portraits we found that ptosis was an old problem and it was not due to the new events.

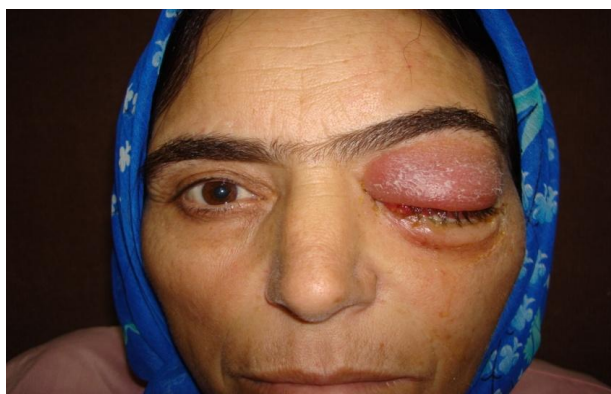

Figure 1. Patient portrait in first visit. Sever ptosis, lid edema and conjunctival prolapse are visible.

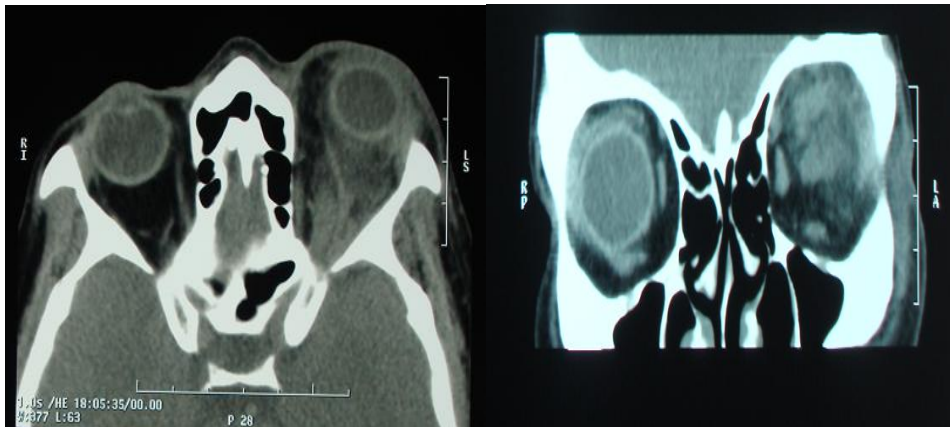


Figure 2. Orbital CT scan; axial and coronal view. Enlargement of superior rectus muscle and superior orbital vein, are noticeable.

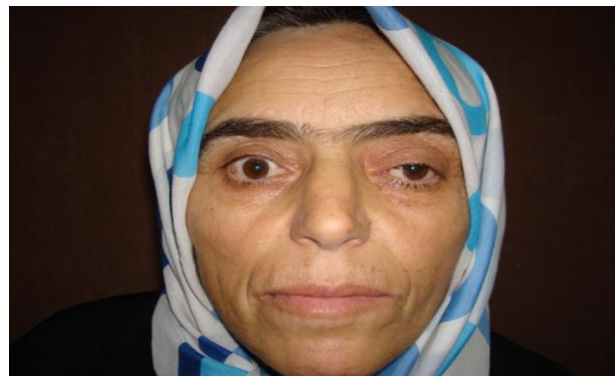


Figure 3. Patient 2 months after medication with prednisone, Moderate ptosis in the left eye is present.

Discussion

Idiopathic orbital inflammatory syndrome (IOIS), also known as orbital pseudotumor is a non-specific, non-neoplastic inflammatory process of the orbit.^{1,4}

Orbital pseudotumor is the third most common ophthalmologic disease of the orbit and account for approximately 8-10% of all orbital tumors.¹¹ Among the orbital pathology, only Graves disease and lymphoproliferative disease are more common.^{1,3,5}

Orbital pseudotumor is a kind of IOIS, that causes a variable degree of polymorphous infiltration and fibrosis, involving the orbital cavity diffusely or targeting specific anatomic structure such as the lacrimal gland or extraocular muscle.^{3,5,6,8}

Typical symptoms included pain, proptosis, local mass, lid edema and conjunctival injection. Diplopia, visual loss, ptosis and extraocular muscle dysmotility may also occur. Symptoms onset is usually acute, over hours to days, but subacute (week) and

chronic (week to months) presentation have also been described.^{2,3,5,6}

Orbital pseudotumor mimics other disease processes and the differential diagnosis is broad; including orbital cellulitis, retrobulbar abscess or hematoma, sarcoidosis, orbital tumors, Graves disease, Wegner granulomatosis and vasculitis.^{2,3,7}

Because of extreme variability of orbital pseudotumor symptomatology, imaging is a critical component of diagnosis. In orbital CT scan, the pseudotumor reveals a broad range of pathological changes. It may appear as an isolated discrete lesion with well-defined borders resembling neoplasm or specific granuloma. The inflammatory changes may remain localised to part of the globe resulting in an apparent thickening of the scleral margin. Myositic pseudotumor can mimic Grave's disease but in pseudotumor the involvement is less regular and unilateral with involvement of tendinous insertion of

extraocular muscles. Infiltrative changes in the adjacent fat, periorbital involvement or a discrete mass with thickened muscles favours the diagnosis of pseudotumor. Varying degrees of contrast enhancement of the abnormal soft tissue is seen in most cases of pseudotumors.^{3,5,6,8,11} Unfortunately, CT is not completely reliable in differentiating orbital pseudotumor from the potential causes, including bacterial inflammation.^{3,8}

According to our understanding and after review in some articles, we found that there are a few reports of orbital pseudotumor that patients presented symptoms of orbital cellulitis.^{3,9,10} Most of these reports are related to pediatric age group.^{4,10} In all previous reported cases there was not any sinus involvement.^{3,9,10}

On the other hand, there are some reports about correlation between orbital pseudotumor and sinusitis. Yan and Wu (2002), studied the incidence of sinusitis in patients with orbital pseudotumor and speculated that sinusitis may be a cause in the etiology of orbital pseudotumor. Among the 209 patients with orbital pseudotumor, 36 (17.2%) had evidence of sinusitis.¹²

Laboratory studies which may be of help, include elevated ESR, peripheral blood eosinophilia and in rare cases presence of serum antinuclear antibody (ANA).^{2,3}

Systemic corticosteroids therapy is the cornerstone of managing orbital pseudotumor; over 71% of patients show dramatic improvement within 24-48 hours of treatment. Starting dosage with 1.0 to 2.0 mg/kg/day of prednisone are adequate. When improvement is noted, dosage should be continued with a slow tapering, guided by clinical judgment.^{2,3,4,10}

In cases with uncertainly diagnosis, steroids resistance or recurrence, biopsy is suggested.^{2,3,4,8} For those patients who are refractory to corticosteroids, other treatment options included radiation therapy and immunosuppressive agents are used.^{2,3,4,8}

In this case, however, there was not sinus involvement and paranasal sinuses were clear in CT scan images, but clinical symptoms and radiologic finding; highly suggested orbital cellulitis. In fact it was orbital pseudotumor that was masquerading orbital cellulitis.

Conclusion

Orbital pseudotumor is an ophthalmologic disease that may mimics a variety of pathologic processes. Although complete physical examination and appropriate imaging are very important for orbital pseudotumor distinction, but sometimes correct diagnosis of the disease would be difficult.

References

1. Mombaerts I, Schlingemann RO, Goldschmeding R, Koornneef L. Idiopathic granulomatous orbital inflammation. *Ophthalmology* 1996;103(12):2135-41.
2. Jacobs D, Galetta S. Diagnosis and management of orbital pseudotumor. *Curr Opin Ophthalmol* 2002;13(6):347-51.
3. Chaudhry IA, Shamsi FA, Arat YO, Riley FC. Orbital pseudotumor: distinct diagnostic features and management. *Middle East Afr J Ophthalmol* 2008;15(1):17-27.
4. Yuen SJ, Rubin PA. Idiopathic orbital inflammation: distribution, clinical features, and treatment outcome. *Arch Ophthalmol* 2003;121(4):491-9.
5. Shields JA, Shields CL, Scartozzi R. Survey of 1264 patients with orbital tumors and simulating lesions: The 2002 Montgomery Lecture, part 1. *Ophthalmology* 2004;111(5):997-1008.
6. Yan J, Wu Z, Li Y. A clinical analysis of idiopathic orbital inflammatory pseudotumor. *Yan Ke Xue Bao* 2000;16(3):208-13.
7. Lee JY, Kim KD, Hwang EH, et al. Inflammatory orbital pseudotumor with infratemporal fossa extension mimicking temporomandibular joint dysfunction. *Dentomaxillofac Radiol* 2002;31(2):147-50.
8. Harris GJ. Idiopathic orbital inflammation: a pathogenetic construct and treatment strategy: The 2005 ASOPRS Foundation Lecture. *Ophthal Plast Reconstr Surg* 2006;22(2):79-86.
9. Anderson J, Thomas T. Orbital pseudotumour presenting as orbital cellulitis. *CJEM* 2006;8(2):123-5.
10. Sirbaugh PE. A case of orbital pseudotumor masquerading as orbital cellulitis in a patient with proptosis and fever. *Pediatr Emerg Care* 1997;13(5):337-9.
11. Weber AL, Romo LV, Sabates NR. Pseudotumour of the orbit. Clinical, pathologic, and radiologic evaluation. *Radiol Clin North Am* 1999;37(1):151-68.
12. Yan J, Wu Z, Li Y. [36 case idiopathic orbital inflammatory pseudotumour with sinus involvement. *Lin Chuang Er Bi Yan Hou Ke Za Zhi* 2002;16(8):410-1.