

Double Corneal Ring: Report of Simultaneous Coincidence of Kayser-Fleischer Ring and Fleischer Ring in a Keratoconus Patient Prior to Appearance of Wilson's Disease

Hamid Gharraee, MD¹ • Taher Soleimani, MD² • Reza Alizadeh, MD²

Abstract

Purpose: To report a case of simultaneous bilateral Fleischer and Kayser-Fleischer rings two years prior to appearance of any sign, symptom or laboratory data of the Wilson's disease

Case report: In this observational case report the examination and laboratory information of a 17-year-old Iranian female with blurred and decreased vision is introduced in a 2 years follow-up period. Complete ophthalmic examination, corneal topography, Orbscan corneal topography, laboratory tests [complete blood count (CBC), serum ceruloplasmin level, urine ceruloplasmin level, serum copper level, urine copper level] were done.

Results: In slit-lamp examination Kayser-Fleischer (KF) and Fleischer rings along with a corneal inferior cone was revealed. The topography and Orbscan imagings confirmed the diagnosis of keratoconus (KCN). Patient did not suffer from any systemic sign or symptoms. Her systemic physical examination was normal. All laboratory tests (liver function tests, serum and 24 hours urine copper level, serum ceruloplasmin level) were within normal limits. After two years of follow-up, fine hand tremors started, so she was referred for more investigations to neurologists. They confirmed that the signs might be due to Wilson's disease central nervous system involvement. In her latest laboratory examinations, her serum ceruloplasmin level was reported beneath the normal limits.

Conclusion: In our literature review there was no other resembling case in literature of coincidence of Wilson's disease and KCN. Hence we prefer to name it the first "double corneal ring" patient.

Keywords: Keratoconus, Wilson's Disease, Fleischer Ring, Kayser-Fleischer Ring

Iranian Journal of Ophthalmology 2012;24(4):57-62 © 2012 by the Iranian Society of Ophthalmology

1. Assistant Professor of Ophthalmology, Mashhad Eye Research Center, Khatam-al-Anbia Eye Hospital, Faculty of Medicine, Mashhad University of Medical Sciences, Mashhad, Iran
2. Resident in Ophthalmology, Mashhad Eye Research Center, Khatam-al-Anbia Eye Hospital, Faculty of Medicine, Mashhad University of Medical Sciences, Mashhad, Iran

Received: November 23, 2011

Accepted: May 19, 2012

Correspondence to: Reza Alizadeh, MD

Resident in Ophthalmology, Mashhad Eye Research Center, Khatam-al-Anbia Eye Hospital, Faculty of Medicine, Mashhad University of Medical Sciences, Mashhad, Iran, Email: reza39ali@gmail.com

Presented in 20th annual congress of the Iranian Society of Ophthalmology, Tehran, Iran, Nov 29 - Dec 2, 2010.

None of the authors received any financial support from any organization.

None of the authors has any financial interest in any product, method or material.

Introduction

Wilson's disease is an autosomal-recessive disease with a prevalence of near 1:30000. It is due to a loss of function of an adenosine triphosphatase, copper metabolism and affected excretion of copper.^{1,2} This malfunction is usually a consequence of a mutation in the ATP7B gene on chromosome 13, as a result copper transport to the bile is decreased and it starts to accumulate in target organs such as the liver, the brain and the eye.¹ The range of signs and symptoms is wide but among the presenting signs neurological presentations are the most prevalent (71.4%).³ What's more these signs are detected at a later age than liver dysfunction signs and symptoms.^{4,5} Two of the most prevalent ophthalmic signs of the disease are Kayser-Fleischer (KF) ring and sunflower cataract.⁴ The KF ring has been known to be associated with Wilson's disease for a long time,^{6,7,8,9,10} and is a consequence of corneal copper deposition.⁴ This sign is of high positive rate (96.8%)⁵ and is often found in patients with neurological problems.¹¹ The KF ring can be absent during the disease¹² or even can be found unilaterally.¹³ The size of KF ring is proportionate to the disease severity.¹⁴ Once the presence of KF ring was considered as the only pathognomonic sign of the disease,⁴ but other conditions have been found to be associated with this finding.^{15,16} Wilson's disease is confirmed by quantitation of copper in tissues.¹⁷ The most important laboratory tests are the serum ceruloplasmin, the urinary copper and for sure, liver biopsy.⁴ Treatment is chelation of excess copper with drugs like penicillamine along with a low copper intake.^{4,17}

Maintenance therapy for life is inevitable.⁴ A good treatment will cause a reduction in the KF ring size.¹⁸⁻²⁰ On the other hand, keratoconus (KCN), the most common primary ectasia, is a multifactorial disease with a diverse pattern of inheritance, it can be sporadic or can have a dominant inheritance in some families.²¹ KCN is a bilateral corneal disease with 1:2000 incidence in general population.²² In adolescence as a result of corneal stromal thinning, a cone-shaped cornea will develop and consequently induced myopia and irregular astigmatism will lead to decreased visual acuity (VA).²²⁻²⁴ In moderate and advance cases, a hemosiderin arc or

circle line, known as Fleischer's ring, is frequently seen around the cone base.²¹

Although pathological pathways of this disease are not completely understood, some investigations support the role of proteinases.^{25,26} Between different diagnostic devices corneal topography is the most beneficial in the diagnosis of this disease.²⁷ Various treatment have been proposed so far which include spectacles,²⁴ contact lenses,^{28,29} corneal rings,³⁰⁻³² cross-linking procedure³³⁻³⁵ and penetrating keratoplasty.²⁴

Case report

Fifteen-year-old Iranian female was referred to our clinic by his family physician for more evaluation of bilateral blurred vision in September 2008. A complete previous medical history, drug history and ocular history was obtained. Complete physical examination was done. Ocular examination with slit-lamp biomicroscopy, gonioscopy, applanation tonometry and complete funduscopy examination was performed. Corneal topography and Orbscan procedure were taken. Uncorrected visual acuity (UCVA) and best corrected visual acuity (BCVA) was measured by ETDRS and dry refraction was obtained as well. Laboratory examination of complete blood count (CBC), serum ceruloplasmin level, urine ceruloplasmin level, serum copper level, urine copper level were taken. Gastrointestionologic and neurologic consults were done. The patient was visited regularly in a 2-year period in a regular basis and all the above mentioned procedures were applied.

Results

The patient's chief complaint was blurred vision. She was otherwise healthy and no sign or symptom of any general systemic diseases was apparent. BCVA was $20/50$ in the right eye and $20/200$ in the left eye. In external eye movement no tropia or phoria was found. Range of external ocular movement was within normal limits. In the slit-lamp examination eye lids, conjunctiva, anterior chamber (AC) depth and iris were normal in both eyes. Intraocular pressure (IOP) was measured by applanation tonometry and was 11 mmHg in both eyes. Nearly symmetrical KF ring was visible in Descemet's membrane

accompanied by Fleischer ring in corneal stroma (Figures 1, 2). Her funduscopy was within normal limit bilaterally. Her dry refraction was -2.50: -8.50 15° for the right eye and -4.00:-7.50 160° for the left eye and keratometric reading (KR) was (60*105 and 52*15) for the right eye and (61*70 and 54*160). In retinoscopy scissor reflex was obvious on both eyes. Gonioscopy emphasize the existence of KF ring (Figure 3). To confirm the clinical diagnosis of KCN corneal topography and Orbscan (Figures 4, 5) were done which were characteristic of KCN because cone was visible in both eyes. Due to existence of KF ring and to rule out any systemic disorder, specially Wilson's disease, neurological and gastrointestional consult along with laboratory tests were done. All of them were normal. Patient did not agree to undergo liver biopsy. There was no family history of Wilson's disease in any of the family members. As a result Wilson's disease was ruled out then. After two years of follow-up, she began to experience systemic problems, such as tremor and difficulty in her speech. Her ophthalmologic examination was the same as before. Her BCVA improved to $20/30$ in the right eye and $20/25$ in the left eye by using spectacles, as a result of inability to stand rigid contact lenses. Her dry refraction was -3.00: -9.00 25° for the right eye and -4.50: -7.25 150° for the left eye and KR was (64*110 and 54*10) for the right eye and (65*75 and 53*165) for the left eye. Due to systemic problems another neurological consult was done and systemic laboratory data was asked and the results were compatible with Wilson's disease. As the result treatment for the disease was started in September 2010 with chelating drugs.

Patient's laboratory data are summarized in table 1.

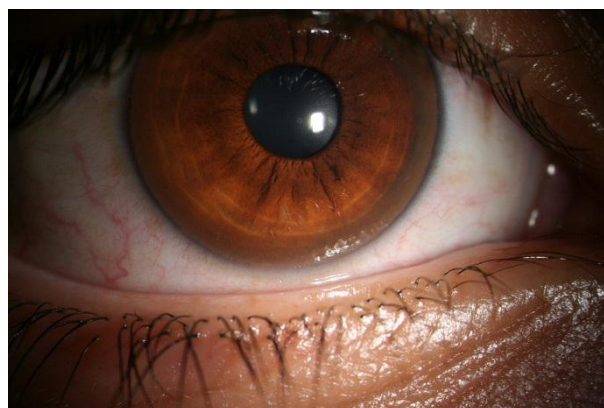


Figure 1. Patient's slit-lamp photography, a brownish circle is visible parallel to limbus, compatible with Kayser-Fleischer ring and also a Fleischer ring is visible

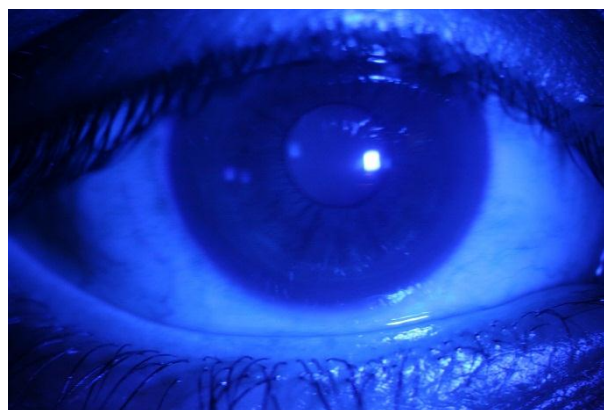

Figure 2. Patient's slit-lamp photography with blue filter. The Kayser-Fleischer ring is obviously visible.




Figure 3. Patient's gonioscopic photography, the presence of both rings is reinforced.

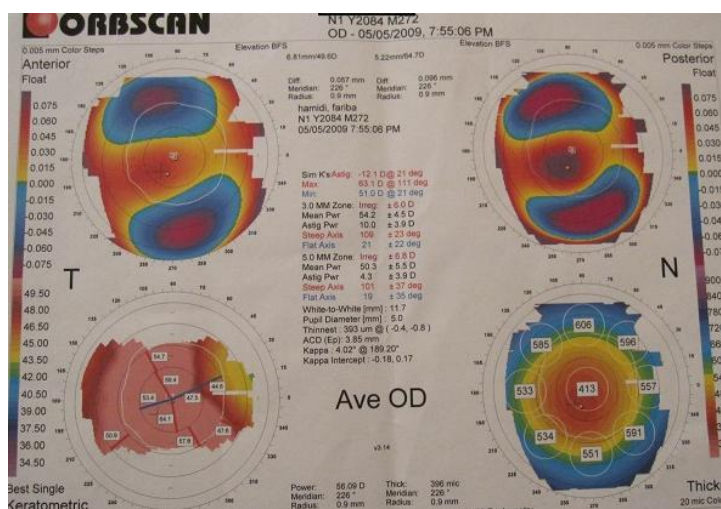


Figure 4. Patient's right eye Orbscan, the findings are compatible with keratoconus disease.

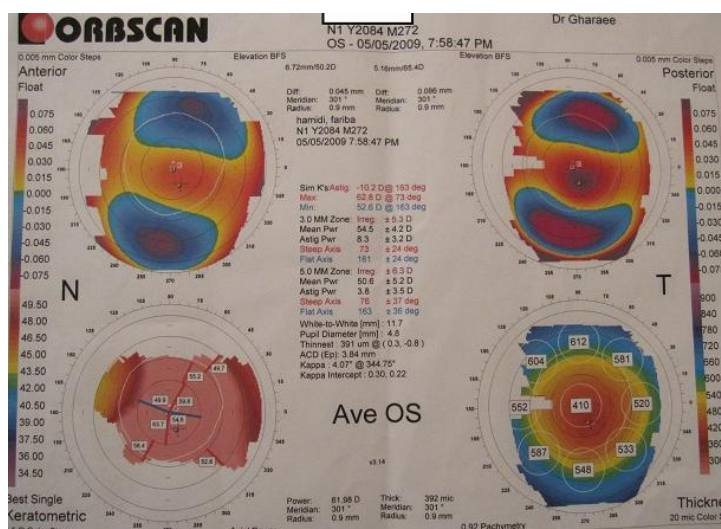


Figure 5. Patient's left eye Orbscan, it shows a somehow symmetrical findings with the right eye, highlighting the keratoconus diagnosis.

Table 1. Patient's laboratory data

	September 2008	June 2009	September 2009	June 2010	September 2010	Normal Range
White Blood Cells	7 * 10 ³	6 * 10 ³	6.3 * 10 ³	7.4 * 10 ³	6.7 * 10 ³	5-11 * 10 ³ / μl
Red Blood Cells	4.26 * 10 ⁶	5 * 10 ⁶	4.5 * 10 ⁶	3.7 * 10 ⁶	4.97 * 10 ⁶	3.8-5.5 * 10 ⁶ / μl
Hemoglobin	13.2	15	13.5	11.2	13.7	12-15.5 g/dl
Hematocrit	37.8	45	40	34.5	42.3	35.0-54.0 %
Platelets	162 * 10 ³	250 * 10 ³	190 * 10 ³	243 * 10 ³	188 * 10 ³	150-450 * 10 ³ / μl
Total Bilirubin	0.4	0.3	0.4	0.3	0.3	0.1-1.2 mg/dl
Direct Bilirubin	0.2	0.1	0.15	0.1	0.1	Less than 0.3 mg/dl
Aspartate transaminase	19	24	25	26	21	Less than 40 U/L
Alanine transaminase	18	25	20	24	17	Less than 40 U/L
Alkaline Phosphatase	350	500	400	346	323	180-1200 (in less than 18 years old patients) IU/L
Serum Ceruloplasmin	250	300	290	278	Less than 145	204-407 mg/l
Serum Copper	98	100	120	120	60	80-155 micg/dl
Urine Copper	120	100	111	118	240	Up to 150 micg/24 hrs

Discussion

Our presented case is unique in two aspects: 1- KF ring can be the first sign of the Wilson's disease but at the same time other laboratory tests are suggestive of the disease and support the diagnosis.³⁶ But in our case for near two years there was no sign, no symptom and no laboratory data compatible with the Wilson's disease.

2- An association between KCN with some other diseases was reported before, diseases such as Down syndrome, Turner syndrome, mitral valve prolaps, Leber's congenital amaurosis, collagenosis, retinitis pigmentosa and Marfan syndrome.²² In our literature review we were not able to find any report of simultaneous occurrence of KCN and the Wilson's disease.

We believe that this is a coincidence rather than a causative effect, as long as there is no acceptable hypothesis that Wilson's disease would change the collagen fibers integrity and biomechanics to induce KCN. On the other hand we do strongly believe that changing the biomechanics of the cornea due to KCN can help the copper to house in descemet's membrane earlier than we expect. The same

theory that is responsible for the formation of Fleischer ring in cornea can be assumed for KF ring; high concentration of copper and a good bed for accumulation. What is interesting in the presented case is the fact that copper serum level was normal as long as the other laboratory data were normal at the time of presentation and for near two years, this is where we think KCN has helped; it decreased the threshold for copper to accumulate, even when the serum level was still within normal limits.

Conclusion

Another important aspect of this case is the importance for meticulous follow-up of each patient presenting with KF ring even if the patient does not show any sign or symptom of Wilson's disease. Our patient was routinely visited every 6 months and as a result we were able to find out and diagnose the Wilson's disease as soon as possible which led to accelerated initiation of treatment, expecting a better prognosis.

References

1. Chilcott-Lauber C, Burkhard PR, Giostra E. [Wilson's disease: Clinical presentations]. *Rev Med Suisse*. 2005;1(31):2018, 2020-2. [Article in French]
2. Noble JA. A case study: identifying a new case of Wilson's disease. *J Am Acad Nurse Pract* 2005;17(12):512-7.
3. Bono W, Moutie O, Benomar A, et al. [Wilson's disease. Clinical presentation, treatment and evolution in 21 cases]. *Rev Med Interne* 2002;23(5):419-31. [Article in French]
4. Herron BE. Wilson's disease (hepatolenticular degeneration). *Ophthalmic Semin* 1976;1(1):63-9.
5. Gao WS, Liu YW, Chen J. [Analysis of 128 Wilson's disease]. *Zhongguo Yi Xue Ke Xue Yuan Xue Bao* 2001;23(5):506-8. [Article in Chinese]
6. Wilson SA. Kayser-Fleischer ring in cornea in two cases of Wilson's disease (Progressive Lenticular Degeneration). *Proc R Soc Med* 1934;27(3):297-8.
7. Palmer GB. A case of Wilson's disease with Kayser Fleischer ring. *N Z Med J* 1951;50(275):56-7.
8. Topalis C, Georgariuo B. [Diagnostic value of the Kayser-Fleischer ring]. *Arch Ophtalmol Rev Gen Ophtalmol* 1958;18(4):444-6. [Article in French]
9. Cairns JE, Walshe JM. The Kayser Fleischer ring. *Trans Ophthalmol Soc U K* 1970;90:187-90.
10. McArdle MJ. Wilson's Disease with Kayser-Fleischer Ring. *Proc R Soc Med* 1937;30(7):858.
11. Huo LJ, Liao RD, Chen XM. [Ophthalmic manifestations of Wilson's disease]. *Zhonghua Yan Ke Za Zhi* 2008;44(2):128-30. [Article in Chinese]
12. Makharia GK, Nandi B, Garg PK, Tandon RK. Wilson's disease with neuropsychiatric manifestations and liver disease but no Kayser-Fleischer ring. *J Clin Gastroenterol* 2002;35(1):101-2.

13. Innes JR, Strachan IM, Triger DR. Unilateral Kayser-Fleischer ring. *Br J Ophthalmol* 1986;70(6):469-70.
14. Rodman R, Burnstine M, Esmaeli B, et al. Wilson's disease: presymptomatic patients and Kayser-Fleischer rings. *Ophthalmic Genet* 1997;18(2):79-85.
15. Tauber J, Steinert RF. Pseudo-Kayser-Fleischer ring of the cornea associated with non-Wilsonian liver disease. A case report and literature review. *Cornea* 1993;12(1):74-7.
16. Frommer D, Morris J, Sherlock S, et al. Kayser-Fleischer-like rings in patients without Wilson's disease. *Gastroenterology* 1977;72(6):1331-5.
17. Woods SE, Colón VF. Wilson's disease. *Am Fam Physician* 1989;40(1):171-8.
18. Esmaeli B, Burnstine MA, Martonyi CL, et al. Regression of Kayser-Fleischer rings during oral zinc therapy: correlation with systemic manifestations of Wilson's disease. *Cornea* 1996;15(6):582-8.
19. Suvarna JC. Kayser-Fleischer ring. *J Postgrad Med* 2008;54(3):238-40.
20. Mitchell AM, Heller GL. Changes in Kayser-Fleischer ring during treatment of hepatolenticular degeneration. *Arch Ophthalmol* 1968;80(5):622-31.
21. Nielsen K, Hjortdal J, Pihlmann M, Corydon TJ. Update on the keratoconus genetics. *Acta Ophthalmol* 2012 Apr 4. doi: 10.1111/j.1755-3768.2012.02400.x. [Epub ahead of print]
22. Grünauer-Kloevekorn C, Duncker GI. [Keratoconus: epidemiology, risk factors and diagnosis]. *Klin Monbl Augenheilkd*. 2006;223(6):493-502. [Article in German]
23. Rosca C. [Diagnostic and therapeutic methods in keratoconus]. *Oftalmologia* 2009;53(4):13-9. [Article in Romanian]
24. Holopainen J, Krootila K. [Keratoconus]. *Duodecim* 2010;126(2):152-8. [Article in Finnish]
25. Balasubramanian SA, Pye DC, Willcox MD. Are proteinases the reason for keratoconus? *Curr Eye Res* 2010;35(3):185-91.
26. Collier SA. Is the corneal degradation in keratoconus caused by matrix-metalloproteinases? *Clin Experiment Ophthalmol* 2001;29(6):340-4.
27. Dumitrica DM, Colin J. Indices for the detection of keratoconus. *Oftalmologia* 2010;54(2):19-29.
28. Garcia-Lledo M, Feinbaum C, Alio JL. Contact lens fitting in keratoconus. *Compr Ophthalmol Update* 2006;7(2):47-52.
29. Lembach RG. Use of contact lenses for management of keratoconus. *Ophthalmol Clin North Am* 2003;16(3):383-94, vi.
30. Koller T, Seiler T. [Therapeutic cross-linking of the cornea using riboflavin/UVA]. *Klin Monbl Augenheilkd* 2007;224(9):700-6.
31. Wollensak G. Crosslinking treatment of progressive keratoconus: new hope. *Curr Opin Ophthalmol* 2006;17(4):356-60.
32. Snibson GR. Collagen cross-linking: a new treatment paradigm in corneal disease - a review. *Clin Experiment Ophthalmol* 2010;38(2):141-53.
33. Piñero DP, Alio JL. Intracorneal ring segments in ectatic corneal disease - a review. *Clin Experiment Ophthalmol* 2010;38(2):154-67.
34. Ertan A, Colin J. Intracorneal rings for keratoconus and keratectasia. *J Cataract Refract Surg* 2007;33(7):1303-14.
35. Colin J, Simonpoli-Velou S. The management of keratoconus with intrastomal corneal rings. *Int Ophthalmol Clin* 2003;43(3):65-80.
36. Liu M, Cohen EJ, Brewer GJ, Laibson PR. Kayser-Fleischer ring as the presenting sign of Wilson disease. *Am J Ophthalmol* 2002;133(6):832-4.