

# Cataract Surgery Management in Eyes with Extensive Iridoschisis

Hassan Hashemi, MD<sup>1,2</sup> • Golshan Latifi, MD<sup>3</sup>  
Sasan Moghimi, MD<sup>4</sup> • S-Farzad Mohammadi, MD<sup>5</sup>

---

## Abstract

**Purpose:** To demonstrate an approach to the problems of cataract surgery in extensive iridoschisis

**Methods:** Four eyes of 2 patients with extensive iridoschisis had cataract surgery by the same surgeon using the techniques that resembled techniques for phacoemulsification in intraoperative floppy iris syndrome (IFIS). We used low flow parameters on phacoemulsification, used super-cohesive ophthalmic viscosurgical devices (OVDs), avoided iris stretching, inserted iris hooks, administered topical atropine preoperatively, and injected intracameral epinephrine.

**Results:** Iris fibrils remained immobile during the procedure, and despite the severity of iridoschisis, there was no iris attachment to phaco tip, iris billowing, or iris prolapse during phacoemulsification. None of the eyes developed posterior capsule rupture.

**Conclusion:** In severe iridoschisis patients, there are risks of aspiration of iris fibers and iris prolapse during cataract surgery. These might be prevented by combination of using super-cohesive OVDs, avoidance of iris stretching, insertion of iris hooks, preoperative administration of topical atropine, and intracameral epinephrine.

**Keywords:** Iridoschisis, Phacoemulsification, Atropine, Epinephrine, Floppy Iris

*Iranian Journal of Ophthalmology 2012;24(4):40-44 © 2012 by the Iranian Society of Ophthalmology*

---

## Introduction

Iridoschisis is a rare condition characterized by separation of the anterior and posterior iris layers.<sup>1</sup> The pigmented layer appears normal, many of the stromal fibers go through a degenerative process in which they detach and free float in the anterior chamber,<sup>2</sup>

creating a shredded wheat appearance. These features are usually seen in the inferior half of the iris, but can affect entire iris in severe cases.<sup>2,3</sup> It is associated with other ocular conditions such as keratoconus,<sup>1</sup> cataract and glaucoma.<sup>5</sup>

- 
1. Noor Ophthalmology Research Center, Noor Eye Hospital, Tehran, Iran
  2. Professor of Ophthalmology, Eye Research Center, Farabi Eye Hospital, Tehran University of Medical Sciences, Tehran, Iran
  3. Resident in Ophthalmology, Eye Research Center, Farabi Eye Hospital, Tehran University of Medical Sciences, Tehran, Iran
  4. Associate Professor of Ophthalmology, Eye Research Center, Farabi Eye Hospital, Tehran University of Medical Sciences, Tehran, Iran
  5. Assistant Professor of Ophthalmology, Eye Research Center, Farabi Eye Hospital, Tehran University of Medical Sciences, Tehran, Iran

Received: April 19, 2012

Accepted: September 9, 2012

Correspondence to: Sasan Moghimi, MD

Associate Professor of Ophthalmology, Eye Research Center, Farabi Eye Hospital, Tehran University of Medical Sciences, Tehran, Iran, Email: sasanimii@yahoo.com

We state that our only interest is academic and we have no financial interest in this publication.

Competing interests: There is no competing interest.

Phacoemulsification is challenging because the free-floating iris fibrils immediately attach to the phaco tip and the irrigation/aspiration (I/A) needle by the fluidic negative forces. Also poor pupil dilation, and iris prolapse might affect cataract surgery in severe cases.<sup>2,3,6</sup>

The use of flexible iris hooks<sup>2</sup> or the pupil expander,<sup>7</sup> high molecular weight ophthalmic viscosurgical devices (OVDs)<sup>6</sup> has been reported to help keep fibrillar material out of pupil area during phacoemulsification. But most of these measures have been applied when only a segment of iris, specially the inferior zone, is involved. In this study, we describe phacoemulsification in 4 eyes with extensive iridoschisis. All of them successfully managed with minimal iris trauma or other complications. The technique include use of low flow parameters on phacoemulsification, use of super-cohesive OVDs, avoidance of iris stretching, insertion of iris hooks, preoperative administration of topical atropine, and intracameral epinephrine.

## Methods

### Informed consent

Written Informed consent was obtained from all the patients after complete explanation

### Surgical technique

Atropine 1% was administered twice daily for 10 days preoperatively. This is supplemented by tropicamide 0.5% and phenylephrine 10% at 20-minute intervals for one hour prior to surgery. Peribulbar anesthesia is then applied. The main incision was made in the clear cornea at the 12 o'clock with a 2.5 mm blade keratome. A 15-degree knife is used to make a paracentesis and epinephrine hydrochloride 1:4000 was injected intracamerally (Figure 1).

For the first two eyes sodium hyaluronate 1.4% (Healon®GV) and for the third and fourth eyes sodium hyaluronate 2.3% (Healon® 5) was injected over the iris peripherally to push the free iris strands posteriorly. The remaining space in the anterior chamber is filled with methyl cellulose 2% (Coatel® Bausch and Lomb). In eyes number 2, 3, and 4 following stab keratotomies at 1:30, 5, 7, 10:30 o'clock positions with 15-degree knife, 4 flexible nylon iris hooks are inserted to capture the disintegrating iris stroma. Gentle traction on the hooks is applied to dilate the pupil and

flatten the fibrillary strands floating in the anterior chamber in all quadrants.

A relatively small anterior continuous curvilinear capsulorhexis (4.0-4.5 mm) is performed. After hydrodissection, the nucleus is removed by the horizontal chop technique using ARC laser unit. To minimize turbulence in anterior chambers and washout of the cohesive OVD, low vacuum rates (up to 175 to 200 mmHg) and power of 30 percent are used. After manual aspiration of residual cortical material, three-piece acrylic intraocular lens (IOL) (Acry-Sof® MA60AT, Alcon) is implanted in the bag. The residual OVDs are aspirated and the iris hooks removed. Finally, acetylcholine is used to constrict the pupil and the eye is patched.

## Case reports

### Case 1

A 78-year-old woman was referred to our clinic with a best corrected visual acuity (BCVA) of hand motion in the right eye and  $20/200$  in the left eye. She had undergone trabeculectomy 3 years earlier for secondary glaucoma in the right eye. The IOP was 12 mmHg in both eyes. More than 85% of the iris surface in the right eye showed stromal splitting sparing the supratemporal area, whereas left eye had a 60% affected area sparing superior segment. There was some degree of posterior synechiae in right eye. The pupil could not be dilated more than 3 mm in the right and 4 mm in the left. There was a mature cataract in the right eye and moderate to severe nuclear sclerotic cataract in the left.

### Eye 1

The less affected eye was scheduled for surgery first. Pupil diameter of 5 mm was achieved after injecting diluted epinephrine, so we didn't insert iris hook. As mentioned Healon® GV was used; a progressive loss of the protective effect was observed during surgery i.e. iris billowing and prolapse needed multiple reinjection of the OVD. Postoperative BCVA improved to  $20/30$  but some iris atrophy could be seen in superior and inferior iris segments.

### Eye 2

One month later phacoemulsification was performed in the right eye (Figure 2). Despite

full pharmacological measures and synechiae release, pupil diameter was not more than 4 mm. Iris hooks were inserted. Combination of Healon®GV and Coatel® was used for the procedure. Although the iridoschisis was extensive, phacoemulsification was carried out uneventfully and the iris fibrils remained rather stable during the procedure and reinjection of OVD was done only once. Postoperative BCVA was  $20/40$ ; no additional iris atrophy was observed.

#### Case 2

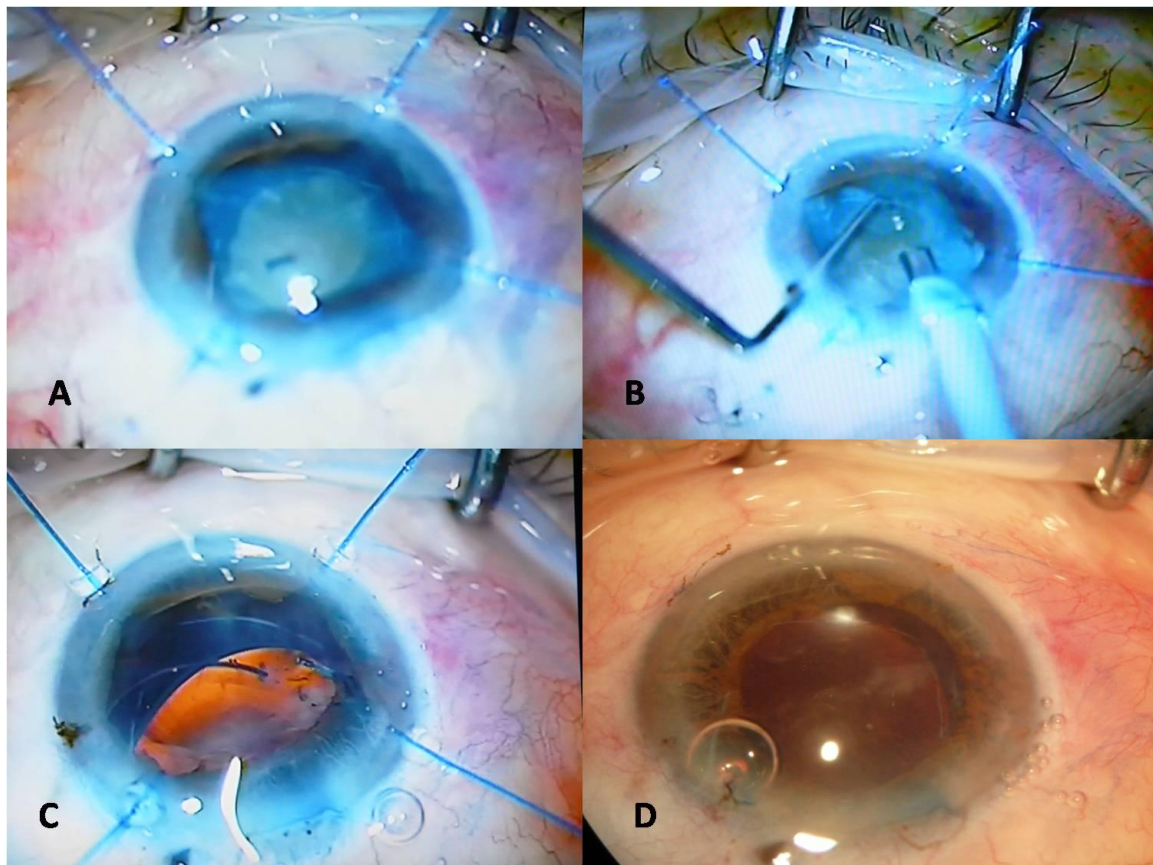
The patient was a 69-year-old man with a preoperative bilateral BCVA of  $20/200$ .

Both eyes had extensive splitting of the anterior layer of the iris and fibrillar degeneration of more than 90% of iris surface area. IOPs were 14 and 16 mmHg in the right and left eyes, respectively. Preoperatively, a

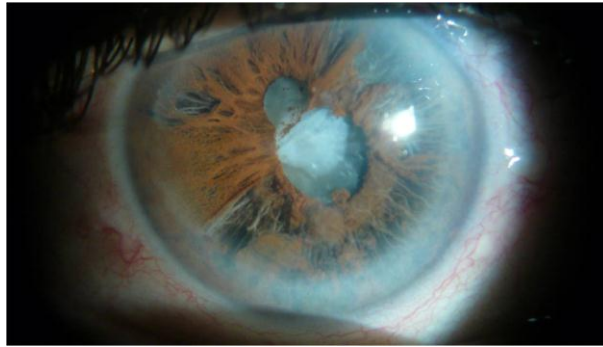
pupil diameter of only 4 mm was achieved. A nuclear sclerotic cataract of grade 3+ was present bilaterally.

#### Eye 3 and 4

The eyes were operated consecutively, one month apart. Following the injection of intracameral epinephrine a pupil dilation of 5 mm was achieved, however iris hooks were also inserted to stabilize the iris. Healon® 5 and Coatel® were used instead. There was no additional need to OVD reinjection as the iris fibrils remained immobile during the procedure, and despite the severity of iridoschisis, there was no iris attachment to phaco tip, iris billowing, or iris prolapse during phacoemulsification. On day 7 post-op, BCVA was  $20/30$  and  $20/25$  in the right and left eyes, respectively.



**Figure 1.** Cataract surgery in an iridoschisis eye. A: 4 flexible nylon iris hooks are inserted and used to capture the disintegrating iris stroma. A relatively small anterior continuous curvilinear capsulorhexis (between 4.0 mm and 4.5 mm) is performed. B: After hydrodissection, the nucleus is removed by the chop technique using ARC laser unit. Low vacuum rates (up to 175 to 200 mmHg) and power of 30 percent were used to reduce turbulence in anterior chambers and wash out of cohesive OVDs. C: After manual aspiration of residual cortical material, three-piece acrylic intraocular lens (Acry-Sof® MA60AT, Alcon) was implanted in the bag. D: Appearance of eye at the end of surgery



**Figure 2.** One of the eyes with iridoschisis in which many of the stromal fibers go through a degenerative process in which they detach and free float in the anterior chamber, creating a shredded wheat appearance

## Discussion

Our experience revealed that through modifications in the preoperative and intraoperative techniques, phacoemulsification can be performed in iridoschisis eyes uneventfully with good visual outcome.

Intraoperative floppy iris syndrome (IFIS) is an identified condition encountered during phacoemulsification in patients who are using  $\alpha$ 1-antagonist agents such as Tamsulosin (Flomax) and similar agents. Chang proposed basing the clinical definition of IFIS on a triad of intraoperative characteristics: fluttering and billowing of the flaccid iris stroma caused by ordinary intraocular fluid currents, a propensity for iris prolapse to the phaco and/or side-port incisions, and progressive constriction of the pupil during surgery.

Our observation substantiates the impression that diffuse iridoschisis has many characteristics in common with IFIS.<sup>8</sup> In diffuse iridoschisis specially in severe cases in addition to mobile, friable and disorganized iris, billowing of the flaccid iris stroma may occur; there might be poor preoperative pupil dilation, intraoperative constriction, and tendency of iris prolapse.

Safe surgical field for phacoemulsification comprises a relatively exposed globe, a clear cornea, a relatively deep anterior chamber, a well dilated pupil, a tight and retroplaced iris, tight zonules, and enough vitreous body support. Of the listed features, tight and retroplaced iris were less recognized as independent factors and considered as associated characteristics with pupillary

dilation. IFIS, in fact, is a syndrome of lack of these features.

A variety of techniques and procedures to ensure safe surgery in patients with IFIS have been proposed namely, adoption of low flow parameters on phacoemulsification, use of super-cohesive OVDs such as sodium hyaluronate 2.3% (Healon® 5), avoidance of iris stretching, insertion of iris hooks, preoperative administration of topical atropine, and intracameral epinephrine.<sup>8-13</sup> Similarity of iris behavior in iridoschisis with IFIS prompt us to apply these techniques in our cases.

Like Rosenberg,<sup>6</sup> we used more than one OVD during surgery. But as the diseased area was extensive in our cases, we first applied cohesive OVD all over the iris periphery. Remaining space was then filled with a dispersive substance so as to prevent highly viscous OVD from being dislodged from the diseased iris surface by the BSS flow.

We used 2 combinations of OVDs, namely Healon® GV and Coatel®; and Healon® 5 and Coatel®. Similar to Rosenberg's report<sup>6</sup> the second combination was proved more resistant to the BSS flow as it kept the iris fibrils steady during the procedure for eyes 3 and 4. Chang also suggested that in patients with IFIS usage of viscoadaptive agent Healon® 5, when properly positioned over the iris, may help in mechanically expansion of the pupil and block the iris from prolapsing out through the incisions. We used low aspiration flow and vacuum settings to avoid premature

removal of the cohesive OVDs from anterior chamber.

We used iris hooks for pupil dilation and to keep the fibrillary materials away from surgical fields. Mechanical stretching or partial-thickness iris sphincter cuts are not recommended in IFIS. Iris hooks may similarly be placed in affected area in iridoschisis to trap friable wisps of iris stroma when only a small part of iris is affected.<sup>2</sup> Chang recommended that iris hooks be positioned in the diamond pattern in IFIS,<sup>14</sup> but we did not. We chose the least affected area (usually superior) as the main incision site, so we applied the hooks in standard configuration in diffuse iridoschisis. Although the first eye had less severely affected area, it was prone to iris prolapse and iris damaged more during surgery. One reason might be that we didn't apply iris hooks in this case.

As in IFIS, no simple solution to reduce challenge of extensive iridoschisis is available.

### Conclusion

A dilated tight iris is necessary for an uneventful surgery in these cases. Adoption of low flow parameters on phacoemulsification, use of super-cohesive OVDs, avoidance of iris stretching, insertion of iris hooks, preoperative administration of topical atropine, and intracameral epinephrine can provide constantly safe results in phacoemulsification in these eyes.

### Ethic Approval

The review board and ethical committee of Eye Research Center of Tehran University of Medical Sciences approved the study.

### References

1. Danias J, Aslanides IM, Eichenbaum JW, et al. Iridoschisis: high frequency ultrasound imaging. Evidence for a genetic defect? *Br J Ophthalmol* 1996;80(12):1063-7.
2. Smith GT, Liu CS. Flexible iris hooks for phacoemulsification in patients with iridoschisis. *J Cataract Refract Surg* 2000;26(9):1277-80.
3. Ghanem VC, Ghanem EA, Ghanem RC. Iridectomy of the anterior iris stroma using the vitreocutter during phacoemulsification in patients with iridoschisis. *J Cataract Refract Surg* 2003;29(11):2057-9.
4. Eiferman RA, Law M, Lane L. Iridoschisis and keratoconus. *Cornea* 1994;13(1):78-9.
5. Salmon JF, Murray AD. The association of iridoschisis and primary angle-closure glaucoma. *Eye (Lond)* 1992;6(Pt 3):267-72.
6. Rozenberg I, Seabra FP. Avoiding iris trauma from phacoemulsification in eyes with iridoschisis. *J Cataract Refract Surg* 2004;30(4):741-5.
7. Auffarth GU, Reuland AJ, Heger T, Völcker HE. Cataract surgery in eyes with iridoschisis using the Perfect Pupil iris extension system. *Cataract Refract Surg* 2005;31(10):1877-80.
8. Chang DF, Campbell JR. Intraoperative floppy iris syndrome associated with tamsulosin. *J Cataract Refract Surg* 2005;31(4):664-73.
9. Mamalis N. Intraoperative floppy-iris syndrome. *J Cataract Refract Surg* 2006;32:1589-90.
10. Masket S, Belani S. Combined preoperative topical atropine sulfate 1% and intracameral nonpreserved epinephrine hydrochloride 1:4000 [corrected] for management of intraoperative floppy-iris syndrome. *J Cataract Refract Surg* 2007;33(4):580-2.
11. Manvikar S, Allen D. Cataract surgery management in patients taking tamsulosin staged approach. *J Cataract Refract Surg* 2006;32(10):1611-4.
12. Shugar JK. Use of epinephrine for IFIS prophylaxis. *J Cataract Refract Surg* 2006;32(7):1074-5.
13. Bendel RE, Phillips MB. Preoperative use of atropine to prevent intraoperative floppy-iris syndrome in patients taking tamsulosin. *J Cataract Refract Surg* 2006;32(10):1603-5.
14. Oetting TA, Omphroy LC. Modified technique using flexible iris retractors in clear corneal surgery. *J Cataract Refract Surg* 2002;28(4):596-8.