

End-Gaze Leukocoria as the First Manifestation of Retinoblastoma

Mehrdad Mohammadpour, MD¹ • Fariba Ghassemi, MD¹ • Roja Toosi² • Batoul Naghavi²

Abstract

Purpose: To report two cases of retinoblastomas detected by “white pupillary reflex” end-gaze leukocoria via flash photographs reported by parents

Case reports: Retinoblastoma, a malignant ocular tumor, can be manifested by leukocoria. Herein, we report two cases, a 4-year-old boy and a 5-year-old girl, presented with the parents' chief complaint of end-gaze leukocoria. In further evaluations retinoblastoma was detected and treated.

Conclusion: Leukocoria is an alarming sign specially in pediatrics age group which should be detected and treated promptly. It may be detected solely in end-gaze by the child's parents or in photographs in the early stages of retinoblastoma.

Keywords: Leukocoria, Retinoblastoma

Iranian Journal of Ophthalmology 2012;24(4):67-69 © 2012 by the Iranian Society of Ophthalmology

Introduction

Retinal diseases are a leading cause of visual impairment in children.¹ Leukocoria means “white pupillary reflex” can be discovered by direct ophthalmoscopy on examination or seen in flash home photographs.² The common causes of leukocoria in children include: retinoblastoma, retinopathy of prematurity, cataract, chorioretinal or optic disc coloboma, uveitis, vitreous hemorrhage, coats' disease, etc.³

Retinoblastoma is one of the most important causes of leukocoria.^{4,5} Delay in detection of retinoblastoma leads to increase in the rate of morbidity and mortality. We report two patients with end-gaze leukocoria detected by their mothers.

Case reports

Case 1

A 4-year-old boy presented to ophthalmology center with the chief complaint of end-gaze leukocoria. His mother had concern about white reflex in the right eye when looking to left side (Figure 1).

On the examination, visual acuity (VA) was normal. Strabismus was not detected. In dilated indirect ophthalmoscopy, a white elevated retinal mass was detected in nasal side of the retina in the right eye (Figure 2). Further retinal consultation and examination under anesthesia suggested the diagnosis of retinoblastoma.

1. Assistant Professor of Ophthalmology, Eye Research Center, Farabi Eye Hospital, Tehran University of Medical Sciences, Tehran, Iran

2. Medical Student, Eye Research Center, Farabi Eye Hospital, Tehran University of Medical Sciences, Tehran, Iran

Received: September 16, 2012

Accepted: December 22, 2012

Correspondence to: Mehrdad Mohammadpour, MD

Assistant Professor of Ophthalmology, Eye Research Center, Farabi Eye Hospital, Tehran University of Medical Sciences, Tehran, Iran, Email: mahammadpour@yahoo.com

The article has not been presented in a meeting.

The authors did not receive any financial support from any public or private sources.

The authors have no financial or proprietary interest in a product, method, or material described herein.

The patient was treated by chemotherapy and trans-pupillary thermotherapy (TTT) and fortunately the tumor regressed substantially

Case 2

A 5-year-old girl presented to ophthalmology center that her mother complained of her left end-gaze leukocoria of the right eye. Past

medical and surgical history was negative (Figure 2).

On the examination VA of the right eye was $\frac{9}{10}$ and left eye was $\frac{7}{10}$. Strabismus was not detected. The retinoblastoma was confirmed by retinal examination (Figure 2).

She was treated by systemic chemotherapy with adjuvant cryotherapy and TTT. The tumor favorably responded.

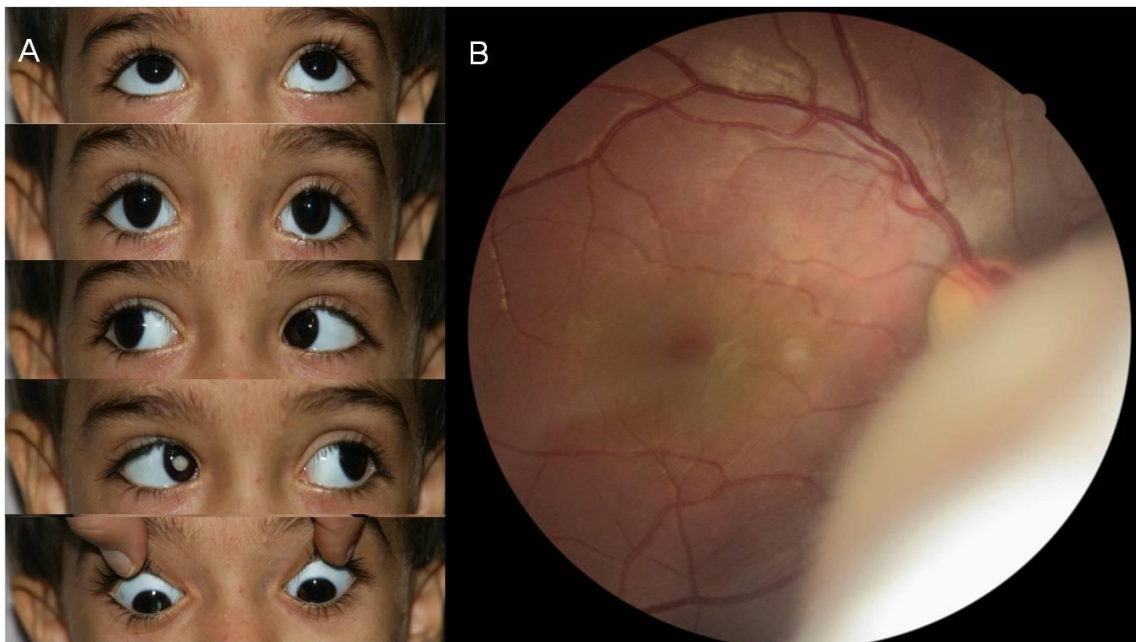


Figure 1. Leukocoria in left end-gaze due to a retinal mass in the nasal side of the right eye of case 1

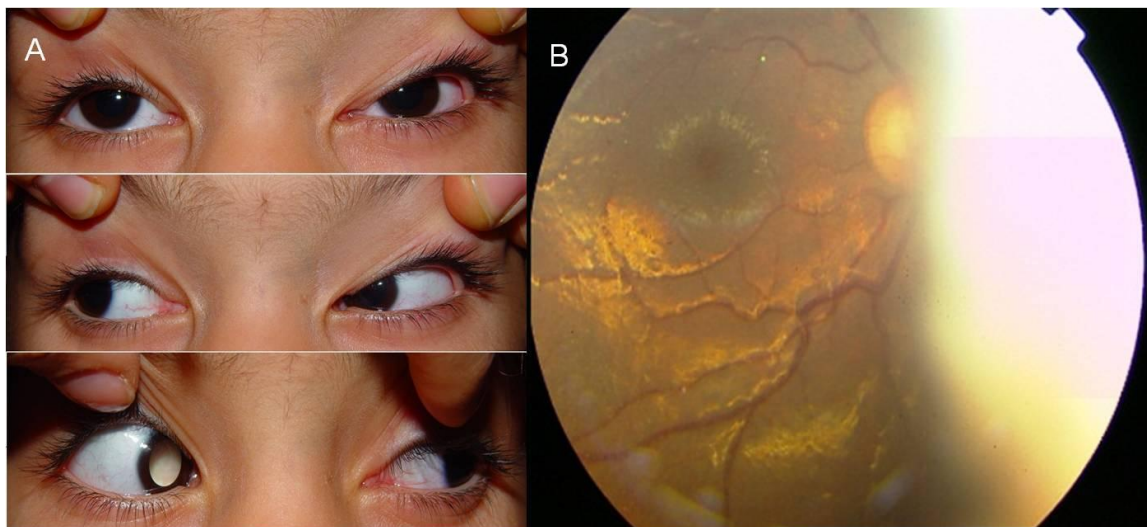


Figure 2. Leukocoria in left end-gaze due to a retinal mass in the nasal side of the right eye of case 2

Discussion

Leukocoria is an alarming sign for various ocular pathologies specially in pediatrics age group. Some of the causes of leukocoria such as congenital cataract may lead to severe amblyopia if not treated, specially when it is unilateral. Other causes such as retinoblastoma are life threatening.

Retinoblastoma is the most common pediatric intraocular tumor. Recent studies show increase in the incidence of retinoblastoma.⁶ Delay in diagnosis leads to increase in mortality and morbidity rate.⁶ Leukocoria may be revealed in off-axis flash photographs, taking by the parents. Other manifestations of retinoblastoma include: strabismus, poor vision, nystagmus, orbital inflammation, excess watering.⁶ Ultrasonography, funduscopy, fluorescein angiography, MRI and CT-scan can be used to confirm the diagnosis.⁷

Treatment depends on the size of the tumor and its laterality, systemic status and metastasis of the tumor.⁸

Current methods of retinoblastoma treatment include intravenous chemoreduction, transpupillary thermotherapy, cryotherapy, plaque radiotherapy, external beam radiotherapy, enucleation, orbital exenteration, and systemic chemotherapy for metastatic disease.⁶

Conclusion

Leukocoria is an alarming sign specially in pediatrics age group which should be detected and treated promptly. It may be detected solely in end-gaze by the child's parents or in photographs in the early stages of retinoblastoma.

References

1. Mirdehghan SA, Dehghan H, Mohammadpour M, et al. Causes of severe visual impairment and blindness in schools for visually handicapped children in Iran. *Br J Ophthalmol* 2005;89(5):612-4.
2. Marshall J, Gole GA. Unilateral Leukocoria in off axis flash photographs of normal eyes. *Am J Ophthalmol* 2003;135(5):709-11.
3. Wiler JL, Price C, Fintak DR, Shields C. Leukocoria and irregular pupil. *Am J Emerg Med* 2010;28(1):121.
4. Canzano JC, Handa JT. Utility of pupillary dilation for detecting leukocoria in patients with retinoblastoma. *Pediatrics* 1999;104(4):e44.
5. Ghassemi F, Chams H, Sabour S, et al. Retinoblastoma: a report from a referral center in Iran: 1979-2007. *Iranian Journal of Ophthalmology* 2012;24(1):31-7.
6. Parulekar MV. Retinoblastoma - current treatment and future direction. *Early Hum Dev* 2010;86(10):619-25.
7. Othman IS. Retinoblastoma major review with updates on Middle East management protocols. *Saudi Journal of Ophthalmology* 2012;26(2):16375.
8. Tuli SY, Giordano BP, Kelly M, et al. Newborn with an absent red reflex. *J Pediatr Health Care* 2013;27(1):51-5.