

Visual Outcomes of Toric Implantable Collamer Lens for Correction of Compound Myopic Astigmatism

Mohammad Ghoreishi, MD¹ • Zahra Jafarzadeh, MD² • Alireza Peyman, MD³
Azadeh Mohammadi, MD² • Mohadeseh Mohammadinia, MSc⁵

Abstract

Purpose: To assess the visual and refractive outcomes after implantation of Toric Implantable Collamer Lens (T-ICL) in compound myopic astigmatism

Methods: In this prospective study, 28 eyes with manifest refraction spherical equivalent (MRSE) errors of -10.94 ± 4.09 diopter (D) and mean cylindrical errors of -3.47 ± 1.39 D underwent T-ICL implantation. Six months after surgery, best corrected and uncorrected visual acuity (BCVA, UCVA), manifest refraction and surgical complications were assessed.

Results: The mean postoperative MRSE was -0.35 ± 0.34 D (range, -1.25 to 0.37), and the mean postoperative refractive cylinder was -0.78 ± 0.45 D (range, -1.50 to 0.00). Postoperatively, manifest spherical equivalent (SE) was within ± 1.00 D in 96% of eyes, and refractive cylinder was equal or less than 1.00 D in 79% of eyes. Fourteen eyes (50%) had uncorrected distance visual acuity (UDVA) of $20/20$ or better, and 27 eyes (96%) had UDVA of $20/40$ or better. All changes in visual and refractive data were statistically significant ($p < 0.05$).

Conclusion: T-ICL is safe and effective for correction of compound myopic astigmatism in patients who are not good candidate for corneal refractive surgery.

Keywords: Toric Implantable Collamer Lens, Myopia, Astigmatism

Iranian Journal of Ophthalmology 2013;25(2):155-162 © 2013 by the Iranian Society of Ophthalmology

Introduction

Photorefractive keratectomy (PRK) and laser in situ keratomileusis (LASIK) are the most popular refractive surgical procedures for correction of refractive errors. These two methods are limited in correction of high refractive errors because of the increased risk for corneal ectasia and postablation corneal haze.¹ Phakic intraocular lenses (IOLs) are an

alternative to LASIK and PRK for patients who are not good candidate for keratorefractive surgery.²⁻¹²

The advantages of phakic IOLs are lack of disruption of the corneal tissue, stability of correction results, rapid visual recovery and ability to correction of higher levels of myopia, hyperopia and astigmatism.

-
1. Associate Professor of Ophthalmology, Feiz Hospital, Isfahan University of Medical Sciences, Isfahan, Iran
 2. Resident in Ophthalmology, Feiz Hospital, Isfahan University of Medical Sciences, Isfahan, Iran
 3. Assistant Professor of Ophthalmology, Feiz Hospital, Isfahan University of Medical Sciences, Isfahan, Iran
 4. Ms in Optometry, Feiz Hospital, Isfahan University of Medical Sciences, Isfahan, Iran

Received: January 7, 2013

Accepted: May 9, 2013

Correspondence to: Zahra Jafarzadeh, MD

Resident in Ophthalmology, Feiz Hospital, Isfahan University of Medical Sciences, Isfahan, Iran, Email: dr.jafarzadeh88@yahoo.com

Financial Disclosure: No author has a financial or proprietary interest in any material or method mentioned.

Phakic IOLs have different designs. The two popular types of phakic IOLs are iris-fixated lenses and implantable contact lenses (ICLs) which are placed in posterior chamber over a clear lens. Recently, toric types of iris-fixated phakic IOLs and Toric Implantable Collamer lenses (T-ICLs) are available for correction of astigmatism.

The first T-ICL was implanted in North America by Gimbel and Ziemia.¹³ T-ICL have been shown to be successful for the correction of high myopia astigmatism.¹⁴⁻²⁰ Visian ICL manufactured by STAAR Surgical is one of the best phakic IOLs available for the treatment of astigmatism.¹² It is made of a copolymer of HEMA (99%) and porcine collagen (1%) with design of a footplate and a central convex/concave optical zone and a cylinder on specific axis.²¹ ICL is FDA approved for correction of -3.00 to -23.00 diopter (D) of myopia and less than -6.00 astigmatism.

Methods

This prospective study included 28 eyes which underwent toric ICL implantation surgery by one experienced surgeon (GH. M). Inclusion criteria included patients with moderate to high myopic with astigmatism who was not good candidate for keratorefractive surgery due to high degree of correct and/or inadequate corneal thickness. Patients with history of diabetes, autoimmune or collagen vascular disease and intraocular disease such as: glaucoma, cataract, uveitis, iris neovascularization, anterior chamber depth less than 3.00 mm, endothelial cell count under 2,500 cells/mm, scotopic pupil size more than 6 mm and previous eye surgery were excluded.

All patients signed the informed consent after understanding all benefits and possible complications of the procedure.

Preoperative assessment included: uncorrected distance visual acuity (UDVA), corrected distance visual acuity (CDVA), manifest and cyclo refraction, slit-lamp evaluation of the anterior segment, applanation tonometry, fundus evaluation, corneal topography (pentacam, Oculus optikgerate GmbH, Wetzlar, Germany), specular microscopy (Topcon Corp, Tokyo, Japan).

Horizontal 'white-to-white' distance and anterior chamber depth were measured with the Orbscan topographer (version 3.14, Bausch & Lomb). T-ICL lenses power and sizing calculations were performed by the manufacturer (STAAR Surgical, Monrovia, CA, USA) using the 'white-to-white', anterior chamber depth, manifest refraction and keratometry.²²

Surgical procedures

Before surgery all eyes was fully dilated, using tropicamide 1% eye drop, for case of ICL implantation into the posterior chamber. For compensation of potential cyclotorsion in supine position, vertical meridian of the cornea was marked with the aid of slit beam of the slit-lamp while patients gaze was maintained in primary position. Under topical anesthesia (tetracain 1%, every five minutes for two doses) the eye was prepared with povidone iodine 5%. Mendez guage and toric marker was used to mark alignment position of the lens. A 2.8 mm clear cornea incision was made at horizontal meridian and one or two 0.8 mm side-port incisions were made in 8 degree from main incision. The lens was inserted by means of STAAR Injector (STAAR Surgical) under protection of Ophthalmic Viscosurgical Device (OVD). The lens was moved into posterior chamber and aligned to desired position which was determined according to the preoperative calculations, based on T-ICL calculator (STAAR Surgical). After verification of T-ICL alignment and positioning, OVD was washed out and Miochole was injected into anterior chamber. After adequate miosis, small peripheral iridectomy was made via a superior side-port incision.

In post operation, topical ciprofloxacin and bethamethasone eye drops were administered eight times daily for first week and four times daily for second week and reduced steadily for third week.

Postoperative follow-up evaluations were done at one day, one week, three months and six months after surgery. The outcome parameters included: UDVA, CDVA, slit-lamp examination, manifest refraction and applanation tonometry. At six month postoperation specular microscopy was repeated.

Statistical analysis

Statistical analysis was performed with SPSS version 18 (SPSS Inc, Chicago, Illinois). Preoperative and postoperative data were compared by using paired *t* test and *p* value less than 0.05 was considered statistically significant. Power vector analysis of astigmatic change (Alpin's method)²³ was used to quantify the contribution of lens rotation to the residual refractive error.

Results

This prospective study including 28 eyes of 22 patients (10 males and 18 females) with mean age of 26.60 years (range, 20 to 40) implanted with the toric ICL.

Visual outcomes, safety and efficacy

The mean logMAR UDVA improved from 1.61±0.45 preoperatively to 0.08±0.10 six months after surgery, as shown in table 1. Preoperatively only 25% of eyes had CDVA of ²⁰/₂₀ or better, but six months postoperatively 96% of eyes had UDVA of ²⁰/₄₀ or better, 50% had ²⁰/₂₀ or better, 7% had ²⁰/₁₆ or better and 4% had ²⁰/_{12.5} or better. The efficacy index (ratio of postoperative UDVA and preoperative CDVA) was 1.18±0.29. Comparison of preoperative CDVA and postoperative UDVA was showed in figure 1.

The mean logMAR CDVA improved from 0.14±0.14 to 0.02±0.06 at six months (table 1). None of the eyes lost one or more lines of CDVA compared to their preoperative level. CDVA in 21% of the eyes was unchanged, 14% gained 1 line, 36% gained 2 lines and 29% gained 3 or more lines (Figure 2). The safety index (ratio of postoperative and preoperative CDVA) was 1.36±0.46.

Refractive outcomes and predictability

At six months, the mean spherical equivalent (SE) refraction decreased from -10.94±4.09 D preoperatively to -0.35±0.34 D postoperatively. 79% of the eyes achieved a manifest SE of ±0.50D and 96% achieved ±1.00 D six months after surgery (Figure 3).

Mean preoperative refractive cylinder decreased from -3.47±1.39D to -0.78±0.45 D at six months. All eyes had refractive cylinder errors of ≥1.00 D preoperatively. 79% of eyes achieved a refractive cylinder of ≤1.00 D and 36% had ≤0.50 D postoperatively (Figure 4). Preoperative and six months postoperative refractive outcomes are shown in table 2. All changes in refractive data were statistically significant (*p*<0.05).

Mean keratometric surgically induced astigmatism which indicates wound induced astigmatism was 0.494±0.309 D. Mean preoperative corneal keratometric cylinder was 2.592±0.930 and postoperative keratometric astigmatism was 2.622±0.991 diopters (*p*=0.563).

At six months 79% of the eyes were within ±0.5 D of the attempted correction. Comparison between attempted and achieved SE refraction showed good predictability of T-ICL implantation surgery in our study (Figure 5).

The mean preoperative endothelial cell count was 2,651.18±302.14 cells/mm² (range, 2,018 to 3,194) this was 2,583.03±276.96 cells/mm² (range, 1,928 to 3,080) at six months after surgery. The change was -0.3%. This change was not statistically significant (*p*=0.06) (Table 3).

Although, majority of patient complained of mild glare and hallos specially in scotopic condition, all of patient were satisfied with visual outcomes of surgery.

Table 1. Visual acuity pre and postoperative

	Preoperative	Postoperative
UDVA (logMAR)		
Mean±SD (range)	1.61±0.45 (2.00 to 0.52)	0.08±0.10 * (0.4 to -0.07)
CDVA (logMAR)		
Mean±SD (range)	0.14±0.14 (0.52 to 0.0)	0.02±0.06 * (0.15 to -0.07)

UDVA: Uncorrected distance visual acuity

CDVA: Corrected distance visual acuity

*: Statistically significant with *p*<0.05

Table 2. Refraction pre and postoperative

	Preoperative	Postoperative
Sphere (D)		
Mean±SD (range)	-9.23±3.98 (-16.50 to -0.25)	-0.08±0.35 * (-1.25 to 0.75)
Cylinder (D)		
Mean±SD (range)	-3.47±1.39 (-6.00 to -1.00)	-0.78±0.45 * (-1.50 to 0.00)
SE (D)		
Mean±SD (range)	-10.94±4.09 (-18.25 to -2.25)	-0.35±0.34 * (-1.25 to 0.37)

SE: Spherical equivalent
*: Statistically significant with p<0.05

Table 3. Corneal characteristics pre and postoperative

	Preoperative	Postoperative
K max, D		
Mean±SD (range)	45.43± 2.73 (38.2 to 52.3)	45.51±2.72 (38.3 to 52.2)
K min, D		
Mean±SD (range)	42.81±2.69 (36.0 to 48.8)	42.87±2.51 (36.4 to 48.3)
K average, D		
Mean±SD (range)	44.09±2.64 (37.1 to 50.2)	44.12±2.60 (37.0 to 50.1)
ECC, cell/mm		
Mean±SD (range)	2651.18±302.14 (2,018 to 3,194)	2583.03±276.96 (1,928 to 3,080)
CCT, um		
Mean±SD (range)	496.82±48.79 (410 to 598)	494.78±51.13 (403 to 602)

ECC: Endothelium cell count
CCT: Central corneal thickness
*: Statistically significant with p<0.05

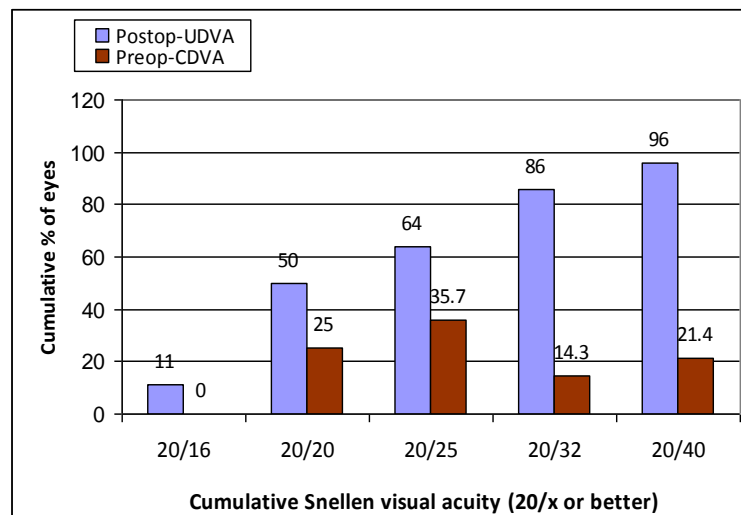


Figure 1. Uncorrected distance visual acuity and efficacy

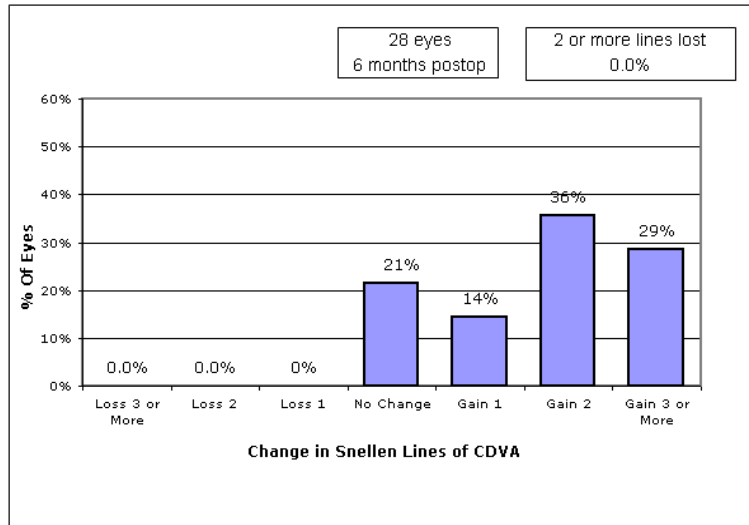


Figure 2. Change in lines, corrected distance visual acuity

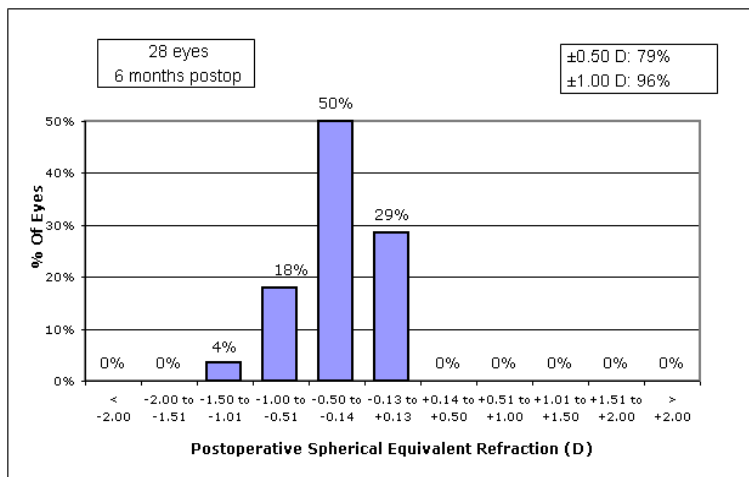


Figure 3. Postoperative spherical equivalent predictability

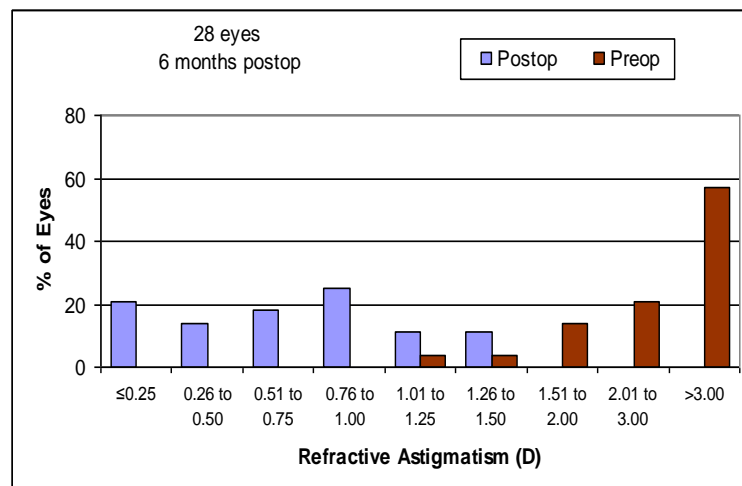


Figure 4. Preoperative postoperative refractive astigmatism

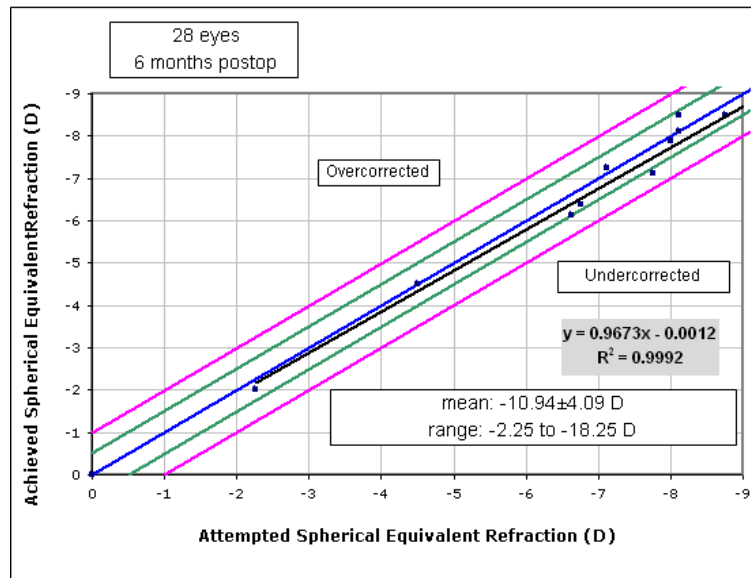


Figure 5. Attempted versus achieved spherical equivalent refraction. This scatterplot is included a linear regression analysis between attempted and achieved spherical equivalent refraction that provides a visual indication tendency towards over or undercorrection.

Discussion

We analyzed 28 eyes implanted with T-ICL. In our study 96% of eyes achieved postoperative SE within ± 1.00 D and 79% achieved within ± 0.5 D. Six months postoperation refractive and visual outcomes were excellent and patients were satisfied. Other previous studies also, showed the efficacy of T-ICL.

United States Food and Drug Administration (FDA) clinical trial of the toric ICL demonstrated that T-ICL implantation was an efficacious procedure for reducing manifest astigmatism.¹⁵

Several other studies have been published on efficacy of T-ICL implantation. For example, Chang and Lau¹⁹ evaluated refractive outcomes of 44 eyes at six months after T-ICL implantation. They reported reducing of the mean refractive cylinder from 2.64 D (± 0.91) preoperatively to 0.59 D (± 0.51) postoperatively. Their results were similar to FDA toric ICL study outcomes.

In other study, published by Kamiya et al¹⁵ the mean preoperative SE of -10.37 ± 2.78 D (rang, -4.00 to -17.25 D) was reduced to -0.13 ± 0.33 D and the mean preoperative refractive cylinder of -2.15 ± 0.79 D (rang, -0.75 to -4.00 D) was reduced to -0.41 ± 0.36 D.

A study by Schallhorn et al³ showed better outcomes of T-ICL implantation compared

with conventional PRK for moderate to high myopic astigmatism. Elies and Alonso et al²⁴ analyzed 63 eyes implanted with T-ICL with mean preoperative SE of -10.71 ± 3.55 D. postoperatively, 93.6% of eyes had SE within ± 1.00 D and 82% were within ± 0.5 D of emmetropia.

In our case series, two eyes of two patients developed lens rotation after one week postoperation. In both of them realignment of the lens, was performed successfully and no exchange of lenses were needed. The cause of rotation was presumed to be under-sizing, but the vault was not too low to need T-ICL exchange. Under-sized T-ICL length for the eye, can lead to misalignment.²⁵ Many studies investigated possible risk factors for postoperation T-ICL misalignment. Park et al²⁶ found significant correlation between spherical power and angle of T-ICL rotation. In Xun-Lun Sheng²⁷ study vault value and ICL footplate-position were possible risk factor for T-ICL rotation. In that study patient with the footplate in the ciliary sulcus showed lower vault value than with the footplate below the ciliary sulcus ($p=0.01$) in that study also, angle of T-ICL rotation had significant correlation with the post operation vaulting. Because of low incidence of T-ICL

misalignment in most studies, greater sample size with long-term follow-up studies is needed to detect major risk factors of this problem.

No significant complication was observed in six months interval. Glaucoma, pigment dispersion, retinal detachment, pupillary block and anterior subcapsular cataract did not occur in our study. The FDA trial²⁸ reported 6-7% anterior subcapsular cataract more than

seven years after ICL implantation. This indicated that long-term follow-up requires determining anterior subcapsular cataract and other significant complications.

Conclusion

The results of this study show that T-ICL implantation is an effective and safe procedure or moderate to high myopia and astigmatism.

References

1. Alfonso JF, Baamonde B, Madrid-Costa D, Fernandes P, Jorge J, Montés-Micó R. Collagen copolymer toric posterior chamber phakic intraocular lenses to correct high myopic astigmatism. *J Cataract Refract Surg* 2010;36(8):1349-57.
2. Lovisolo CF, Reinstejn DZ. Phakic intraocular lenses. *Surv Ophthalmol* 2005;50(6):549-87.
3. Schallhorn S, Tanzer D, Sanders DR, Sanders ML. Randomized prospective comparison of visian toric implantable collamer lens and conventional photorefractive keratectomy for moderate to high myopic astigmatism. *J Refract Surg* 2007;23(9):853-67.
4. Dick HB, Alió J, Bianchetti M, Budo C, Christiaans BJ, El-Danasoury MA, et al. Toric phakic intraocular lens: European multicenter study. *Ophthalmology* 2003;110(1):150-62.
5. Marinho A, Neves MC, Pinto MC, Vaz F. Posterior chamber silicone phakic intraocular lens. *J Refract Surg* 1997;13(3):219-22.
6. Tehrani M, Dick HB. Iris-fixated toric phakic intraocular lens: Three-year follow-up. *J Cataract Refract Surg* 2006;32(8):1301-6.
7. Güell JL, Vázquez M, Malecaze F, Manero F, Gris O, Velasco F, et al. Artisan toric phakic intraocular lens for the correction of high astigmatism. *Am J Ophthalmol* 2003;136(3):442-7.
8. Bartels MC, Santana NT, Budo C, van Rij G, Mulder PG, Luyten GP. Toric phakic intraocular lens for the correction of hyperopia and astigmatism. *J Cataract Refract Surg* 2006;32(2):243-9.
9. Bartels MC, Saxena R, van den Berg TJ, van Rij G, Mulder PG, Luyten GP. The influence of incision-induced astigmatism and axial lens position on the correction of myopic astigmatism with the Artisan toric phakic intraocular lens. *Ophthalmology* 2006;113(7):1110-7.
10. Sanders DR, Sarver EJ. Standardized analyses of correction of astigmatism with the visian toric phakic implantable collamer lens. *J Refract Surg* 2007;23(7):649-60.
11. Alfonso JF, Fernández-Vega L, Lisa C, Fernandes P, González-Méijome JM, Montés-Micó R. Collagen copolymer toric posterior chamber phakic intraocular lens in eyes with keratoconus. *J Cataract Refract Surg* 2010;36(6):906-16.
12. Alfonso JF, Fernández-Vega L, Fernandes P, González-Méijome JM, Montés-Micó R. Collagen copolymer toric posterior chamber phakic intraocular lens for myopic astigmatism: one-year follow-up. *J Cataract Refract Surg* 2010;36(4):568-76.
13. Gimbel HV, Ziémba SA. Management of myopic astigmatism with phakic intraocular lens implantation. *J Cataract Refract Surg* 2002;28(5):883-6.
14. Sanders DR, Schneider D, Martin R, Brown D, Dulaney D, Vukich J, et al. Toric Implantable Collamer Lens for moderate to high myopic astigmatism. *Ophthalmology* 2007;114(1):54-61.
15. Kamiya K, Shimizu K, Ando W, Asato Y, Fujisawa T. Phakic Toric Implantable Collamer Lens implantation for the correction of high myopic astigmatism in eyes with keratoconus. *J Refract Surg* 2008;24(8):840-2.
16. Mertens EL, Sanders DR, Vitale PN. Custom-designed toric phakic intraocular lenses to correct high corneal astigmatism. *J Refract Surg* 2008;24(5):501-6.
17. Alfonso JF, Palacios A, Montés-Micó R. Myopic phakic STAAR collamer posterior chamber intraocular lenses for keratoconus. *J Refract Surg* 2008;24(9):867-74.

18. Chang J, Lau S. Toric Implantable Collamer Lens for high myopic astigmatic Asian eyes. *Ophthalmology* 2009;116(12):2340-7.
19. Kamiya K, Shimizu K, Aizava D, Igarashi A, Komatsu M, Nakamura A. One-year follow-up of posterior chamber toric phakic intraocular lens implantation for moderate to high myopic astigmatism. *Ophthalmology* 2010;117(12):2287-94.
20. Bhikoo R, Rayner S, Gray T. Toric implantable collamer lens for patients with moderate to severe myopic astigmatism: 12-month follow-up. *Clin Experiment Ophthalmol* 2010;38(5):467-74.
21. Allarakhia L, Knoll RL, Lindstrom RL. Soft intraocular lens. *J Cataract Refract Surg* 1987;13(6):607-20.
22. Sarver EJ, Sanders DR. Astigmatic power calculations for intraocular lenses in the phakic and aphakic eye. *J Refract Surg* 2004;20(5):472-7.
23. Alpíns N. Astigmatism analysis by the Alpíns method. *J Cataract Refract Surg* 2001;27(1):31-49.
24. Elies D, Alonso T, Puiq J, Gris O, Güell JL, Coret A. Visian toric implantable collamer lens for correction of compound myopic astigmatism. *J Refract Surg* 2010;26(4):251-8.
25. Jiménez-Alfaro I, Benítez del Castillo JM, García-Feijóo J, Gil de Bernabé JG, Serrano La Iglesia JM. Safety of posterior chamber phakic intraocular lenses for the correction of high myopia: anterior segment changes after posterior chamber phakic intraocular lens implantation. *Ophthalmology* 2001;108(1):90-99.
26. Park SC, Kwun YK, Chung ES, Ahn K, Chung TY. Postoperative astigmatism and axis stability after implantation of the STAAR toric Implantable Collamer Lens. *J Refract Surg* 2009;25(5):403-9.
27. Sheng XL, Rong WN, Jia Q, Liu YN, Zhuang WJ, Gu Q, et al. Outcomes and possible risk factors associated with axis alignment and rotational stability after implantation of the Toric implantable collamer lens for high myopic astigmatism. *Int J Ophthalmol* 2010;5(4):459-65.
28. Sanders DR. Anterior subcapsular opacities and cataracts 5 years after surgery in the visian implantable collamer lens FDA trial. *J Refract Surg* 2008;24(6):566-70.