

Effectiveness of Topical Cyclosporin A in A Patient with Cogan Syndrome: A Case Report and Review of the Literature

Elif Betul Turkoglu, MD¹ • Erkan Celik, MD² • Semra Acer, MD²
Hanife Celik, MD³ • Gursoy Alagoz, MD²

Abstract

Purpose: To present a case of typical Cogan syndrome (CS) and the efficacy of topical cyclosporine A in the treatment

Case report: A 38-year-old woman with history of dizziness, loss of bilateral hearing and tinnitus in both ears who developed bilateral keratitis and on biomicroscopic examination, subepithelial stromal infiltration, corneal vascularization was observed in both eyes. Anterior chamber and posterior segment were not explorable. Ultrasonography showed vitreous opacities, but the retina was on. Topical cyclosporine A was used which successfully resolved the symptoms. However, the ocular signs recurred during seven years and the same treatment was applied successfully.

Conclusion: Topical cyclosporin A can be effective in treating CS.

Keywords: Cogan Syndrome, Cyclosporin A, Keratitis, Dizziness, Tinnitus, Hearing Loss

Iranian Journal of Ophthalmology 2013;25(2):171-175 © 2013 by the Iranian Society of Ophthalmology

Introduction

Cogan syndrome (CS) is a rare autoimmune disease that was first described by David Cogan in 1945.¹ Most commonly it occurs in young persons regardless of gender. It is characterized by recurrent ocular inflammation, nonsyphilitic interstitial keratitis and Meniere-like vestibuloauditory symptoms and hearing loss or insufficiency.

CS is classified into typical or atypical forms. The typical form presents with initial bilateral peripheral subepithelial keratitis or interstitial keratitis with perilimbal infiltration irregular granular with late vascularization. In the atypical form, different ocular

manifestations include ptosis, chronic or recurrent conjunctivitis, episcleritis, uveitis, glaucoma, retinitis, retinal vasculitis, choroiditis, xerophthalmia and optic disc edema are observed. While duration between the findings of ocular and audiovestibular is less than two years in the typical form, it is more than two years in the atypical forms.

Systemic findings can be seen at a rate of up to 90% in atypical forms but are rare in typical form of the disease. Urinary, cardiac and gastrointestinal system vasculitis were reported in 30% of the patients.

1. Department of Ophthalmology, Akdeniz University, Antalya, Turkey

2. Department of Ophthalmology, Sakarya University Research and Training Hospital, Sakarya, Turkey

3. Department of Physical Therapy and Rehabilitation, Sakarya University Research and Training Hospital, Sakarya, Turkey

Received: April 28, 2013

Accepted: July 22, 2013

Correspondence to: Elif Betul Turkoglu, MD

Department of Ophthalmology, Akdeniz University, Ankara, Turkey, Email: drelifbetul@yahoo.com

Pagnini et al identified aortic and mitral valve insufficiency in 17.4% of 23 patients diagnosed with CS in children. Aortitis were present in 10% of patients with atypical CS. Coronary ostial stenosis, pericarditis, myocarditis, arrhythmia, iliac and renal vasculitis are among the other cardiovascular pathologies.

Patients generally present with redness, photophobia and pain in both eyes. Headache, fever, weight loss, arthralgia, myalgia, stomach ache, skin rashes, tinnitus, vertigo, nausea, vomiting, hearing insufficiency are other symptoms that might accompany the disease. There is no specific diagnostic method, and diagnosis bases are on the clinical findings.²

In this presentation, we discuss a case with typical CS and the efficiency of cyclosporine A in the treatment.

Case report

A 38-year-old woman with a history of sudden dizziness, loss of balance, hearing loss and tinnitus in both ears underwent first examination in 2003. Meniere disease was diagnosed and treated with an anti-emetic and betahistine. One month later, she complained of bilateral ocular redness and blurred vision that was diagnosed by an ophthalmologist as bilateral keratitis and received topical acyclovir and steroid. She had frequent episodes of redness and pain in both eyes during seven years and applied the same treatment at each episode. During this period, hearing loss occurred in both ears. In September 2010, she was admitted to our clinic with the complaints of decreased vision, burning, redness and pain in both eyes. Best corrected visual acuity (BCVA) was $20/200$ and intraocular pressure (IOP) was 14 mmHg in each eye. On biomicroscopic examination; subepithelial stromal infiltration, corneal vascularisation and ciliary injection was observed in both eyes (Figures 1 and 2). Anterior chamber and posterior segment were not visible. Central corneal thickness was 458 μ OD and 510 μ OS, and approximately 815 μ in the areas of infiltrations. The Schirmer test with anesthesia was 5 mm OD and 4 mm OS. Tear break-up time was 6 Sec OD and 8 Sec OS. Ocular ultrasonography showed reattached retina, vitreous opacities. The patient was consulted for a systemic examination. Blood tests

demonstrated an elevation in C-reactive protein (4.16 mg/dl) and ESR (89 mm/h). Electrolytes, renal and liver function tests, rheumatologic tests (antinuclear antibody, antinuclear cytoplasmic antibodies, rheumatoid factor (RF), immunoglobulin, HLA-B27) were all negative. Syphilis and other serological tests (Hepatitis B, Hepatitis C, HIV, rubella, HSV2) were normal.

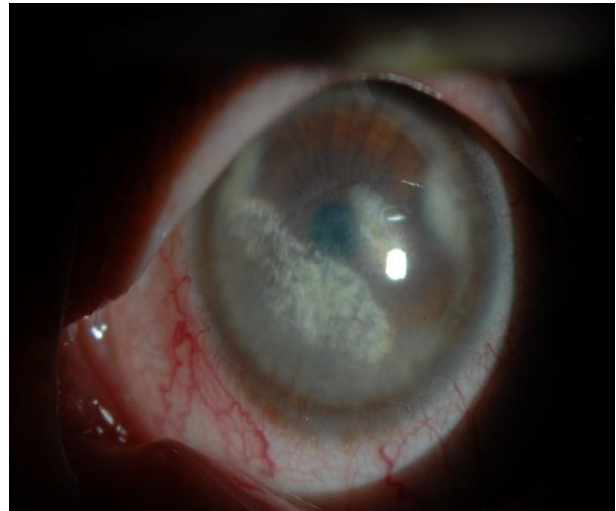


Figure 1. Subepithelial-stromal infiltration, corneal vascularisation and ciliary injection in left eye

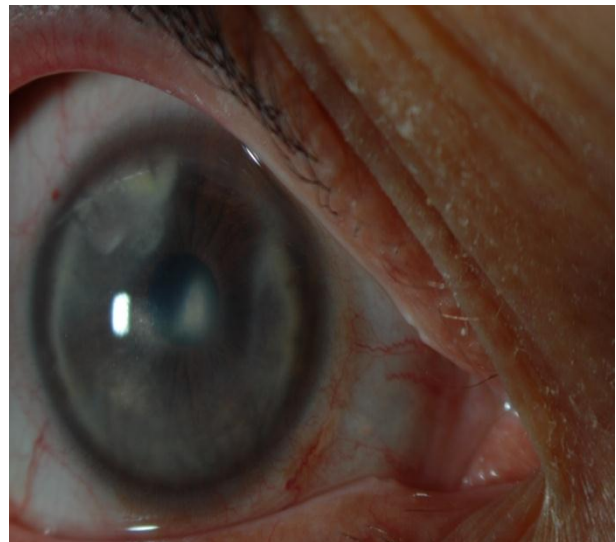


Figure 2. Subepithelial-stromal infiltration, corneal vascularisation and ciliary injection in right eye

Toxoplasmosis and herpes simplex virus (HSV) IgG were positive. On neurological examination, high-resolution brain MRI was normal. The audiometric evaluation confirmed bilateral severe sensory-neural hearing loss.

The clinical findings were associated with typical CS. The patient was treated with topical corticosteroid (Pred Forte, Allergan, USA) and ocular lubricant. After the therapy, rapid improvement of her symptoms occurred. The patient had three recurrent ocular inflammations with an interval of one to two months, and received the same therapy. On a control examination, topical 0.05% cyclosporine A (Restasis, Allergan, USA) was used in both eyes four times a day due to abnormal results of Schirmer test and tear break-up time. She continued this therapy for about two years and we realized that at this period there has been no subsequent recurrence of interstitial keratitis.

Discussion

Although the pathogenesis of CS is not exactly known, it is generally considered as an autoimmune disease because of successful remission of hearing loss after steroid administration, and the demonstration of antibodies against corneal and inner ear tissues and the association with other autoimmune disorders such as rheumatoid arthritis.² The presence of antiphospholipid antibodies and antineutrophil cytoplasmic antibodies and an association with antigens of the human leukocyte antigen system, such as A9, Bw17, Bw35, Cw4.³ Lunardi et al demonstrated antibodies against a peptide antigen (Cogan Peptide), sharing sequence homology with CD148 and connexin 26, which are expressed on corneal endothelial cells and in the inner ear.⁷ In addition, animal studies suggested that functional deficiency of T lymphocytes lead to CS.⁸

The presence of history of upper respiratory tract infection in some cases suggests that an infectious agent could develop the autoimmune response.³ Ljungstrom et al reported a patient with CS who had fourfold increased levels of IgG antibody titre to *Chlamidya pneumoniae*.⁹ Haynes et al determined serologic evidence of a recent *Chlamidya psittaci* in a patient and *Chlamidya trachomatis* in 4 of 13 patients.¹⁰ Ndiaye et al reported a case of CS with a history of vaccination for tuberculosis.¹¹ Our patient had described no history of infection in the beginning of the disease and serological tests were all negative except Toxoplasma and HSV1 IgG.

However, no paraclinical tests for CS are available and the diagnosis is made on the clinical features. Helmschen et al used high resolution magnetic resonance imaging (MRI) to differentiate between active and inactive stages of the disease. Abnormal signals were observed in vestibule, semicircular canals, vestibular nerve and cochlea in active stage, and in chronic stage, no abnormal signals were seen except narrowing in semicircular canals and cochlea.¹² Our case had a normal MRI. As the availability of positron emission tomography (PET) increases, it may play a more prominent role in the diagnosis and monitoring of a number of inflammatory conditions. In a study, a series of ten patients with immune-mediated hearing loss underwent PET scanning for the diagnosis of inner ear inflammatory activity. Of five patients with active disease, four had abnormal PET images with normalization of PET, following the treatment, in three of abnormal cases of the five patients with stable disease, PET of four out of five patients were normal, suggesting a possible role for PET in the diagnosis of CS.¹³

To be sure of the diagnosis of CS, diseases associated with ocular signs and sensorineural hearing loss, such as Wegener's granulomatosis, lupus erythematosus, Behcet's disease, polyarteritis nodosa and giant cell arteritis, should be considered. Our case had no systemic involvement or additional signs in favor of these diseases.

Losing vision is usually temporary in CS, but blindness also has been reported.¹⁴ The posterior pole involvement, late treatment, corneal opacity and vascularization can cause vision loss. In our patient, visual acuity (VA) decreased because of corneal vascularisation and opacity.

If the eye is the only site of involvement, topical steroids (Prednisolone acetate) therapy would be sufficient. Symptoms can regress with topical steroids in early period. In presence of posterior segment of the eye, the inner ear or in cases of systemic involvement, oral steroids (Prednisolone 1 mg/kg) should be initiated.^{2,3,15,16} Corticosteroids are effective in the short-term but in long-term it can not be used because of its side effects. Also, some authors have noted that hearing could be stabilized with corticosteroid treatment, but

total bilateral vestibuloauditory dysfunctions may occur and deafness could not be prevented.¹⁶ In cases of treatment failure or insufficiency, other immunosuppressive drugs such as cyclophosphamide, azathioprine, methotrexate, cyclosporine, tumor necrosis factor-alpha blockers (Infliximab, Etanercept, Rituximab) can be used.¹⁵⁻¹⁷

Cyclosporin A inhibits T-cell-mediated autoimmune response. In inflammatory diseases, many cytokines specially interleukin-2 (IL-2) are released by stimulation of T cells. These cytokines can cause tissue damage and release of more T lymphocytes. This cycle cause increasing of inflammation. Cyclosporin A provides immunomodulation with reducing the release of IL-2 by selective T-cell-mediated.¹⁸ Autoimmunity and T lymphocytes are responsible in CS pathogenesis, thus we have considered that cyclosporine A may be effective in CS. Shimura et al, reported a case with CS. Despite the multiple treatment (systemic and topical corticosteroid and antibiotic therapy), necrotizing scleritis had appeared bilaterally in this patient. They applied topical administration of 1% cyclosporine A to both eyes four times a day. After two months of this therapy, the epithelial tissue covered the necrotizing tissue and her symptom of ocular

pain was relieved and her corrected VA was improved. This is the first case showing that topical cyclosporin A is an effective treatment for severe anterior segment inflammation associated with CS.¹⁹ Also, there are some reports that show the success of topical cyclosporine A in the treatment of other autoimmune-mediated anterior segment inflammatory diseases such as Mooren's ulcer.^{19,20} We prescribed topical 0.05% cyclosporine A to our patient's both eyes four times a day for dry eye syndrome. And we observed that she did not have any CS attack in this period, although she had many attacks before the cyclosporine A treatment.

Conclusion

CS should be considered in patients with recurrent ocular inflammation and audiovestibular. In the early period, the eye symptoms regress with topical and systemic steroids. In late diagnosis and treatment, permanent blindness can develop due to posterior segment pathology or corneal scar. We observed that 0.05% Cyclosporine A is effective in the treatment of the disease and the prevention of its attacks. However, more extensive case series are needed to show the effectiveness of cyclosporine A in treatment of CS.

References

1. Cogan DG. Syndrome of nonsyphilitic interstitial keratitis and vestibuloauditory symptoms. *Arch Ophthalmol* 1945;33:144-9.
2. Murphy G, Sullivan MO, Shanahan F, Harney S, Molloy M. Cogan's syndrome: present and future directions. *Rheumatol Int* 2009;29(10):1117-21.
3. Pagnini I, Zannin ME, Vittadello F, Sari F, Simonini G, Cimaz R, et al. Clinical features and outcome of Cogan syndrome. *J Pediatr* 2012;160(2):303-7.
4. Orsoni J, Zavota L, Pellistri I, Piazza F, Cimino L. Cogan syndrome. *Cornea* 2002;21(4):356-9.
5. Grasland A, Pouchot J, Hachulla E, Blétry O, Papo T, Vinceneux P, et al. Typical and atypical Cogan's syndrome: 32 cases and review of the literature. *Rheumatology (Oxford)* 2004;43(8):1007-15.
6. Migliori G, Battisti E, Pari M, Vitelli N, Cingolani C. A shifty diagnosis: Cogan's syndrome. A case report and review of the literature. *Acta Otorhinolaryngol Ital* 2009;29(2):108-13.
7. Lunardi C, Basson C, Leandri M, Navone R, Lestani M, Millo E, et al. Autoantibodies to inner ear and endothelial antigens in Cogan's syndrome. *Lancet* 2002;360(9337):915-21.
8. Gloddek B, Gloddek J, Arnold W. A rat T-cell line that mediates autoimmune disease of the inner ear in the Lewis rat. *ORL J Otorhinolaryngol Relat Spec* 1999;61(4):181-7.
9. Ljungström L, Franzén C, Schlaug M, Elowson S, Viidas U. Reinfection with *Chlamydia pneumoniae* may induce isolated and systemic vasculitis in small and large vessels. *Scand J Infect Dis Suppl* 1997;104:37-40.

10. Haynes BF, Kaiser-Kupfer MI, Mason P, Fauci AS. Cogan syndrome: studies in thirteen patients, long-term follow-up and a review of the literature. *Medicine* 1980;59(6):426-41.
11. Ndiaye IC, Rassi SJ, Wiener-Vacher SR. Cochleovestibular impairment in pediatric Cogan's syndrome. *Pediatrics* 2002;109(2):E38.
12. Helmchen C, Jäger L, Büttner U, Reiser M, Brandt T. Cogan's syndrome. High resolution MRI indicators of activity. *J Vestib Res* 1998;8(2):155-67.
13. Mazlumzadeh M, Lowe VJ, Mullan BP, Fabry DA, McDonald TJ, Matteson EL. The utility of positron emission tomography in the evaluation of autoimmune hearing loss. *Otol Neurotol* 2003;24(2):201-4.
14. Massinger C, Keilmann A. [Cogan-I-syndrome: A rare differential diagnosis in progressive sensorineural hearing loss]. *HNO* 2003;51(1):66-70. [Article in German]
15. Scharl M, Frei P, Fried M, Rogler G, Vavricka SR. Association between Cogan's syndrome and inflammatory bowel disease: a case series. *J Crohns Colitis* 2011;5(1):64-8.
16. Greco A, Gallo A, Fusconi M, Magliulo G, Turchetta R, Marinelli C, et al. Cogan's syndrome: an autoimmune inner ear disease. *Autoimmun Rev* 2013;12(3):396-400.
17. Lepur D, Vranjican Z, Himbele J, Klinar I, Barsić B. Chlamydia pneumoniae infection as a trigger for a Cogan's syndrome. *J Infect* 2006;52(3):223-6.
18. Lallemand F, Felt-Baeyens O, Besseghir K, Behar-Cohen F, Gurny R. Cyclosporine A delivery to the eye: a pharmaceutical challenge. *Eur J Pharm Biopharm* 2003;56(3):307-18.
19. Shimura M, Yasuda K, Fuse N, Nakazawa M, Tamai M. Effective treatment with topical cyclosporin A of a patient with Cogan syndrome. *Ophthalmologica* 2000;214(6):429-32.
20. Holland EJ, Olsen TW, Ketcham JM, Florine C, Krachmer JH, Purcell JJ, et al. Topical cyclosporin A in the treatment of anterior segment inflammatory disease. *Cornea* 1993;12(5):413-9.