

Clinicopathological Report of Three Cases of Opacification in Hydrophilic Acrylic Intraocular Lenses

Hamid Khakshoor, MD¹ • Hamid Gharaee, MD² • Amirhossein Vejdani, MD³
Masoud Shafiee, MD⁴ • Masoud Shahabian, MD⁵

Abstract

Purpose: To report clinical and pathological features of three cases of opacification with hydrophilic acrylic intraocular lenses (IOLs)

Case reports: In this interventional case report, we introduce the surgical and laboratory information about three hydrophilic acrylic IOLs which calcified after implantation for these patients with cataract. These lenses were explanted and analyzed with optical microscopy and pathological evaluation.

Results: Microscopic analyses showed granular deposits and pathological evaluation revealed deposition of calcium crystals.

Conclusion: Pathologic analyses of explanted IOLs revealed that late opacification of hydrophilic acrylic IOLs are the result of calcification. Patient related factors might have been responsible for this complication.

Keywords: Hydrophilic Intraocular Lens, Calcification, Pathology

Iranian Journal of Ophthalmology 2013;25(3):238-243 © 2013 by the Iranian Society of Ophthalmology

Introduction

Small-incision cataract surgery using foldable intraocular lenses (IOLs) has gained increasing popularity¹ which has led to a rise in the number of complications that requires serious investigations.² These complications include opacification of IOLs, which has been recognized for several years.³ Most reported cases have been late opacification of

hydrophilic acrylic IOLs.⁴⁻¹⁰ However, single cases of opacification have been reported with silicone IOLs.¹¹⁻¹³ Opacification reduces visual acuity (VA) and it requires some investigation. We report the clinical history and pathological analysis of three cases of progressive opacification in hydrophilic acrylic IOLs.

-
1. Associate Professor of Ophthalmology, Eye Research Center, Department of Ophthalmology, Khatam-al-Anbia Hospital, Mashhad University of Medical Sciences, Mashhad, Iran
 2. Assistant Professor of Ophthalmology, Department of Ophthalmology, Khatam-al-Anbia Hospital, Mashhad University of Medical Sciences, Mashhad, Iran
 3. Ophthalmologist, Department of Ophthalmology, Khatam-al-Anbia Hospital, Mashhad University of Medical Sciences, Mashhad, Iran
 4. Resident in Ophthalmology, Department of Ophthalmology, Khatam-al-Anbia Hospital, Mashhad University of Medical Sciences, Mashhad, Iran
 5. General Practitioner, Khatam-al-Anbia Hospital, Mashhad University of Medical Sciences, Mashhad, Iran

Received: April 30, 2013

Accepted: August 2, 2013

Correspondence to: Amirhossein Vejdani, MD

Ophthalmologist, Department of Ophthalmology, Khatam-al-Anbia Hospital, Mashhad University of Medical Sciences, Mashhad, Iran,
Email: amirhosein_vejdani@yahoo.com

Case reports

Case 1

A 52-year-old man had uneventful right eye cataract surgery and implantation of an Acryl C160 IOL (Ophthalmed; 18.5 D) in January 2001. The surgery was performed using the phacoemulsification technique. He underwent a similar procedure with a different foldable lens (Morcher; 19.0 D) in the left eye three months later, leading to a visual outcome of $^{10}/_{10}$ and had no problems since.

On examination, the best corrected visual acuity (BCVA) improved to $^{10}/_{10}$ (right eye). During follow-up, no intraocular inflammation or increased intraocular pressure (IOP) was detected.

Six years later, opacification of the implanted lens had caused decreased vision (BCVA decreased to $^7/_{10}$) (Figure 1). The possibility of an IOL exchange was discussed with the patient. The IOL was exchanged with a single-piece acrylic lens (Excelens; 19 D) (Figure 2).

Case 2

A 38-year-old female with VA of $^2/_{10}$ because of a right eye cataract underwent routine right phacoemulsification and IOL implantation in 2003. A foldable hydrophilic acrylic IOL (Morcher®; 19.0 D) was implanted in the capsular bag. She was referred to the clinic again in 2005 and underwent a neodymium: YAG [Nd: YAG] laser with a diagnosis of posterior capsule opacification.

Later during the follow-up, the IOL was found to be opacified by slit-lamp examination (Figure 3). Uncorrected visual acuity (UCVA) was $^2/_{10}$ and BCVA was $^7/_{10}$.

Exchange of the posterior chamber IOL with another foldable hydrophilic acrylic IOL (Zonula®, Mediphacos) was performed. At last observation, the patient had VA of $^4/_{10}$ and BCVA of $^7/_{10}$. Optical coherence tomography confirmed the diagnosis of cystoid macular edema.

Case 3

A 51-year-old male with a history of left eye glaucoma and cataracts underwent uneventful left eye trabeculectomy plus phacoemulsification with implantation of a single-piece hydrophilic acrylic intraocular lens (Ioflex®, Mediphacos; 22.0 D) in December 2006. Five months after surgery,

timolol was administered to control high IOP. Later, biosopt and xalatan were added to reduce IOP.

On presentation, BCVA had improved to $^7/_{10}$, but approximately two years after surgery white granular deposits appeared at the center of the IOL (Figure 4). The deposits were not associated with a significant decrease in VA.

The most recent documented VA in the left eye was $^5/_{10}$ and the patient is under follow-up, since he has not had a significant decrease in visual function (Figure 5).

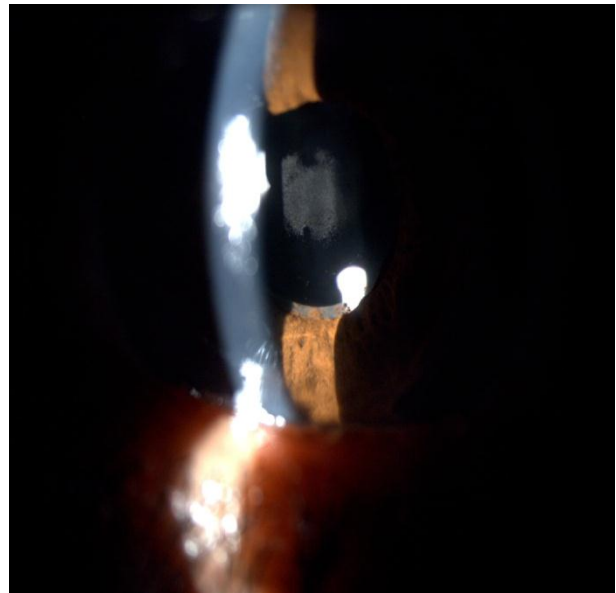


Figure 1. Preoperative slit-lamp photograph from the right eye of a 52-year-old man showing deposits on the surface of the intraocular lens




Figure 2. Slit-lamp photograph showing diffuse milky white opalescence of the intraocular lens

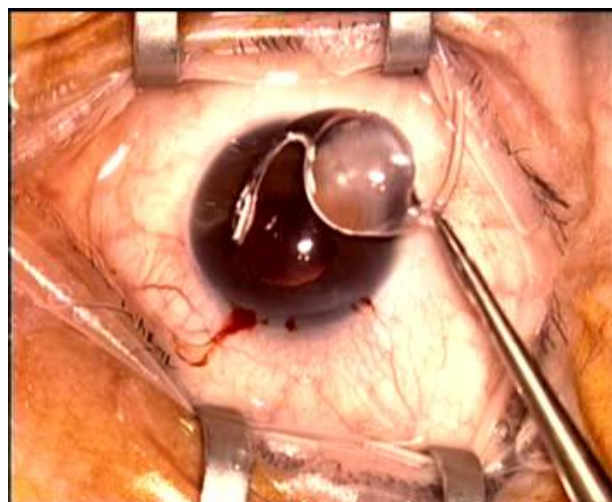


Figure 3. Explanted opacified Acryl C160 IOL: gross photograph of the IOL

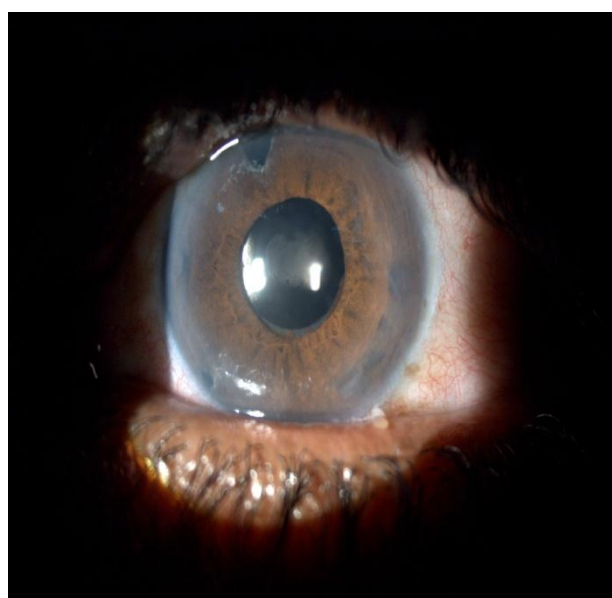


Figure 4. White granular deposits at the center of the intraocular lens

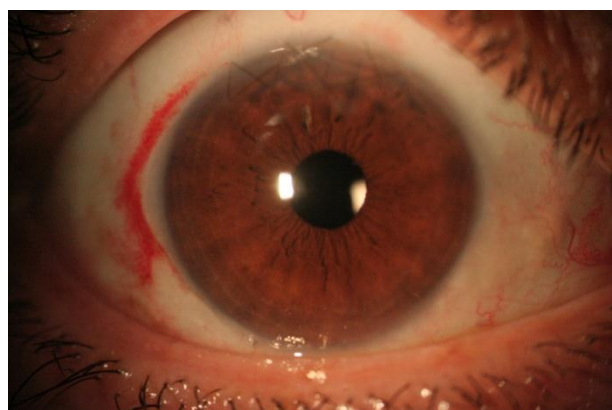


Figure 5. Postoperative view of the patient eye

Results

The IOLs of patients in cases 1 and 2 were explanted through a small incision at the edge of the capsulorhexis, after viscodissection from capsular bag and folding the lens which was removed carefully. Capsular bag was the site for the new lens.

In both cases, gross (macroscopic) analysis of the explanted IOLs showed that the IOL optic was completely opacified. Opacification had begun to involve both haptics in case 1. Microscopic analyses of full-thickness sections through the explanted lenses showed granular deposits that stained with 1% alizarin red. In these cases calcium was found to be the cause of IOL haze or opacification.

Discussion

The number of IOL implantations is growing daily worldwide, but fortunately complications related to foldable acrylic IOL itself are rare. Each IOL is manufactured from a different copolymer acrylic material. Loss of IOL transparency is a potential problem that results in gradual deterioration of VA. Therefore, this clinical problem must be considered when evaluating the long-term biocompatibility of the lens material.

Changes in the IOL material have been reported as fogging or glistening.¹⁴ Glistening is related to the formation of vacuoles inside the lens body because of raised temperature beyond the glass transition temperature and water entrance to the vacuoles. As a result, glistening is related to thermal effects inside the lens rather than structural changes. In our cases no evidence of glistening of the lens was detected.

Protein absorption to the IOL surface is another cause of opacification¹⁵ there is a hypothesis that immunological response of the eye (Antigen-antibody complexes) would bring on proteins to the IOL. In these cases we did not find any proteins in the lens material.

UV radiation is harmful to the retina and for protection, UV-C radiation (200-290 nm) is absorbed in the cornea, UV-B radiation (290-320 nm) is absorbed by the lens capsule and UV-A radiation (320-400 nm) is absorbed by stroma of the lens.¹⁶ By removing the lens, eye loses one of the protection filters and the manufactured IOLs have a UV-blocking agent for this purpose. This blocking is much higher

in some IOLs and the origin of opacification can be aging process of the UV-blocking agent.¹⁷

One major cause of IOL opacification can be calcification. The formation of calcium deposits consisting of calcium phosphate salts may be attributed to the fact that aqueous humor is supersaturated with calcium crystalline.¹⁸ Calcification may be on the outer surface or in the inner part of the IOL. Izak described two patterns of deposits as revealed by light microscopic and scanning electron microscope (SEM) analyses. Both irregular granular deposits on the external optical surfaces of the lens and multiple fine, granular deposits within the lens optic, distributed in a line parallel to the anterior and posterior curvatures of the optic, with a clear zone just beneath its external surfaces were exhibited simultaneously in Aqua-Sense lenses.⁵ It has been reported that polymethyl methacrylate modified in a way to increase the hydroxyl groups present on the surface and resulted in the formation of octa calcium phosphate on its surface.¹⁹

Calcium content of normal aqueous humor is low and is half of the serum level. Any cause of a localized increase in calcium and phosphorus may result in dystrophic calcification which can be derived from residual cataractous lens material and inadequate cortex cleaning during cataract surgery.²⁰

Biological calcification is the deposition of calcium phosphate salts on tissues of living organisms. Calcification occurs on foreign surfaces such as implants as well as vessel walls after a long time contact because of a supersaturated phenomenon in the biological fluids and formation of nucleus and crystals of calcium phosphates. Super saturation of aqueous humor may be the mechanism of crystalline lens late calcification.

However calcification is also affected by some factors such as polymer structure and water content. Surface complexes with calcium ions may act as the nucleus of mineral phase. The presence of hydroxyl and phosphate ions on the polymers accelerates hydroxyapatite overgrowth on polymeric components of the IOL.²¹

There have been case reports of calcification in various types of IOLs. Werner reported four major IOL designs manufactured

in the US with this problem. They were Hydroview (Bausch & Lomb) lens, the MemoryLens (Ciba Vision), the SC60B-OUV (Medical Developmental Research), and the Aqua-Sense (Ophthalmic Innovations International). Some have been removed from the market, and a change in the polishing process resolved the problem for others.²² Calcium depositions had been occurred in various types of IOLs at the late postoperative periods.

Previous studies reported IOL discoloration after exposure to intraocular dye.²³ Such exposure did not occur in our cases.

Systemic diseases such as diabetes were implied in the pathogenesis of IOL calcification²⁴⁻²⁶ but the mechanism is not clear. Whether changes in blood aqueous barrier is responsible for the phenomenon or there is another mechanism. We did not find any probable predisposing factors in our cases but the possibility of an induced mechanism, such as a metabolic imbalance, cannot be ruled out.

Characteristics of the patients or surgical procedure may be the other predisposing factors for the IOL opacification. In our case 2, posterior capsul opacification (PCO) had occurred that needed YAG laser therapy. Factors that can prevent PCO formation are tight contact between the IOL posterior surface and posterior capsule, the shrink-wrap effect of the IOL by capsular bag. However the new designs of IOL can be helpful in prevention of PCO.²⁷

No attempts has been made to determine whether one particular material or design of IOL is better than the other but the surgeons that use a special type of IOL should be alert about the complications and secondary interventions that may be needed. Further investigations on calcification process in different types of IOL will improve safety and efficacy of IOLs and special care must be taken to avoid nucleation of mineral deposits on the surface of IOL. It is important for the surgeons to know the possible complications of implanted IOLs. However the mechanism of some IOL opacifications is not really understood but this cannot be generalized to all of IOLs used in the field of cataract surgery.

Surgical investigation for removal of IOLs is required in cases of vision threatening opacification. The technique is usually hazardous and challenging due to the tight adherence of the IOL to the capsular bag. Cutting the haptics before removal of the opacified IOL is sometimes required.²⁸

Conclusion

Complications include zonular dehiscence, rupture of the posterior capsule and corneal decompensation. Circumferential enlargement of the preexisting capsulorrhexis is a critical step during surgery and would minimize traction on the capsule and hence the risk of zonular dehiscence or posterior capsule rupture.^{29,30}

References

1. Leaming DV. Practice styles and preferences of ASCRS members--2002 survey. *J Cataract Refract Surg* 2003;29(7):1412-20.
2. Mamalis N, Davis B, Nilson CD, Hickman MS, Leboyer RM. Complications of foldable intraocular lenses requiring explantation or secondary intervention--2003 survey update. *J Cataract Refract Surg* 2004;30(10):2209-18.
3. Neuhann IM, Neuhann TF, Szurman P, Koerner S, Rohrbach JM, Bartz-Schmidt KU. Clinicopathological correlation of 3 patterns of calcification in a hydrophilic acrylic intraocular lens. *J Cataract Refract Surg* 2009;35(3):593-7.
4. Werner L, Apple DJ, Kaskaloglu M, Pandey SK. Dense opacification of the optical component of a hydrophilic acrylic intraocular lens; a clinicopathological analysis of 9 explanted lenses. *J Cataract Refract Surg* 2001;27(9):1485-92.
5. Izak AM, Werner L, Pandey SK, Apple DJ. Calcification of modern foldable hydrogel intraocular lens designs. *Eye (Lond)* 2003;17(3):393-406.
6. Neuhann IM, Werner L, Izak AM, Pandey SK, Kleinmann G, Mamalis N, et al. Late postoperative opacification of a hydrophilic acrylic (hydrogel) intraocular lens: a clinicopathological analysis of 106 explants. *Ophthalmology* 2004;111(11):2094-101.
7. Werner L, Apple DJ, Escobar-Gomez M, Ohrström A, Crayford BB, Bianchi R, et al. Postoperative deposition of calcium on the surfaces of a hydrogel intraocular lens. *Ophthalmology* 2000;107(12):2179-85.
8. Dorey MW, Brownstein S, Hill VE, Mathew B, Botton G, Kertes PJ, et al. Proposed pathogenesis for the delayed postoperative opacification of the hydroview hydrogel intraocular lens. *Am J Ophthalmol* 2003;135(5):591-8.
9. Pandey SK, Werner L, Apple DJ, Kaskaloglu M. Hydrophilic acrylic intraocular lens optic and haptics opacification in a diabetic patient; bilateral case report and clinicopathologic correlation. *Ophthalmology* 2002;109(11):2042-51.
10. Klebe S, Kirkwood BJ, Coster DJ. Delayed surface opacification of a hydroview intraocular lens. *Clin Exp Optom* 2006;89(6):386-9.
11. Tanaka T, Saika S, Hashizume N, Ohnishi Y. Brown haze in an Allergan SI-40NB silicone intraocular lens. *J Cataract Refract Surg* 2004;30(1):250-2.
12. Hilgert CR, Hilgert A, Höfling-Lima AL, Farah ME, Werner L. Early opacification of SI-40NB silicone intraocular lenses. *J Cataract Refract Surg* 2004;30(10):2225-9.
13. Sathyan P, Myint K, Singh G, Mon S, Sathyan P, Dhillon B. Late green discoloration of Allergan SI-40NB silicone intraocular lens. *J Cataract Refract Surg* 2006;32(9):1584-5.
14. Werner L. Glistenings and surface light scattering in intraocular lenses. *J Cataract Refract Surg* 2010;36(8):1398-420.
15. Johnston RL, Spalton DJ, Hussain A, Marshall J. In vitro protein adsorption to 2 intraocular lens materials. *J Cataract Refract Surg* 1999;25(8):1109-15.
16. Abadi RV, Davies IP, Papas E. The spectral transmittance of hydrogel contact lens filters. *Ophthalmic Physiol Opt* 1989;9(4):360-7.
17. Frohn A, Dick HB, Augustin AJ, Grus FH. Late opacification of the foldable hydrophilic acrylic lens SC60B-OUV. *Ophthalmology* 2001;108(11):1999-2004.

18. Gartaganis SP, Kanellopoulou DG, Mela EK, Panteli VS, Koutsoukos PG. Opacification of hydrophilic acrylic intraocular lens attributable to calcification: investigation on mechanism. *Am J Ophthalmol* 2008;146(3):395-403.
19. Choi SM, Yang WK, Yoo YW, Lee WK. Effect of surface modification on the in vitro calcium phosphate growth on the surface of poly(methyl methacrylate) and bioactivity. *Colloids Surf B Biointerfaces* 2010;76(1):326-33.
20. Bucher PJ, Büchi ER, Daicker BC. Dystrophic calcification of an implanted hydroxyethylmethacrylate intraocular lens. *Arch Ophthalmol* 1995;113(11):1431-5.
21. Drimtzias EG, Rokidi SG, Gartaganis SP, Koutsoukos PG. Experimental investigation on mechanism of hydrophilic acrylic intraocular lens calcification. *Am J Ophthalmol* 2011;152(5):824-33.
22. Werner L. Causes of intraocular lens opacification or discoloration. *J Cataract Refract Surg* 2007;33(4):713-26.
23. Werner L, Apple DJ, Crema AS, Izak AM, Pandey SK, Trivedi RH, et al. Permanent blue discoloration of a hydrogel intraocular lens by intraoperative trypan blue. *J Cataract Refract Surg* 2002;28(7):1279-86.
24. Yu AK, Kwan KY, Chan DH, Fong DY. Clinical features of 46 eyes with calcified hydrogel intraocular lenses. *J Cataract Refract Surg* 2001;27(10):1596-606.
25. Kim CJ, Choi SK. Analysis of aqueous humor calcium and phosphate from cataract eyes with and without diabetes mellitus. *Korean J Ophthalmol* 2007;21(2):90-4.
26. Kim CY, Kang SJ, Lee SJ, Park SH, Koh HJ. Opacification of a hydrophilic acrylic intraocular lens with exacerbation of Behçet's uveitis. *J Cataract Refract Surg* 2002;28(7):1276-8.
27. Leishman L, Werner L, Bodnar Z, Ollerton A, Michelson J, Schmutz M, et al. Prevention of capsular bag opacification with a modified hydrophilic acrylic disk-shaped intraocular lens. *J Cataract Refract Surg* 2012;38(9):1664-70.
28. Al-Bdour MD, Dahabreh LS. Late opacification of a hydrophilic acrylic intraocular lens. *Middle East Afr J Ophthalmol* 2008;15(1):37-8.
29. Dagres E, Khan MA, Kyle GM, Clark D. Perioperative complications of intraocular lens exchange in patients with opacified Aqua-Sense lenses. *J Cataract Refract Surg* 2004;30(12):2569-73.
30. Voros GM, Strong NP. Exchange technique for opacified hydrophilic acrylic intraocular lenses. *Eur J Ophthalmol* 2005;15(4):465-7.