

Advanced Cataracts and Pseudotumor Cerebri as the First Presentations of Hypoparathyroidism

Mehrdad Mohammadpour, MD¹ • Hassan Hashemi, MD^{2,3} • Mahmoud Jabbarvand, MD³
Firoozeh Rahimi, MD³ • Amir Houshang Beheshtnejad, MD⁴ • Mohammad Naser Hashemian, MD³
Mohammad Ali Zare, MD⁴ • Mohammadreza Fallah Tafti, MD⁴ • Siamak Karkheiran, MD⁵
Khalilullah Arefi⁶ • Mohammad Saeed Shakari⁶ • Shayan Khoshkish⁶

Abstract

Purpose: To report a rare case of a patient with hypoparathyroidism presenting with bilateral disc swelling and near mature cataract as her first clinical manifestation

Case report: A 23-year-old woman presented with complaint of worsening vision since one year ago and a history of refractory seizures and headache for several years, being under treatment with Lamotrigine 50 mg/daily. Slit-lamp examination revealed significant cataracts on both sides. Red reflex was dull in the right eye and absent in the left side. The intraocular pressure (IOP) measurement was normal in both eyes (16 mmHg). Her fundus examination revealed disc swelling in her right eye and hazy media that obscured fundus examination due to dense cataract in the left eye. The combination of bilateral disc swelling and dense cataracts raised suspicion to hypoparathyroidism. Subsequently, neuroimaging and intracranial pressure (ICP) monitoring was requested along with neuro-ophthalmology consultation. The diagnosis was Pseudotumor Cerebri. Due to increased ICP, she underwent multiple lumbar punctures. Computed tomography (CT) scan showed abnormal signal density in basal ganglia suggestive for presence of calcium depositions, making the diagnosis of hypoparathyroidism more probable. Ensuing laboratory result made the definite diagnosis of hypoparathyroidism. Meanwhile the cataract progressed and the visual acuity (VA) decreased to HM in her both eyes. She underwent cataract extraction and PCIOL implantation. Papilledema resolved and the vision restored to ²⁰/₂₀.

Conclusion: Ocular complaints happens very rare in the course of hypoparathyroidism but still it seems rational that this occasionally fatal condition be ruled out by hormonal evaluation for cases of unexplained cataracts, particularly if it is accompanied by disc swelling.

Keywords: Cataract, Pseudotumor Cerebri, Hypoparathyroidism

Iranian Journal of Ophthalmology 2013;25(3):244-248 © 2013 by the Iranian Society of Ophthalmology

1. Assistant Professor of Ophthalmology, Eye Research Center, Farabi Eye Hospital, Tehran University of Medical Sciences, Tehran, Iran
2. Noor Ophthalmology Research Center, Noor Eye Hospital, Tehran, Iran
3. Professor of Ophthalmology, Eye Research Center, Farabi Eye Hospital, Tehran University of Medical Sciences, Tehran, Iran
4. Associate Professor of Ophthalmology, Eye Research Center, Farabi Eye Hospital, Tehran University of Medical Sciences, Tehran, Iran
5. Neurologist, Eye Research Center, Farabi Eye Hospital, Tehran University of Medical Sciences, Tehran, Iran
6. Medical Student, Eye Research Center, Farabi Eye Hospital, Tehran University of Medical Sciences, Tehran, Iran

Received: April 4, 2013

Accepted: August 11, 2013

Correspondence to: Mehrdad Mohammadpour, MD

Assistant Professor of Ophthalmology, Eye Research Center, Farabi Eye Hospital, Tehran University of Medical Sciences, Tehran, Iran
Email: mahammadpour@yahoo.com

This manuscript has not been presented in any scientific gathering.

The authors have no financial or proprietary interest in a product, method or material described herein.

Introduction

Hypoparathyroidism is decreased function of parathyroid gland leading to lowered levels of calcium in blood. Hypocalcaemia in turn can result in a wide range of signs in symptoms involving different organs of the body. Muscle cramps, impairment in nerve conduction, tetany, fatigue, paresthesia, headache, crampy abdominal pain and bone pain are some common symptoms and signs seen in hypocalcaemia. Seizures and cardiac arrhythmias are amongst the most life threatening emergencies in hypocalcaemia. Unlike hypoparathyroidism, pseudo-hypoparathyroidism is a condition in which hypocalcaemia and the following complications are due to impaired receptor function despite increased levels of parathyroid hormone.

In terms of etiology, hypoparathyroidism can be idiopathic, iatrogenic, autoimmune, hereditary or due to hemochromatosis, DiGeorge syndrome and low blood magnesium. The diagnosis is readily made by measurement of blood levels of calcium, magnesium, albumin and PTH.

We present a case of a female patient with complaint of blurred vision as her first clinical manifestation found to be due to hypoparathyroidism after further evaluations. Ocular involvement as the first clinical manifestation of hypoparathyroidism is reported only rarely in literature, yet this is the first case of posterior sublenticular cataract to be reported.¹

Case report

A 23-year-old woman presented to an ophthalmologist at Farabi Eye Hospital with complaint of insidiously diminishing vision of both eyes during the preceding year. She reported no history of trauma, applications of contact lenses or topical drugs. She also complained of refractory seizures and headaches for the past several years for which was taking Lamotrigine 50 mg/daily. In initial evaluations performed, visual acuity (VA) was counting fingers in the left and 2/10 in the right eye. Slit-lamp examination revealed significant cataracts on both sides. Red reflex was dull in the right eye and absent

in the left side. The intraocular pressure (IOP) measurement was normal in both eyes (16 mmHg). Pupil of both eyes were round and equal in size and reactive to light. Indirect ophthalmoscopy detected disc swelling in her right eye (Figure 1) and hazy media due to dense cataract in the left eye. The combination of bilateral disc swelling and significant, progressive cataract raised suspicion to hypoparathyroidism. Subsequently due to bilateral papilledema neuroimaging and intracranial pressure (ICP) monitoring was requested along with neuro-ophthalmology consultation. The ICP was 72 mmHg.

The diagnosis was pseudotumor cerebri. Due to increased ICP, she underwent multiple lumbar punctures to manage increased ICP due to pseudotumor cerebri.

Computed Tomography (CT) scan showed abnormal signal density in basal ganglia suggestive for presence of calcium depositions, making the diagnosis of hypoparathyroidism more probable. Ensuing laboratory result made the definite diagnosis of hypoparathyroidism. Parathyroid hormone was 8.0 pg/ml (Normal: 17.3-70 pg/ml), 25 OH-Vitamin "D" total was 9.1 ng/ml (Deficiency <10).

The treatment of her systemic disease started urgently with systemic intravenous and then oral prescription of Vitamin D3 and calcium and repeated lumbar punctures for decreasing the ICP.

Fortunately, the patient responded favorably to systemic treatments. The calcium level of the serum raised to normal range and subsequently the seizure attacks were discontinued without need to anticonvulsant therapies.

Meanwhile the cataract progressed and the VA decreased to HM in her both eyes (Figure 2). She underwent cataract extraction and PCIOL implantation (Figure 3). Papilledema resolved (Figure 4) and the vision restored to ²⁰/₂₀.

The patient was operated for her cataract and her neurological complaint including headache and seizures remarkably responded to daily oral supplementations of calcium.

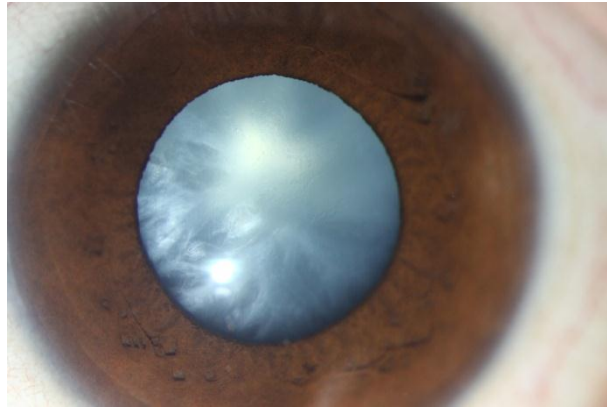


Figure 1. Left eye with mature cataract

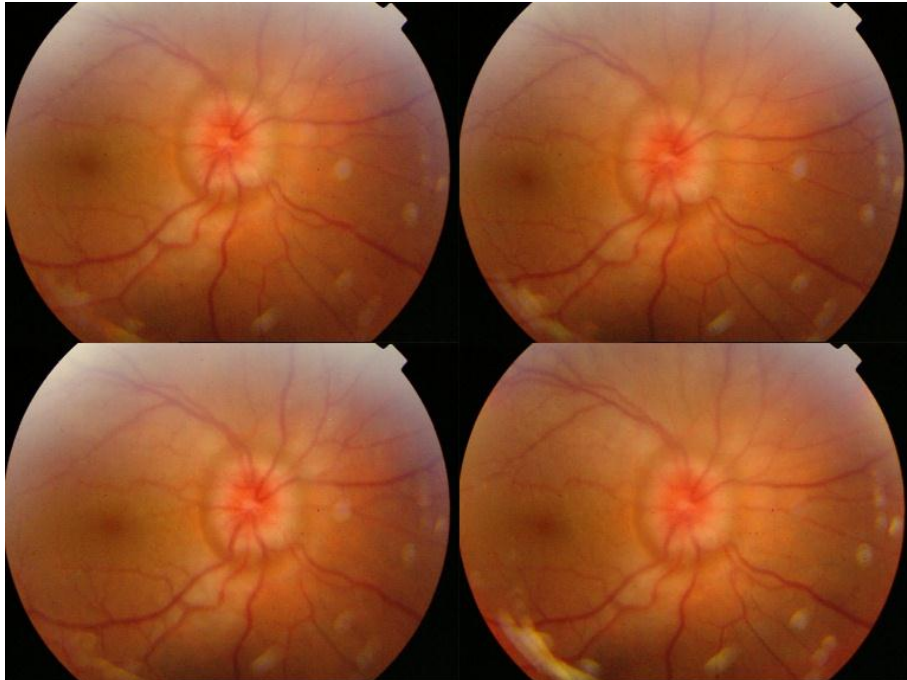


Figure 2. Papilledema can be seen in right eye.

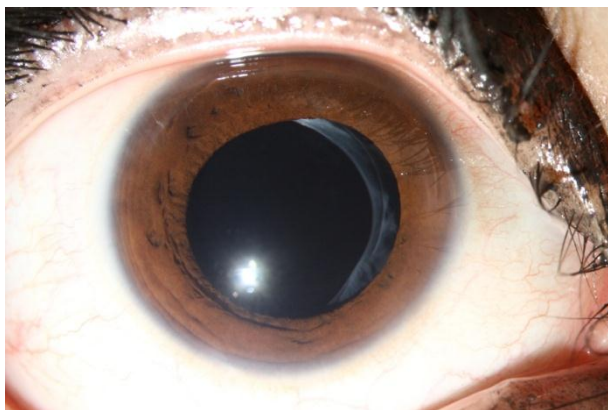


Figure 3. Postoperative status of the left eye following cataract surgery and intraocular lens implantation

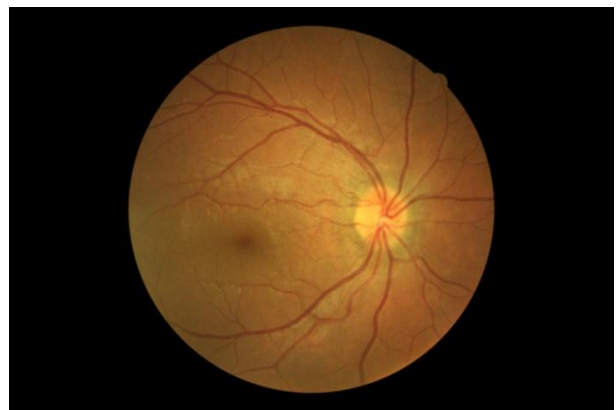

Figure 4. Fundus exam of the right eye after treatment of increased intracranial pressure and hypocalcemia showing improvement of disc swelling

Discussion

Hypoparathyroidism is an endocrine and metabolic disease in which deranged amount of parathormone provides a hypocalcemic milieu and progression of multi organ pathological processes that manifest themselves as different clinical pictures. Although scarce, eye is a well-known site to be involved during the course of the disease. Ophthalmic involvements in hypoparathyroidism are well-documented and include papilledema (first described by Ludwig in 1903¹) and early lenticular cataract^{3,4} and raised ICP.³

In the present case, severe hypocalcemia gave rise to a set of neurological symptoms misdiagnosed as idiopathic seizures that along with lack of classical symptoms of hypocalcemia caused rather a long delay in diagnosing the underlying culprit which is hypoparathyroidism. As ocular manifestations being so rare in hypoparathyroidism, it is very uncommon that such condition to be diagnosed by an ophthalmologist before any other organ involvement which raised suspicion to proper diagnosis. To the best of our knowledge, there has been just one report as the ophthalmic complaints being the first clinical manifestations of hypoparathyroidism⁶ but unlike that report, the present case presented bilateral mature cataract in addition to papilledema. Cataract is a condition which occurs late in the course of hypoparathyroidism. Cataract formation is mostly attributed to decreased calcium level but lenticular effects of parathyroid hormone has also been proposed in the literature and despite its dubious mechanism, a few hypothesized have been suggested. One of which, is the known direct effect of parathyroid hormone on carbohydrate metabolism and the association of carbohydrate metabolism defects and cataract formation⁷ indicated by inability of utilizing glucose and production of lactic acid by lens after parathyroidectomy.

Papilledema, also rare yet well-known in hypoparathyroidism, can happen through different mechanisms. Two of which are hyper secretion of cerebrospinal fluid (CSF)⁵ and

decreased ability of CSF reuptake subsequent to diminished level of serum calcium.⁸ But the fact is that papilledema does not necessarily accompany increased CSF pressure.

It is also noteworthy to mention that chronicity and pace in which hypocalcemia occurs plays an important role in the manner that hypoparathyroidism presents itself. As this case proclaims, chronic forms of hypocalcemia can exhibit themselves as such infrequent clinical pictures as it would take several years before the diagnosis is made. It seems interesting, though, how dramatically all the above symptoms and signs responded to oral calcium supplementation except for cataract which needed surgical intervention.

Systemic diseases specially endocrine problems are usually associated with ocular morbidities and may even initially present themselves with eye involvement.⁹⁻¹¹ The ophthalmologist may be the first referral person and he should always be avid for systemic findings that may guide him to the proper diagnosis. Consultation with experts is strongly recommended and is often a good guide in diagnosis.

Cataract surgery may have the risk of increased postoperative inflammation particularly in young patients. Therefore, it is logical to prevent it by prescribing judicious steroid treatment¹² such as in this case.

Conclusion

Despite the rarity of ophthalmic involvement, hypoparathyroidism can manifest itself as ocular manifestations and to be the first clinical picture of the disease. This warrants the prompt investigation for such scenarios of cataract or papilledema with no justifiable underlying reason. Among these reasons, hypoparathyroidism plays a major role due to its progression which could be disastrous and life-threatening. A prompt diagnosis is mandatory since the disease does respond properly to the conventional remedies and supplements at the early stage.

References

1. Braunwald E, Fauci AS, Kasper DL, Hauser SL, Longo DL, Jameson JL. Harrison's Principles of Internal Medicine, 15th Edition (Jul, 2012).
2. Ayuk J, Matthews T, Tayebjee M, Gittoes NJ. A blind panic. *Lancet* 2001;21;357(9264):1262.
3. Jacques L. Cataract and postoperative Tetany. *Am J M Sc* 1928;175(2):185-95.
4. Cole L. Parathyroid Tetany and cataract. *Lancet* 1930;215(5549):13-6.
5. Sheldon RS, Becker WJ, Hanley DA, Culver RL. Hypoparathyroidism and pseudotumor cerebri: an infrequent clinical association. *Can J Neurol Sci* 1987;14(4):622-5.
6. Mukhopadhyay R, Strens LH, Winer JB, Ayuk JA, Gittoes NJ. Having the vision to measure calcium. *J Neurol* 2010;257(6):1032-4.
7. Firschein HE. Lenticular effects of parathyroid hormone. *Invest Ophthalmol* 1962;1:788-91.
8. Sambrook MA, Hill LF. Cerebrospinal fluid absorption in primary hypoparathyroidism. *J Neurol Neurosurg Psychiatry* 1977;40(10):1015-7.
9. Mohammadpour M. Keratitis associated with multiple endocrine deficiency. *Cornea* 2006;25(1):112-4.
10. Mohammadpour M. Limbal stem cell deficiency in the context of autoimmune polyendocrinopathy. *Eur J Ophthalmol* 2006;16(6):870-2.
11. Mohammadpour M. Progressive corneal vascularization caused by graft-versus-host disease. *Cornea* 2007;26(2):225-6.
12. Mohammadpour M, Jafarinasab MR, Javadi MA. Outcomes of acute postoperative inflammation after cataract surgery. *Eur J Ophthalmol* 2007;17(1):20-8.