

Color Doppler Imaging of Ocular Hemodynamic Alterations in Patients with Manifest Hyperopia

Tulay Simsek, MD¹ • Mehmet Citirik, MD¹ • Bahar Yanik, MD²

Abstract

Purpose: To assess orbital color Doppler ultrasonography (CDU) parameters of patients with manifest hyperopia in comparison to the emmetropes

Methods: Forty eyes of 40 patients presenting with manifest hyperopia were included into the study. Forty eyes of 40 emmetropes healthy volunteers also were examined as the control group. We have evaluated ophthalmic artery (OA), central retinal artery (CRA), posterior ciliary artery, central retinal vein (CRV), and superior ophthalmic vein (SOV) flow velocities and resistance indices (RI).

Results: RI value in the OA and mean velocities (MV) in the SOV were significantly higher in the group of manifest hyperopia. CDU parameters of the CRA, CRV, nasal and temporal posterior ciliary artery (nPCA, tPCA)) between hyperopic group and the control group were statistically insignificant.

Conclusion: Doppler ultrasonography findings revealed that some orbital CDU parameters are altered in eyes with manifest hyperopia compared to emmetropia. Particularly, increased RI suggested the possibility that increased choroidal vascular resistance may be associated with the pathological angiogenesis in the affected eye.

Keywords: Color Doppler, Ultrasonography Parameters, Hyperopia, Ocular Blood Flow

Iranian Journal of Ophthalmology 2014;26(2):82-6 © 2014 by the Iranian Society of Ophthalmology

Introduction

Hyperopia is a common refractive error and it can be divided into three types: absolute, manifest, and latent hyperopia. Manifest hyperopia is defined as the strongest convex lens correction accepted for clear distance vision.¹ A thicker eye wall in a shorter eye showed with biometric studies has been considered a general oculometric feature of hyperopia.^{2,3} A high incidence of hyperopia has been reported to be associated with retinal vein occlusion.⁴ Hyperopia is also a risk factor for exudative forms of age-related macular degeneration (AMD).⁵

Color Doppler ultrasonography (CDU) is a non-invasive method for evaluating blood flow velocities in the orbital and retinal vascular diseases. It is commonly used as a reliable, sensitive, and non-invasive method for the evaluation of ocular hemodynamics.⁶ Orbital CDU is also a valuable technique for the assessment of the alterations of blood flow parameters in various eye disorders.⁷ It has been reported that the central retinal artery (CRA) blood velocity was lower in highly myopic eyes using the CDU technique.⁸

1. SB Ankara Ulucanlar Eye Education and Research Hospital, Ankara, Turkey

2. Department of Radiology, SB Ankara Diskapi Education and Research Hospital, Ankara, Turkey

Received: February 18, 2014

Accepted: July 6, 2014

Correspondence to: Mehmet Citirik, MD

SB Ankara Ulucanlar Eye Education and Research Hospital, Ankara, Turkey, Email: mcitirik@hotmail.com

Disclaimer on financial support (grants): None

Potential conflicts of interest: None

© 2014 by the Iranian Society of Ophthalmology

Published by Otagh-e-Chap Inc.

The aim of this study is to evaluate the hemodynamic features of orbital blood flow velocities using CDU in patients with manifest hyperopia in comparison to those in emmetropes healthy volunteers.

Methods

This prospective study was performed in 40 eyes of 40 patients with manifest hyperopia in our hospital. Forty eyes of 40 emmetropes healthy volunteers' subjects with no history of systemic or ocular disease (including systemic hypertension and glaucoma) or smoking were included into the study. In the study protocol, Hyperopia was defined as the spherical equivalent refraction between +4.0 and 10.0 D. The objective total refraction was determined using an auto refractometer KR-8800 (Topcon, Tokyo, Japan). Axial lengths were obtained using an optical biometer based on optical coherence interferometry (IOL Master; Carl Zeiss, Germany). Each measurement consisted on the average of 3-5 scans. Patients with any other systemic (e.g., hypertension, diabetes mellitus) disorder or ocular operation was excluded from the study. All patients had normal systemic blood pressure (<140/90 mmHg) and intraocular eye pressure (10-19 mmHg) values. One eye of each control subject was randomly selected to measure orbital blood flow velocities.

All of the studied patients had undergone orbital CDU examination by the same researcher (B.Y.). Examinations were performed using an SSA 390A ultrasound scanner (Toshiba, Tokyo, Japan) and a 6- to 11-MHz linear-array transducer.

The operator had no knowledge of the patient's condition. The transducer was applied gently to the closed eyelid using a coupling gel, and care was taken to avoid any pressure to the eye. The study was performed while the subjects were lying on their back, with the head tilted forward at about a 30 degree angle. The ophthalmic artery (OA), the CRA, nasal and temporal posterior ciliary arteries (nPCA and tPCA, respectively), the central retinal vein (CRV), and the superior ophthalmic vein (SOV) were examined. In order to measure the OA velocity, the Doppler sample gate was set about 15-20 mm posterior to the globe. The CRA and CRV were identified within the optic nerve shadow,

about 2-3 mm behind the surface of the optic disc. The tPCA and nPCA were identified along the sides of the optic nerve within 5 mm behind the posterior sclera. Blood flow velocities in the SOV were measured just before it left the orbit. Examinations were performed in a medium flow setting to allow optimal detection of Doppler frequency shifts of the orbital vessels. After the vessels were identified via ultrasonography, spectral waveforms and quantitative information were obtained using the Doppler gate. The Doppler sample gate (≤ 3 mm) was placed on the detected vessels. As the orbital vessels were directed toward the transducer, the angle between the sound beam and the vessels were generally kept under 30° .

The peak systolic velocities (PSV), end-diastolic velocities (EDV), pulsatile indices (PI), and resistance indices (RI) were measured in the OA, CRA, tPCA, and nPCA. Mean velocities (MV) were obtained in the SOV and CRV. For each vessel, three consecutive measurements were performed and the average value was taken. Mean values and standard deviations were calculated for PSV, EDV, and RI in arterial structures and for MV in venous structures.

The statistical analysis was performed by a *t*-test according to Bonferroni procedures for multiple comparisons; any P value <0.05 was considered statistically significant. Differences among two groups for ages were evaluated using Mann Whitney U Test. All statistics in this study were analyzed using SPSS for Windows (SPSS Inc., Chicago, IL, USA). All procedures were conducted in accordance with the Declaration of Helsinki, and informed consent was obtained from all patients after approval from the Institutional Review Board.

Results

We prospectively evaluated 40 eyes of 40 patients with hyperopia using orbital CDU. Of these patients, 16 women and 24 men were available for evaluation. Patients were 19 to 60 years old (mean \pm SD 40.1 \pm 10.3 years). Forty eyes of 40 emmetropes control subjects, 18 women and 22 men, aged 18-58 years (mean \pm SD 42.4 \pm 11.1 years) were included in this study. Mean refractive error was 6.6 \pm 1.8 diopters (4-10 D) in study group. The mean refractive error was -0.38 \pm 0.22 diopters in the control group (0.00 \pm 1.25 D). The axial length

of hyperopic eyes (19.83 ± 1.46 mm) was significantly lower ($p < 0.001$) than the control eyes (21.62 ± 1.21 mm). At the time of CDU the intraocular pressure was on average 13.9 ± 2.6 mmHg (range, 10-19 mmHg) in hyperopic group and 12.2 ± 2.4 mmHg (range, 10-19 mmHg) in control group, without any pharmacological treatment.

All vessels, both in the control and in the study groups, were examined successfully. While performing orbital CDU, we did not detect any obstructed vessel. No significant

differences were detected between the ages of the control group and the patient group (Mann Whitney U Test $P: 0.117$). Table 1 shows the values of the OA, CRA, nPCA, tPCA, CRV, and SOV blood flow. The *t*-test showed statistically significant differences between hyperopic group and the control group for the following: RI in the OA ($P: 0.018$ with the Bonferroni *t*-test for multiple comparison), and MV in the SOV ($P: 0.018$ with the Bonferroni *t*-test for multiple comparison) (Figure 1).

Table 1. Velocity measurements in orbital vessels

Artery	Measurement	Velocity values (Mean±Standard deviation)		p
		Manifest Hyperopia	Control group	
Ophthalmic artery	Peak systolic velocities (cm/sec)	39.75±5.56	37.57±5.25	0.07
	End-diastolic velocities (cm/sec)	12.32±2.64	11.82±2.65	0.40
	Resistance indices	0.70±0.06	0.64±0.05	0.001
	Pulsatile indices	1.19±0.17	1.21±0.23	0.68
Central retinal artery	Peak systolic velocities (cm/sec)	11.95±2.57	11.70±2.50	0.66
	End-diastolic velocities (cm/sec)	4.17±1.05	4.22± 0.86	0.81
	Resistance indices	0.65±0.05	0.64±0.06	0.48
	Pulsatile indices	1.46± 0.44	1.52± 0.36	0.48
Temporal posterior ciliary arteries	Peak systolic velocities (cm/sec)	14.17±3.00	13.27±2.09	0.12
	End-diastolic velocities (cm/sec)	5.12±1.18	4.95±0.74	0.43
	Resistance indices	0.62±0.06	0.62±0.05	0.81
	Pulsatile indices	1.13±0.32	1.21±0.27	0.20
Nasal posterior ciliary arteries	Peak systolic velocities (cm/sec)	12.42±1.53	12.22±1.56	0.56
	End-diastolic velocities (cm/sec)	5.25±1.23	5.07±0.91	0.47
	Resistance indices	0.60±0.08	0.62±0.15	0.46
	Pulsatile indices	1.15±0.30	1.19±0.21	0.509
Superior ophthalmic vein	Mean velocities	11.45±2.92	8.95±1.79	0.001
Central retinal vein	Mean velocities (cm/sec)	5.95±1.79	6.15±1.77	0.61

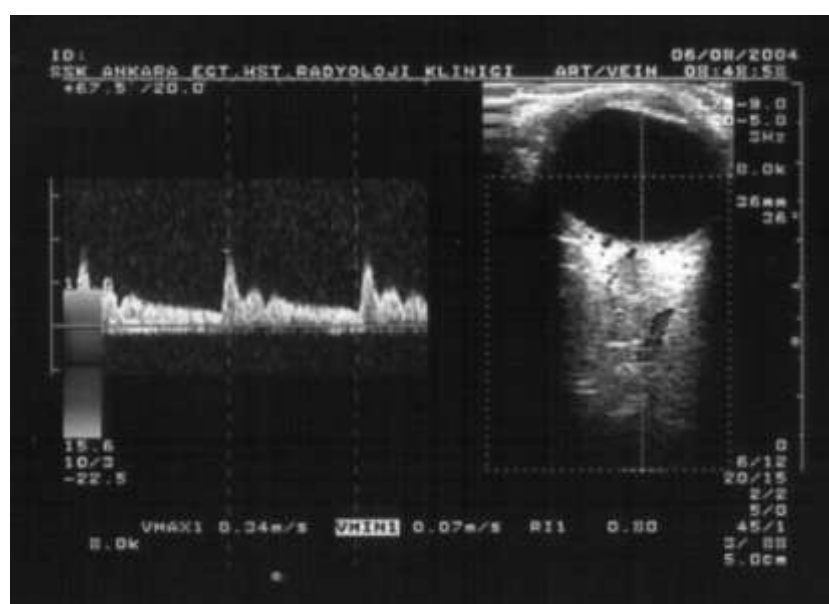


Figure 1. Increased resistance indices value (0.80) of ophthalmic artery in a case of hyperopic patient (peak systolic velocities: 34 cm/sec and end-diastolic velocities: 7 cm/sec)

RI in the OA and MV in the SOV calculated for hyperopic group were significantly higher than that calculated for the control group. Besides, no significant differences were obtained for the following: PSV, EDV, and PI in the OA; PSV, EDV, PI and RI in the CRA; PSV, EDV, PI and RI in the tPCA; PSV, EDV, PI and RI in the nPCA; MV in the CRV between two groups (Table 1).

Discussion

Orbital CDU is a non-invasive technique in the evaluation of flow hemodynamics in orbital vessels. CDU is a reliable technique for evaluating orbital diseases and can provide information relating to the flow, direction, course, and position of blood vessels.⁶ Biometric studies have shown that hyperopic eyes have shorter axial lengths and shallower anterior chambers than emmetropic eyes.³ A thicker eye wall in a shorter eye showed with biometric studies has been considered a general oculometric feature of hyperopia.^{2,3} An eye wall will appear thick and shortened in a hyperopic eye than normal eye. It is postulated that eyes with shorter axial length have smaller lamina cribrosa and a narrower scleral canal through which the CRV and artery could pass.⁹ This may lead to a relative mechanical blockage in the vein which may predispose to thrombus formation.¹⁰

Generalized stiffness of the sclera may cause an increase in resistance of the choroidal venous outflow¹¹ with throttling of the vorticose veins, and thicker choroids.¹² Both histologic and *in vivo* studies with laser Doppler flow measurements have shown an increased choroidal resistance in AMD-cases compared with gender-and age-matched controls.¹³ Therefore, decreased flow prevents easy exchange of nutrients and metabolic products across the RPE and results in drusen formation and thickening of Bruch's membrane.¹⁴ Other comments that may explain the observed association with hyperopia are that poorer cooling of the retina by an impaired choroidal blood flow may lead to a higher susceptibility to oxidative stress.¹⁴ Furthermore, the thicker retina in hyperopic versus myopic eyes may have a higher need for oxygen and nutrients.¹⁴ Likewise, it is uncertain whether the photoreceptor density per square millimeter of the fovea or per RPE cell is different in hyperopia. Kremmer et al¹⁵

found retinal nerve fiber layer decreasing not only with increasing myopia but also with increasing hyperopia. In previous studies that examined ocular blood flow in high myopia, mainly choroidal blood flow, there was a negative correlation between the axial length and choroidal blood flow using pulsatile ocular blood flow¹⁶ or color Doppler imaging techniques.⁸ To our knowledge, there have been no reports on ocular circulation in patients having manifest hyperopia. The local microcirculation in the hyperopic eye may be responsible for the hyperopic choroidal neovascularization. For testing this hypothesis, we measured the retrobulbar circulation in the eyes of patients having manifest hyperopia. Statistically significant differences were detected orbital CDU parameters of hyperopic group and the control group. RI in the OA was significantly higher than that of the control group. In other words, resistance increased in the vascular bed of the patients in the hyperopic group. The high vascular resistance in eyes with manifest hyperopia can be an argument for the hypothesis that the decrease in perfusion pressure caused by thick and shortened hyperopic eye is decrease in blood flow velocity of the OA. Factors that might affect the flow velocity such as increased systemic blood pressure or increased intraocular pressure were excluded in our study. The results indicating increased RI in the OA of the affected eye suggests a circulatory dysfunction in the choroidal circulation. The RI is considered to represent peripheral vascular resistivity.¹⁷ Increased RI has been found in other proliferative ophthalmic diseases, such as diabetic retinopathy¹⁸ and age related maculopathy.¹⁹ Therefore, the fact that increased RI suggests the possibility that increased choroidal vascular resistivity could be associated with angiogenesis in affected eye.¹⁹ Improvement of the choroidal circulation may be important for the prevention of hyperopia related age related maculopathy.²⁰

In our study, MV in the SOV in hyperopic group was found to be significantly higher than control group. The SOV carries most the venous drainage from the orbit and the eye, it is usually fused with the thinner inferior ophthalmic vein, and it empties the combined venous blood into the cavernous sinus.²¹

Friedman et al²² found a significantly higher coefficient of scleral rigidity in AMD patients—a finding that may be associated with increased scleral rigidity that could interfere with venous outflow. Also, increased choriocapillaris density and diameters with decrease the total choroidal vascular resistance have been documented in histopathologic studies of patients with AMD.²³ Decrease in total choroidal vascular resistance would be associated with increase MV of SOV. Possibly, this could be due to an autoregulatory attempt to maintain a constant choroidal blood flow. It is possible that therapies that stabilize the circulation of the choroid may be of benefit in the treatment of hyperopia related age related maculopathy.

There are several limitations in our present study. Firstly, the number of patient was small with 40 eyes in study group. Secondly, other refractive conditions were not evaluated.

Conclusion

Our study demonstrates that orbital CDU parameters are altered in eyes with manifest hyperopia than emmetropia. This may result in changes of ocular hemodynamics as clinically described in patients with AMD. Particularly, increased RI suggested the possibility that increased choroidal vascular resistance may be associated with the pathological angiogenesis in the affected eye.

References

1. Lens, Al. Optics, retinoscopy, and refractometry. Ledford JK, Daniels K, Campbell R, editors. 2nd ed. USA. SLACK Incorporated; 2006:18-9.
2. Guthoff R, Berger RW, Draeger J. Ultrasonographic measurement of the posterior coats of the eye and their relation to axial length. *Graefes Arch Clin Exp Ophthalmol* 1987;225(5):374-6.
3. Strang NC, Schmid KL, Carney LG. Hyperopia is predominantly axial in nature. *Curr Eye Res* 1998;17(4):380-3.
4. Appiah AP, Trempe CL. Risk factors associated with branch vs. central retinal vein occlusion. *Ann Ophthalmol* 1989;21(4):153-5,157.
5. Sandberg MA, Tolentino MJ, Miller S, Berson EL, Gaudio AR. Hyperopia and neovascularization in age-related macular degeneration. *Ophthalmology* 1993;100(7):1009-13.
6. Williamson TH, Baxter GM, Dutton GN. Color Doppler velocimetry of the arterial vasculature of the optic nerve head and orbit. *Eye (Lond)* 1993;7 (Pt 1):74-9.
7. Belden CJ, Abbitt PL, Beadles KA. Color Doppler US of the orbit. *Radiographics* 1995;15(3):589-608.
8. Akyol N, Kükner AS, Ozdemir T, Esmerligil S. Choroidal and retinal blood flow changes in degenerative myopia. *Can J Ophthalmol* 1996;31(3):113-9.
9. Gutman FA. Evaluation of a patient with central retinal vein occlusion. *Ophthalmology* 1983;90(5):481-3.
10. Kir E, Tülin Berk A, Osman Saatci A, Kaynak S, Ergin MH. Axial length and hyperopia in eyes with retinal vein occlusions. *Int Ophthalmol* 1997-1998;21(4):209-11.
11. Friedman E. A hemodynamic model of the pathogenesis of age-related macular degeneration. *Am J Ophthalmol* 1997;124(5):677-82.
12. Kiel JW, Reiner AJ. Morphometric analysis of the choroid, Bruch's membrane, and retinal pigment epithelium in eyes with age-related macular degeneration. *Invest Ophthalmol Vis Sci* 1997;38(7):1290-2.
13. Berger JW, Fine SL, Maguire MG (eds). *Age-related macular Degeneration*. St. Louis: Mosby, 1999; xiii, pp 463.
14. Ikram MK, van Leeuwen R, Vingerling JR, Hofman A, de Jong PT. Relationship between refraction and prevalent as well as incident age-related maculopathy: The Rotterdam Study. *Invest Ophthalmol Vis Sci* 2003;44(9):3778-82.
15. Kremmer S, Zadow T, Steuhl KP, Selbach JM. Scanning laser polarimetry in myopic and hyperopic subjects. *Graefes Arch Clin Exp Ophthalmol* 2004;242(6):489-94.
16. Tanaka S. Eye fundus blood flow meter. *USP* 1997;5:963.
17. Evans DW, Harris A, Danis RP, Arend O, Martin BJ. Altered retrobulbar vascular reactivity in early diabetic retinopathy. *Br J Ophthalmol* 1997;81(4):279-82.
18. Güven D, Ozdemir H, Hasanreisoglu B. Hemodynamic alterations in diabetic retinopathy. *Ophthalmology* 1996;103(8):1245-9.
19. Dimitrova G, Tamaki Y, Kato S, Nagahara M. Retrobulbar circulation in myopic patients with or without myopic choroidal neovascularization. *Br J Ophthalmol* 2002;86(7):771-3.
20. Xu W, Grunwald JE, Metelitsina TI, DuPont JC, Ying GS, Martin ER, et al. Association of risk factors for choroidal neovascularization in age-related macular degeneration with decreased foveolar choroidal circulation. *Am J Ophthalmol* 2010;150(1):40-7.
21. Spektor S, Piontek E, Umansky F. Orbital venous drainage into the anterior cavernous sinus space: microanatomic relationships. *Neurosurgery* 1997;40(3):532-40.
22. Friedman E, Ivry M, Ebert E, Glynn R, Gragoudas E, Seddon J. Increased scleral rigidity and age-related macular degeneration. *Ophthalmology* 1989;96(1):104-8.
23. Spraul GW, Lang GE, Grossniklaus HE. Morphometric analysis of the choroid, Bruch's membrane, and retinal pigment epithelium in eyes with age-related macular degeneration. *Invest Ophthalmol Vis Sci* 1996;37(13):2724-35.