

# A Study on X-Linked Retinitis Pigmentosa and Its Molecular Diagnosis

Gholamreza Nourzad, PhD<sup>1</sup> • Mahnaz Baghershiroodi, MSc<sup>2</sup>

---

## Abstract

**Purpose:** Retinitis pigmentosa (RP) is a hereditary eye disease in human beings. It commences at childhood and continues by Nyctalopia and gradual reduction of visual field and ends up by blindness. It may be inherited in three forms of autosomal dominant, autosomal recessive and sex-linked. In this investigation we intend to study RP type as a sex-linked disease and its location on X chromosome.

**Case report:** Upon blood taking and extraction of DNA by the use of PCR method, it was possible to reproduce RPGR gene. Then the PCR product was subject to electrophoresis on Agarose Gel.

**Results:** The patient is a 12-year-old and blind boy with Ataxia. The diagnosis was RP3. We found a mutation in Exon No. 5 of RPGR gene related to regulating GTPase enzyme through which TCA code of Serine Amino Acid is replaced with TTA code of Aminoacid Lysine. As a result there will be a change in protein chain with further disorders in GTPase function.

**Conclusion:** The mutation in Exon No. 5 of RPGR gene causing a change in protein chain and disorders in GTPase function.

**Keywords:** X-Linked Retinitis Pigmentosa, RPGR Gene, RP3, Blindness, Nyctalopia

*Iranian Journal of Ophthalmology 2014;26(2):111-5 © 2014 by the Iranian Society of Ophthalmology*

---

## Introduction

Retinitis pigmentosa (RP; OMIM 268000) is the most common destructive retinal hereditary disease. X-linked retinitis pigmentosa type 3 (XLRP3) (MIM312610) stands out among other types of RP for several reasons.<sup>1</sup> Inheritance of RP can be autosomal dominant, autosomal recessive, X-linked, or in the rare cases taken as a digenic trait.<sup>2</sup> The prevalence of it is about one in 3,000 to 7,000 cases.<sup>3</sup> Since it is not related to any primary infections, its name changed into Retinopathia Pigmentosa. But the same similar primary name is used mostly. In case a

non-hereditary disorder resulting from medical intoxications such as, Phenothiazine or chloroquine causing some pigmentary changes of retina is called Pseudo RP.<sup>3</sup> Classic RP is accompanied with progressive Nyctalopia and reduction of peripheral visual field and progressively destruction of central sight area.<sup>3,4</sup> The disease is mostly obvious at young age or middle ages. Nyctalopia is usually the first sign of it. There is a gradual reduction in sight power and visual field caused by the destruction of cylindrical cells from the margin towards the center.

---

1. Associate Professor of Hormozgan University, Department of Biology, Bandar Abbas, Iran

2. Molecular Medicine of Research Center, Hormozgan University of Medical Sciences, Bandar Abbas, Iran

Received: May 6, 2014

Accepted: September 23, 2014

Correspondence to: Mahnaz Baghershiroodi, MSc

Molecular Medicine of Research Center, Hormozgan University of Medical Sciences, Bandar Abbas, Iran

Email: shiroodi33@yahoo.com

In other words, there is a start of tunnel vision and then progressive destruction of central cells as well. In dominant cases, both sexes may suffer from this disease. But in most sex-linked forms we have mostly males who may suffer as the dominant-linked. Sometimes it may appear with Ataxia (spinocerebral), mental retardation and behavioral disorders. Of course such signs may be due to the effect of muted gene type. Abnormal changes of electro-retinography may even start the clinical signs.<sup>4-7</sup> Retinal pigmentation is recognizable in all hereditary RP's which are different in different types of RP.<sup>3-6</sup> There are different reports about the frequency of X-linked type which indicate to 10% to 20% of cases of RP.<sup>4</sup> The major subtypes of XLRP is RP3, which accounts for six to 20% of all RP cases. Mutations in the RP3 gene, called RP GTPase Regulator (RPGR) causes a number of different retinopathies.<sup>8,9</sup> Major XLRP gene isolated in Xp21.1, RPGR, is composed of 19 exons encoding an ubiquitously expressed protein of 815 amino acids.<sup>10</sup> Two major isoforms of RPGR are detected in the retina: RPGR<sup>1-19</sup> (amino acids 815; exons 1-19) and RPGR<sup>1-ORF15</sup> (amino acid residues 1152; exons 1-15 and part of intron 15). The RPGR protein isoforms are prominently localized on the sensory cilia of photoreceptors (transition zone and basal bodies), human and monkey cochlea and to the nucleus, cilia and centrosomes of cultured cells.<sup>11</sup>

### Case report

We took 4cc blood for DNA extraction. Then extracts (0.5  $\mu$ l) were amplified in a 50  $\mu$ l reaction mixture containing PCR buffer (10 mM Tris-HCl, pH 8.3; 50 mM KCl, and 1.5 mM MgCl<sub>2</sub>), 200  $\mu$ M of each dNTP, 0.25  $\mu$ M of each primer (Table 1) and 1 unit of Taq polymerase (Pharmacia Biotech). The cycling conditions were initially started at 94° C for five minutes, followed by 30 cycles of denaturation at 94° C for one minute, annealing at 60° C for one minute, extension at 72° C for one minute, and a final extension step at 72° C for five minutes. We used DNA of a healthy person as the positive control and a negative one including reaction

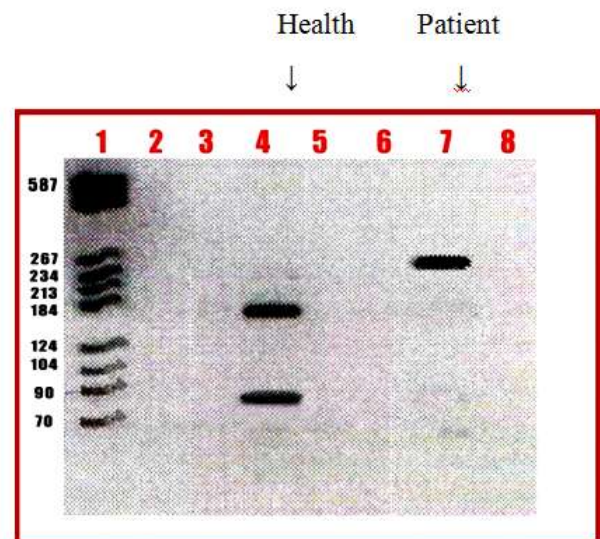
compositions of polymerase chain but without any DNA.

Restriction endonuclease analysis of the products was performed with PvuII (Boehringer Mannheim). Briefly, 30  $\mu$ l volumes of the amplified products were digested with 1  $\mu$ l of the restriction enzyme (PvuII, 10 U  $\mu$ l<sup>-1</sup>) at 37° C for 18 h. The DNA fragments from restriction endonuclease digestion were separated by electrophoresis (with SLV-Ladder, 8-587 bp, Roche) through a 2% agarose gel and visualized by ethidium bromide staining (Figure 1).

### DNA sequencing

PCR-amplified exon fragments were purified by the PCR product Extraction Kit (Quagene) and directly sequenced using an automated terminator fluorescent (Big dye terminator) sequencer. Primers for sequencing were the same as those for PCR. Each mutation was confirmed by a second PCR and sequencing in both directions.

The sequencing program cycling conditions were done by 25 cycles of denaturation at 94° C for 30 second, annealing at 50° C for 15 second, extension at 60° C for four minutes.



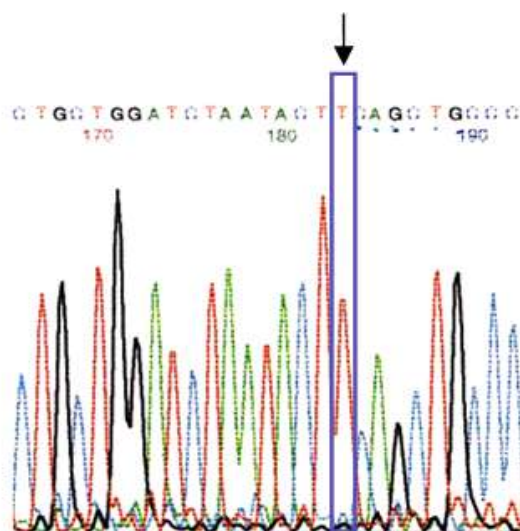
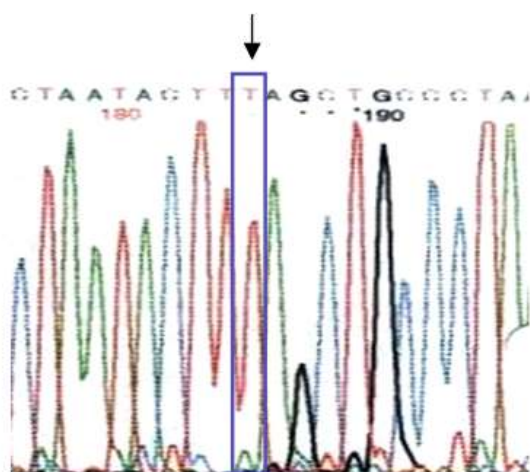
**Figure 1.** PvuII PCR-RFLP products on agarose gel 2%. Lane 1 is DNA Ladder SLV, Lane 4 showing the 90 and 170 bp DNA fragments (health), Lane 7 showing the undigested sample (patient).

**Table 1.** The required primers for Exone 5

Forward primer (5'→3')	Reverse primer (5'→3')	bp	°C
GTCTCATAAAAAGGGGGACTC	CAGGGAAAGGGAATGTGTCC	260	60

## Results

A 12-year-old boy being blind and having Ataxia had RP. He was investigated at the University Genetic Center. We found a mutation in Exon No. 5 of RPGR gene related to regulating GTPase enzyme (Figures 1, 2, and 3).

**Figure 2.** Image of natural cod TCA**Figure 3.** Image of mutation TTA Code in which we have specified a changed base T.

## Discussion

RP is a heterogenic disease with various genes and locus on various chromosomes (3, 4, 5, 6, 7, 12, 13, 8, 14, 15, 9) and X (XLRP). The most common situation of this disease in sex-linked type as the real goal of this research was related to a mutation in RPGR gene.<sup>7,8</sup> Most mutations are point types and related to four genes lead to non-syndromic RP.

These genes are related to Rhodopsin, Periforine  $\beta$ de, rom, rds and rod  $\alpha$ -GMP channel.<sup>4,12-15,25</sup> In case RP is accompanied with hearing reduction it would be named as Usher syndrome. RP is appeared with ophthalmoplegia, displasia ataxi and cardiac defect and ptosis in mitochondria disease Kern Sayre-Syndrome (Ragged-Red Fiber Myopathy). RP may appear with mental retardation, peripheral neuropathy, Ataxia, Acanthatic, RBCs (Spiked) in Abta Lipoproteinemia. The other conditions of RP are obvious in neuro-syphilis, Toxoplasmosis and also Refsum's diseases.

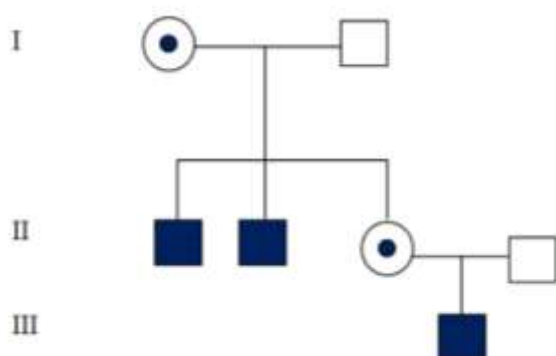
More than 20 different types of this disease have been recognized with little clinical differences up to now. From among them, there are two types of RP2 (XP11.2-11.3) with probable presence of a gene resulted from retinal dystrophy. The X-linked RP protein RP2 is a GTPase activating protein (GAP) for the small GTPase Arl3 and both proteins are implicated in the traffic of proteins to the primary cilia.<sup>16</sup> Type RP3 (XP21.1) as a sex-dependence is the most common type of retinal dystrophy for 10-15% of total patients. Since the cloning of the RPGR gene in 1996, a total of 77 mutations of the gene has been described. They are located in exons 1-8, 10, 11, 13-15 as well as some introns.<sup>17-22</sup> The major XLRP gene isolated in Xp21.1, RPGR, is composed of 19 exons encoding an ubiquitously expressed protein of 815 amino acids.<sup>23</sup>

What is attractive is reflection of vibrating and metallic beam with carriers (females). Those types of RP6 & RP8 are accompanied

with deafness. About 45 genes have been recognized up to now which their mutations may cause RP.<sup>10,24</sup> Therefore such a form variety with different appearances is really important in tribal groups and societies. RP3 gene has 2,784 nucleotides and 19 exons. The relevant mutation in concerned patient is related to exon No.5. This exon is made from 159 nucleotides through which in site 143 a C replaced with T (Serin→Leucin) (TCA-->TTA) (Figures 2, 3). As a result there will be a change in protein chain and some disorders in GTPase function.<sup>3,25,26,27</sup>

### Counseling

We considered three generations of a family who were worry about vision disorders of their 12-year-old son (Pedigree 1). According to the family pedigree IV/1, it was obvious that his mother has two brothers with III/1 & III/2 diseases. Since his father (III/4) has a mother's grandfather (II/2), both are healthy and also there were not any effects of vision disorders on syndrome or non-syndromic forms, therefore his disease was the result of a mutated gene in his mother's family. This assumption is really obvious because both his uncles are suffering from the same disease. This is specific because of his mother's uncle disease.



**Pedigree 1.** Pedigree of patients's family with x-linked RP3

What is necessary is recognition of disease and separated conditions of Refsum & Chorioidermy syndromes and other forms of retinal degenerations at childhood in compliance with special changes of eye depth physiology.<sup>3</sup> Premature recognition before appearance of disease and further findings and single forms of blinds by the help of

retinography are possible even prior to the start of clinical signs. Also any measurement of darkness acceptance is useful in recognition of disease. The hardest process of disease is obvious in autosomal forms of it. By the way we have central blindness in clear autosomal dominant heritage. In those forms of sex-based RP mostly we can recognize any carrier mothers through clinical recognitions and darkness acceptance and also special characteristics. The metallic lines and circular dark points surrounding the Macula may enable us to recognize it as well. It is possible to perform a heterozygote test in different families with autosomal recessive hereditary. Any recognition before birth and heterozygote are possible through genetic methods if the place and position of genes are available. Exact recognition of genetic defect is possible with DNA analysis. Different techniques like DNA-Chip & Protein-Chip are under establishment which will make quicker recognition accordingly.<sup>26</sup>

### Therapy

Hereditary retinal blindness is caused by mutations in genes expressed in photoreceptors or retinal pigment epithelium. There is no more fixed treatment for this disease. By the way both E & A vitamins (with 15,000 doses per day as an international unit for Vitamin A) have been used. After a 6-years research, Dr. Berson published an essay in U.S.A in 1993 in which it was proved that injection of 15000 IU (or 4.5 mg) of A-Palmitat vitamin may postpone the speed of reducing process of retina up to 10 years.<sup>24</sup> He has even tested the effect of Vitamin E. But the result was not positive. Retinal transplant and treatment with stem cells are under laboratory steps.<sup>7,25,28</sup> Gene therapy in mouse and dog models of a primary retinal pigment epithelium disease has already been translated to human clinical trials with encouraging results. After subretinal injections of adeno-associated virus-2/5-vectored human RPGR with human IRBP or GRK1 promoters, in vivo imaging showed preserved photoreceptor nuclei and inner/outer segments that were limited to treated areas. Both rod and cone photoreceptor function were greater in treated (three of four) than in control eyes.<sup>29</sup> Micro-system techniques should be replaced as the retina function prosthesis. Recently

scientists could return vision power by installation a sub-retinal link with resolution power of 1,500 diodes.<sup>5,13,15</sup> A special food regime free from phitanic acid may put a stop on retinopathy of Refsum Syndrome as a metabolic disorder.<sup>30</sup>

## References

1. Ferreira PA. Insights into X-linked retinitis pigmentosa type 3, allied diseases and underlying pathomechanisms. *Hum Mol Genet* 2005;14 Spec No. 2:R259-67.
2. Sheng X, Li Z, Zhang X, Wang J, Ren H, Sun Y, et al. A novel mutation in retinitis pigmentosa GTPase regulator gene with a distinctive retinitis pigmentosa phenotype in a Chinese family. *Mol Vis* 2010;16:1620-8.
3. Fujita R, Buraczynska M, Gieser L, Wu W, Forsythe P, Abrahamson M, et al. Analysis of the RPGR gene in 11 pedigrees with the retinitis pigmentosa type 3 genotype: paucity of mutations in the coding region but splice defects in two families. *Am J Hum Genet* 1997;61(3):571-80.
4. Andréasson S, Ponjavic V, Abrahamson M, Ehinger B, Wu W, Fujita R, et al. Phenotypic variations in X-linked retinitis pigmentosa. *Digital Journal of Ophthalmology* 1998;4(1).
5. Roepman R, van Duijnhoven G, Rosenberg T, Pinckers AJ, Bleeker-Wagemakers LM, Bergen AA, et al. Positional cloning of the gene for X-linked retinitis pigmentosa 3: homology with the guanine-nucleotide-exchange factor RCC1. *Hum Mol Genet* 1996;5(7):1035-41.
6. Berson EL, Jakobiec F, Albert D. Principles and practice of Ophthalmology. Hereditary retinal diseases. Retinitis pigmentosa and allied diseases 1995;106.
7. Miano MG, Testa F, Strazzullo M, Trujillo M, De Bernardo C, Grammatico B, et al. Mutation analysis of the RPGR gene reveals novel mutation in south European patients with X-linked retinitis pigmentosa. *Eur J Hum Genet* 1999;7(6):687-94.
8. Zitol I, Thiselton DL, Gorin MB, Stout JT, Plant C, Bird AC, et al. Identification of novel RPGR (retinitis pigmentosa GTPase regulator) mutation in a subset of X-linked retinitis pigmentosa families segregating with the RP3 locus. *Hum Genet* 1999;105(1-2):57-62.
9. Omoti AE. Hereditary atypical retinitis pigmentosa: case report. *Annals of African Medicine* 2005;4(2):88-90.
10. Daiger SP, Bowne SJ, Sullivan LS. Perspective on genes and mutations causing retinitis pigmentosa. *Arch Ophthalmol* 2007;125(2):151-8.
11. Ghosh AK, Murga-Zamalloa CA, Chan L, Hitchcock PF, Swaroop A, Khanna H. Human retinopathy-associated ciliary protein retinitis pigmentosa GTPase regulator mediates cilia-dependent vertebrate development. *Hum Mol Genet* 2010;19(1):90-8.
12. Zitol I, Morris A, Tyson P, Winship I, Sharp D, Gilbert D, et al. Sequence variation within the RPGR gene: evidence for a founder complex allele. *Hum Mutat* 2000;16(3):273-4.
13. Guevara-Fujita M, Fahrner S, Buraczynska K, Cook J, Wheaton D, Cortes F, et al. Five novel RPGR mutations in families with X-linked retinitis pigmentosa. *Hum Mutat* 2001;17(2):151.
14. Telander D, de Beus A, Small K. Retinitis pigmentosa. *eMedicine* 2007.
15. Alteheld N, Roessler G, Walter P. Towards the bionic eye--the retina implant: surgical, ophthalmological and histological and perspectives. *Acta Neurochir Suppl* 2007;97(Pt 2):487-93.
16. Beltran WA, Cideciyan AV, Lewin AS, Hauswirth WW, Jacobson SG, Aquirre GD, et al. Gene augmentation for X-linked retinitis pigmentosa caused by mutations in RPGR. *Cold Spring Harb Perspect Med* 2014. [Epub ahead of print]
17. Meindl A, Dry K, Herrmann K, Manson F, Ciccodicola A, Edgar A, et al. A gene (RPGR) with homology to the RCC1 guanine nucleotide exchange factor is mutated in X-linked retinitis pigmentosa (RP3). *Nat Genet* 1996;13(1):35-42.
18. Buraczynska M, Wu W, Fujita R, Buraczynska K, Phelps E, Andréasson S, et al. Spectrum of mutations in the RPGR gene that are identified in 20% of families with X-linked retinitis pigmentosa. *Am J Hum Genet* 1997;61(6):1287-92.
19. Shu X, Black GC, Rice JM, Hart-Holden N, Jones A, O'Grady A, et al. RPGR mutation analysis and disease: an update. *Hum Mutat* 2007;28(4):322-8.
20. Schwarz N, Novoselova TV, Wait R, Hardcastle AJ, Cheetham ME. The X-linked retinitis pigmentosa protein RP2 facilitates G protein traffic. *Hum Mol Genet* 2012;21(4):863-73.
21. Vervoort R, Lennon A, Bird AC, Tulloch B, Axton R, Miano MG, et al. Mutational hot spot within a new RPGR exon in X-linked retinitis pigmentosa. *Nat Genet* 2000;25(4):462-6.
22. Liu L, Chen H, Liu M, Jin L, Wei Y, Wu X, et al. Two novel mutations of the retinitis pigmentosa GTPase regulator gene in two Chinese families with X-linked retinitis pigmentosa. *Chin Med J (Engl)* 2002;115(6):833-6.
23. Hartong DT, Berson EL, Dryja TP. Retinitis pigmentosa. *Lancet* 2006;368(9549):1795-809.
24. Rush MG, Drivas G, D'Eustachio P. The small nuclear GTPase Ran: how much does it run? *Bioessays* 1996;18(2):103-12.
25. Meindl A, Carvalho MR, Herrmann K, Lorenz B, Achatz H, Lorenz B, et al. A gene (SRPX) encoding a sushi-repeat-containing protein is deleted in patients with X-linked retinitis pigmentosa. *Hum Mol Genet* 1995;4(12):2339-46.
26. Initial results of the pilot study: Chip enables blind people to gain impressions of vision. [http://www.bio-pro.de/magazin/wirtschaft/archiv\\_2008/index.html?lang=en&artikelid=/artikel/02094/index.html](http://www.bio-pro.de/magazin/wirtschaft/archiv_2008/index.html?lang=en&artikelid=/artikel/02094/index.html).
27. Hamel C. Retinitis pigmentosa. *Orphanet J Rare Dis* 2006;1:40.
28. Beltran WA, Cideciyan AV, Lewin AS, Iwabe S, Khanna H, Sumaroka A, et al. Gene therapy rescues photoreceptor blindness in dogs and paves the way for treating human X-linked retinitis pigmentosa. *Proc Natl Acad Sci U S A* 2012;7:109(6):2132-7.
29. Sandberg MA, Rosner B, Weigel-DiFranco C, McGee TL, Dryja TP, Berson EL. Disease course patients with autosomal recessive retinitis pigmentosa due to the USH2A gene. *Invest Ophthalmol Vis Sci* 2008;49(12):5532-9.
30. Goodwin P. Hereditary retinal disease. *Curr Opin Ophthalmol* 2008;19(3):255-62.