

Can OCT Pachymetry Identify Keratoconus Suspects?

Mostafa Mohammadian, MSc¹ • Hassan Hashemi, MD² • Ebrahim Jafarzadehpur, PhD³
Mahmoud Jabbarvand, MD⁴ • Ali Mirzajani, PhD⁵
AbbasAli Yekta, PhD⁶ • Mehdi Khabazkhoob, PhD⁷

Abstract

Purpose: Comparing the optical coherence tomography (OCT) pachymetry patterns in keratoconus suspect and normal people

Methods: Thirty-two keratoconus suspects and 36 healthy eyes were selected within the age range of 20-30 yrs. Their pachymetry pattern was obtained through OCT Visante in the minimum thickness spot, upper and lower corneal difference (I-S), lower temporal, and upper nasal thickness (IT-SN), withdrawal or non-withdrawal of the minimum thickness area of cornea from 0-2 central zone using the output map.

Results: In all measured parameters a significant difference was observed between the two groups ($p < 0.0001$). The Keratoconus suspects had a thinner cornea and showed more changes in corneal thickness than the normal group.

Conclusion: It seems that an OCT system of anterior segment can be utilized to assess patients prior to refractive surgery or Keratoconus screening, along with equipments such as Pentacam, and Orbscan.

Keywords: Optical Coherence Tomography, Keratoconus, Pachymetry

Iranian Journal of Ophthalmology 2014;26(4):189-92 © 2014 by the Iranian Society of Ophthalmology

Introduction

Early and valid detection of keratoconus is one of the most important challenges that vision sciences clinicians face.¹ Various criteria have been proposed for detecting Keratoconus.²⁻⁴ The most important criteria used for detecting keratoconus include corneal thickness in different areas of cornea,³ corneal maximal power,⁴ and changes in corneal power.⁵ The basis of many diagnostic

techniques of keratoconus is using the information on corneal thickness, and corneal curvature in keratoconus suspects and comparing them with norms of the society.

Some of the diagnostic techniques and equipments are more accurate in one or both of parameters of changes in corneal thickness or changes in corneal curvature.

-
1. MS Student in Optometry, Department of Optometry, Iran University of Medical Sciences, Tehran, Iran
 2. Professor of Ophthalmology, Noor Ophthalmology Research Center, Noor Eye Hospital, Tehran, Iran
 3. Professor of Optometry, Department of Optometry, Iran University of Medical Sciences, Tehran, Iran
 4. Professor of Ophthalmology, Eye Research Center, Farabi Eye Hospital, Tehran University of Medical Sciences, Tehran, Iran
 5. Associate Professor of Optometry, Department of Optometry, Iran University of Medical Sciences, Tehran, Iran
 6. Department of Optometry, School of Paramedical Sciences, Mashhad University of Medical Sciences, Mashhad, Iran
 7. Department of Epidemiology, Faculty of Public Health, Shahid Beheshti University of Medical Sciences, Tehran, Iran

Received: May 22, 2014

Accepted: September 25, 2014

Correspondence to: Ebrahim Jafarzadehpur, PhD

Professor of Optometry, Department of Optometry, Tehran University of Medical Sciences, Tehran, Iran

Email: ejafarzadehpur@tums.ac.ir

The regression curve of Pentacam machine presents the risk of afflicting to keratoconus based on the changes in the corneal thickness.⁶ In addition, in this machine, different parameters based on the changes in cornea curvature, analyze the conditions of afflicting to keratoconus.⁶ Some studies have shown that changes in corneal thickness may be a better indicator for predicting keratoconus.⁷ Hence, using equipments that can measure the cornea thickness with great precision, and which are able to measure different corneal area thicknesses, may be utilized in predicting keratoconus.

Optical coherence tomography (OCT) machine was initially used for retinal imaging.⁸ The development of this machine has greatly increased image resolution. Images recorded in the frequency domain were far faster than the ones recorded in time domain.⁹ More sophisticated OCT machines make posterior and anterior segments imaging possible. Two of the most widely used OCT machines for imaging the anterior and posterior segments are Visante and Optovue. Therefore, using the obtained information from OCT on corneal thickness in its different regions may help predict keratoconus risk. The present study tries to investigate this theory using Visante OCT.

Methods

In the present study, people who referred to Farabi Hospital to perform refractive surgery underwent precise and complete examination of anterior segment. At first, a specific optometrist conducted the basic vision and refraction examination. These initial examinations included visual acuity, computer refraction with and without pupillary dilation, retinoscopy with and without dilation, monitoring the patient previous glasses' score, keratometry, pachymetry, and assessment with Pentacam. The participants were selected based on the results, and considering the admission criteria (age range between 20 and 30, absence of any irregular astigmatism, and scissors movement in retinoscopy, absence of eye operation history, or any aggressive intervention, certified or

classified by a specialist under healthy or keratoconus suspect category, corrected vision of $10/10$ or better in each eye) normal findings assign the subjects in normal group. In addition, specialist ophthalmologist's comments with regard to the eyes' health or possibility of surgery, or their being suspicious to keratoconus. Therefore corneal specialist assigned KCN suspects according to the Pentacam finding, refraction and Rabinowits criteria. The referred people were OCT examined by Visante machine (Carl Zeiss, Germany). The OCT operator was kept unaware of the purpose of the study and conducted the OCT based on the standard protocol. A technician did the OCT via Visante machine and the pachymetry maps were obtained. Through the pachymetry maps, the following variables were measured (Figure 1):

- Measurement of the degree of mean difference of lower segment of central cornea in the scope out of 2 central millimeters with its symmetric area in the upper cornea (I-S Value),
- Measurement of the difference between lower segment and the upper temporal segment, and nasal segment in the scope out of 2 mm (IT-SN Value),
- Determining the minimum corneal thickness,
- Determining whether the minimum thickness part of cornea is out of the 2-mm area or not (MINIMUMOUTSIDE2 MM Diameter)

The above-mentioned parameters were measured and recorded for the referred patients on specific forms. The obtained results through descriptive statistics were categorized and classified. An independent t-test was used to compare the recorded results of the two groups.

Ethical issues

The Ethics Committee of Iran University of Medical Sciences approved the study protocol, which was conducted in accord with the tenets of the Helsinki Declaration. All participants signed a written informed consent.

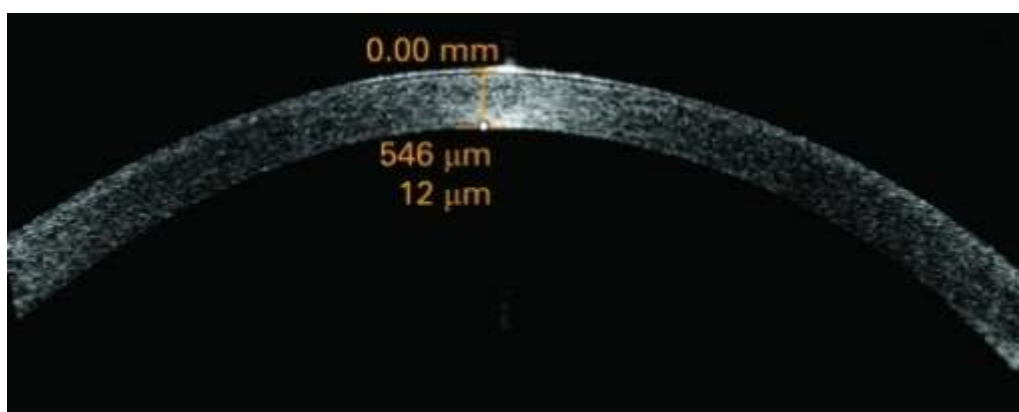


Figure 1. Pachymetry maps of optical coherence tomography by Visante machine

Results

Thirty-two keratoconus suspect eyes and 36 normal eyes were studied and examined in this investigation. The results related to both groups are presented in table 1.

According to the results, in 19.4% of the healthy normal people, the minimum thickness

area of cornea was located outside the 2 mm from the center of cornea, while in the keratoconus suspects, in 50% of the cases, the minimum thickness area of cornea is outside the 2 mm area.

Table 1. Comparison of mean and standard deviation of measured parameters in two groups

	Min thickness (mean±SD)	IT-SN (mean±SD)	I-S (mean±SD)
Keratoconus suspects	491.06±29.6	25.47±11.8	20.09±11
Normal	533.69±27.5	13.31±7.7	10.08±8.2
p-value<	0.0001	0.0001	0.0001

Discussion

As shown in table 1, statistically significant differences are observed in all measured parameters in the keratoconus suspect group, and the normal group ($p < 0.0001$). In addition, the frequency of the minimum thickness of cornea outside the 2 mm area is higher among keratoconus suspect group (50%) than normal group (19.4%). These results emphasize two important clinical issues. First, the examination of corneal thickness in the minimum thickness area, difference of thickness between the upper and lower area outside 2 central mm (I-S), besides, the difference between lower segment and temporal segment (IT), as well a nasal segment (SN) outside central 2 mm area (IT-SN Value) can be a good indicator to predict keratoconus. Second, it seems that the OCT Visante machine can prove to be an appropriate equipment to assess keratoconus suspect patients. These findings are in line

with other studies,¹⁰ which were done on patients with evident keratoconus. The importance of our study lies in the fact that distinguishing keratoconus suspects can be of greater clinical importance. Li et al.'s study clearly showed the correlation of KISA parameter (Keratometry, I-S, Astigmatism, and Skew percentage [KISA%]) in these patients and presented quantitative topographic results.¹⁰ These results indicate that OCT pachymetry can be a diagnostic indicator for keratoconus.

Using OCT in frequency domain prepares the grounds for improving image resolution, as well as pachymetry image quality.¹¹ Improved resolution of OCT machines can naturally provide us with more accurate and precise information of corneal thickness.¹¹ The present study has used the OCT machine utilized in pachymetry in frequency domain.

Other studies conducted on keratoconus suspect patients, normal people, and people with refractory surgery background, have shown that the results obtained from the pachymetry pattern by OCT, have presented much more precise and accurate results compared to Scheimpflug pachymetry.¹² Pentacam machine is probably one of the most important equipments that can contribute to early detection of keratoconus, and distinguish keratoconus suspects. This machine can present information on corneal thickness and keratoconus risk through Scheimpflug imaging.⁶ However, Propsero et al's study has shown that not only are not the diagnostic capability of OCT is less, but also OCT results seem to have more accuracy.¹² In addition, OCT results have proved to have appropriate reliability.¹²

Considering the frequency of keratoconus in Iranians population,¹³ it seems that screening and detecting keratoconus afflicted patients needs further and intense attention. Considering the existence of a range of machines and equipments to predict, detect, and diagnose keratoconus suspects, OCT, considering its merits, can be utilized in this case. It is also suggested that OCT machines that are able to measure corneal curvature be used for this purpose.¹⁴

Conclusion

Anterior OCT may be useful pachymetry device for evaluation of some cornea pathologies such as KCN. It can be used for KCN suspected patients. However, OCT may be recommended for confirming Pentacam finding or as indicator for considering more inspections for KCN detections.

References

1. Sugar J, Macsai MS. What causes keratoconus? *Cornea* 2012;31(6):716-9.
2. Rabinowitz YS, Rasheed K. KISA% index: a quantitative videokeratography algorithm embodying minimal topographic criteria for diagnosing Keratoconus. *J Cataract Refract Surg* 1999;25(10):1327-35.
3. Prakash G, Agarwal A, Mazhari AI, Kumar G, Desai P, Kumar DA, et al. A new, pachymetry-based approach for diagnostic cutoffs for normal, suspect and keratoconic cornea. *Eye (Lond)* 2012;26(5):650-7.
4. Piñero DP, Nieto JC, Lopez-Miguel A. Characterization of corneal structure in keratoconus. *J Cataract Refract Surg* 2012;38(12):2167-83.
5. Tummanapalli SS, Maseedupally V, Mandathara P, Rathi VM, Sangwan VS. Evaluation of corneal elevation and thickness indices in pellucid marginal degeneration and keratoconus. *J Cataract Refract Surg* 2013;39(1):56-65.
6. Uçakhan ÖÖ, Cetinkor V, Özkan M, Kanpolat A. Evaluation of Scheimpflug imaging parameters in subclinical keratoconus, keratoconus, and normal eyes. *J Cataract Refract Surg* 2011;37(6):1116-24.
7. Ahmadi Hosseini SM, Mohidin N, Abolbashari F, Mohd-Ali B, Santhirathelagan CT. Corneal thickness and volume in subclinical and clinical keratoconus. *Int Ophthalmol* 2013;33(2):139-45.
8. Stanga PE, Bird AC. Optical coherence tomography (OCT): principles of operation, technology, indications in vitreoretinal imaging and interpretation of results. *Int Ophthalmol* 2001;23(4-6):191-7.
9. Sung KR, Kim JS, Wollstein G, Folio L, Kook MS, Schuman JS. Imaging of the retinal nerve fibre layer with spectral domain optical coherence tomography for glaucoma diagnosis. *Br J Ophthalmol* 2011;95(7):909-14.
10. Li Y, Meisler DM, Tang M, Lu AT, Thakrar V, Reiser BJ, et al. Keratoconus diagnosis with optical coherence tomography pachymetry mapping. *Ophthalmology* 2008;115(12):2159-66.
11. Li Y, Tan O, Brass R, Weiss JL, Huang D. Corneal epithelial thickness mapping by Fourier-domain optical coherence tomography in normal and keratoconic eyes. *Ophthalmology* 2012;119(12):2425-33.
12. Prospero Ponce CM, Rocha KM, Smith SD, Krueger RR. Central and peripheral corneal thickness measured with optical coherence tomography, Scheimpflug imaging, and ultrasound pachymetry in normal, Keratoconus-suspect, and post-laser in situ keratomileusis eyes. *J Cataract Refract Surg* 2009;35(6):1055-62.
13. Ziaei H, Jafarinasab MR, Javadi MA, Karimian F, Poorsalman H, Mahdavi M, et al. Epidemiology of Keratoconus in an Iranian population. *Cornea* 2012;31(9):1044-7.
14. Kim E, Ehrmann K, Choo J, Franz S, Moilanen J. The effect of inlay implantation on corneal thickness and radius of curvature in rabbit eyes. *Cornea* 2013;32(5):e106-12.