

Bilateral Microphthalmos Associated with Papillomacular Fold, Severe Hyperopia and Steep Cornea

Mojtaba Abrishami, MD¹ • Alireza Maleki, MD²
Ali Hamidian-Shoormasti, MD³ • Mostafa Abrishami, MD⁴

Abstract

Purpose: To report a young patient with microphthalmos associated with bilateral papillomacular fold and severe hyperopia

Case report: In this observational case report, a sixteen-year-old young man was referred with high hyperopia to Al-Zahra Eye Hospital, Zahedan University of Medical Sciences, Zahedan, Iran, for check up. Spherical error in right eye (RE) was +14.75 D and in the left eye (LE) was +15.00 D without astigmatism. Keratometry was reported 51.50, 52.25@113 in RE and 51.25, 52.25@65 in LE. Best corrected visual acuity (BCVA) was ²⁰/₂₅ in both eyes. Axial length in RE was 14.8 mm and 14.9 mm in LE. Also cornea diameter measured 9.9 for both eyes. In fundus exam, a papillomacular retinal fold extending from the center of the fovea toward the optic nerve head was present. In OCT exam, papillomacular fold with thickness of 322 microns in RE and 277 microns in LE were reported. In Pentacam exam, anterior chamber depth, central corneal thickness and anterior and posterior best fit sphere (BFS) were reported 2.34 mm, 565 microns, 6.54 mm and 5.39 mm in RE and 2.41 mm, 578 microns, 6.54 mm and 5.39 mm in LE. Intraocular pressure (IOP) was 13 mmHg in both eyes and there was no sign of angle closure glaucoma.

Conclusion: Microphthalmos may be associated with high hypermetropia, thick papillomacular fold, and steep cornea with a relative good vision.

Keywords: Microphthalmos, Papillomacular Fold, Hyperopia

Iranian Journal of Ophthalmology 2014;26(4):223-7 © 2014 by the Iranian Society of Ophthalmology

-
1. Assistant Professor of Ophthalmology, Eye Research Center, Farabi Eye Hospital, Tehran University of Medical Sciences, Tehran, Iran
 2. Assistant Professor of Ophthalmology, Al-Zahra Eye Center, Zahedan University of Medical Sciences, Zahedan, Iran
 3. Resident in Ophthalmology, Al-Zahra Eye Center, Zahedan University of Medical Sciences, Zahedan, Iran
 4. Eye Research Center, Mashhad University of Medical Sciences, Mashhad, Iran

Received: December 14, 2014

Accepted: March 11, 2015

Correspondence to: *Mojtaba Abrishami, MD*

Assistant Professor of Ophthalmology, Eye Research Center, Farabi Eye Hospital, Tehran University of Medical Sciences, Tehran, Iran
Email: *mojtaba_abrishami@yahoo.com*

Financial disclosure: No author has a financial or proprietary interest in any material or method mentioned.

Introduction

Microphthalmos defined as presence of a small eye within the orbit due to a developmental arrest. Microphthalmos has been classified into simple (absence of major ocular malformations) and complex (with ocular abnormalities).¹ In patients with microphthalmos, there is usually foreshortening of both the anterior and posterior segments of the eye. Refraction is high hyperopia, and the cornea is small.²

Posterior microphthalmos is a rare type of microphthalmos that describes a reduced axial length along with normal corneal diameter, resulting in high hyperopia and a papillomacular retinal fold.³ These features are also present in nanophthalmos,⁴ which is described as an eye with microphthalmos, microcornea, shallow anterior chamber, relatively large lens/globe volume ratio, thickened sclera, and tendency toward uveal effusion.³ The potential for visual development in microphthalmic patients is dependent upon retinal development and other ocular characteristics.² Microphthalmic patients may experience normal or near normal vision if early evaluation and diagnosis, close follow-up, and appropriate management are performed to improve or maintain visual function in such patients.²

Here we aim to report a patient with symmetric high hyperopia, short axial length and reduced anterior segment dimensions like microcornea and short anterior-chamber

depth and also retinal fold but with steep cornea, and with preserved visual acuity.

Case report

A sixteen-year-old young man was referred with high hyperopia for checkup. Spherical error in right eye (RE) was +14.75 D and in the left eye (LE) was +15.00 D without astigmatism. Keratometry was reported 51.50, 52.25@113 in RE and 51.25, 52.25@65 in LE. Ocular motility was full and orthophoric. Pupils were equally reactive to light and accommodation and no afferent pupillary defect were present. Best corrected visual acuity (BCVA) was $20/25$ in both eyes. Axial length was reduced (14.8 mm RE and 14.9 mm LE) and corneal diameter was 9.9 mm in both eyes. The posterior segment examinations revealed bilateral elevated horizontal papillomacular retinal fold without subretinal fluid in the macula (Figure 1). Optical coherence tomography was consistent with the clinical examination and showed papillomacular fold with thickness of 322 microns in RE and 277 microns in LE (Figure 2). In Pentacam exam, anterior chamber depth, central corneal thickness and anterior and posterior best fit sphere (BFS) were reported 2.34 mm, 565 microns, 6.54 mm and 5.39 mm in RE (Figure 3) and 2.41 mm, 578 microns, 6.54 mm and 5.39 mm in LE (Figure 4). Intraocular pressure (IOP) was 13 mmHg in both eyes and there was no sign of angle closure glaucoma in gonioscopy.

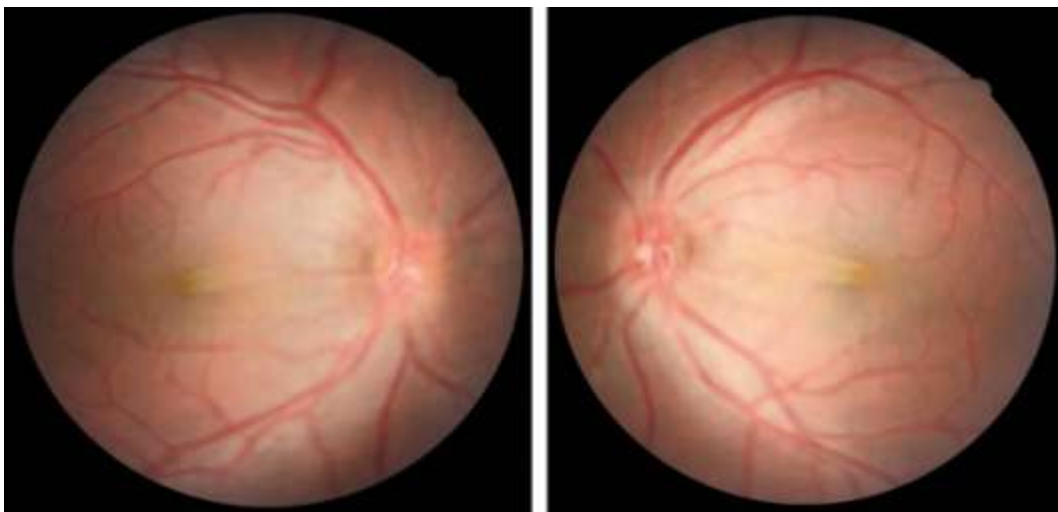


Figure 1. Right and left fundus photos of the patient showing the papillomacular retinal fold

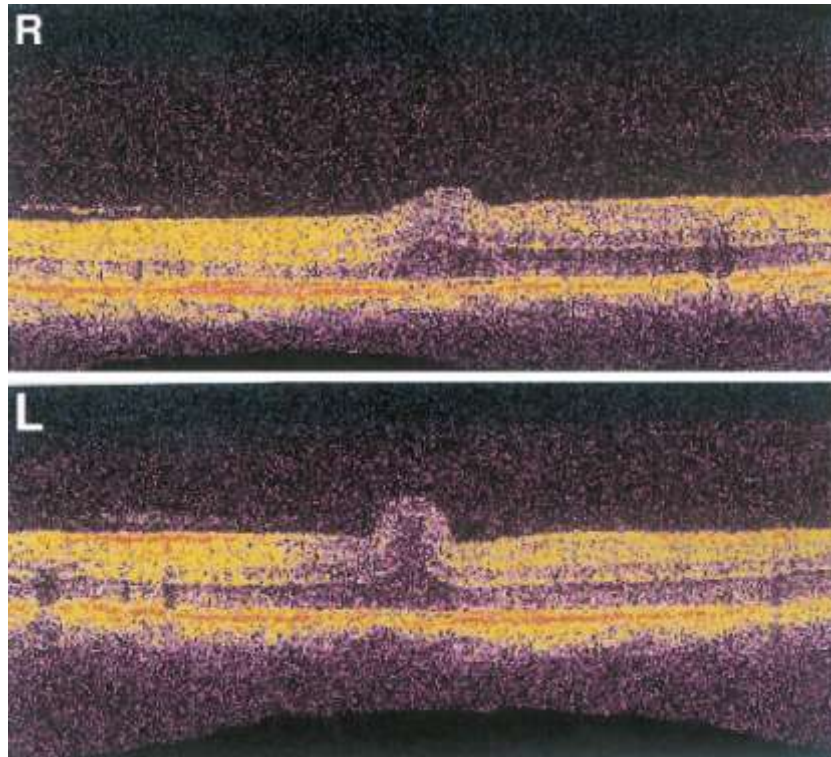


Figure 2. Right and left OCT of the macula

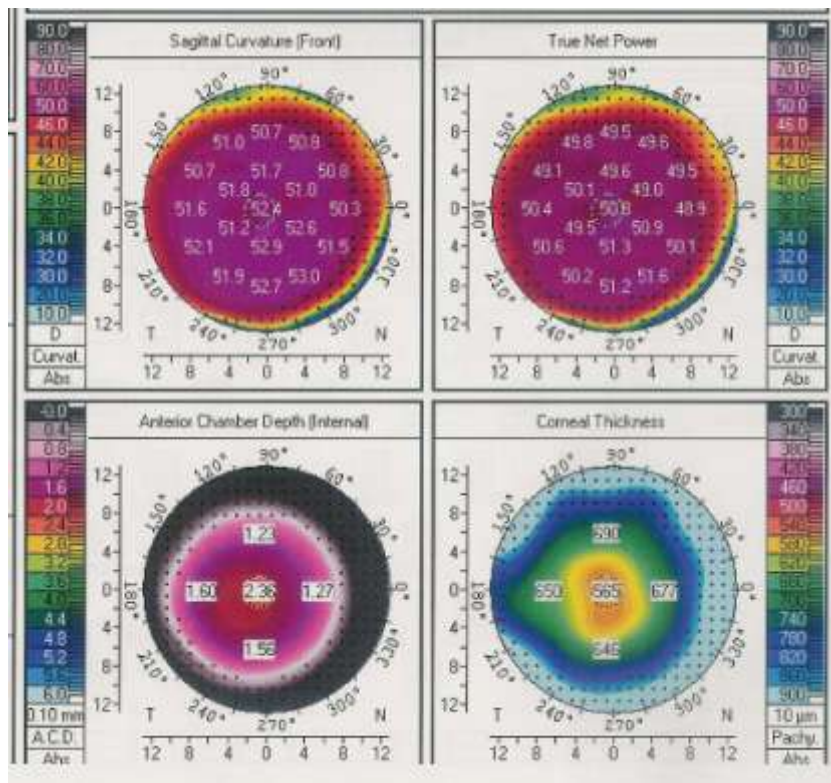


Figure 3. Pentacam report of the right eye

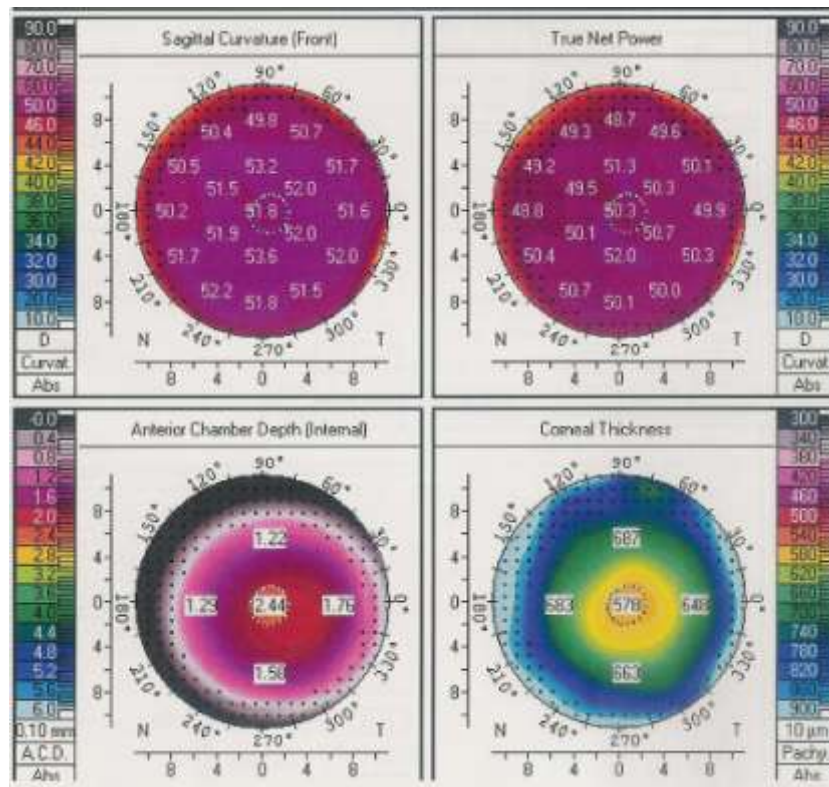


Figure 4. Pentacam report of the left eye

Discussion

Hereby we report a patient showing a very short axial length with also small corneal diameter and short anterior chamber depth which is combined with steep cornea and thick papillomacular fold with a relative good vision.

In microphthalmia axial length is two standard deviations below the mean value standardized for age; this typically is below 21 mm in adult human eyes.² Nanophthalmos is defined as axial length less than 18 mm, and at least 8 D hypermetropia.¹ So we can consider our case as a nanophthalmic eye. In contrast with microphthalmia which is a fairly common ocular malformation, nonophthalmos is a very rare form, and most cases of nanophthalmos are sporadic.⁵ Microphthalmos, and also nanophthalmos are typically associated with microcornea in which the cornea is relatively flat.⁶ In the sporadic reports dealing with very small eyes (partly synonymous with nanophthalmos), there is only occasional information about refractive components and ocular size parameters.⁷ In a report by Fledelius, oculometric features of extreme hyperopia in two Faroese families found and 25% in the first family and 70% of

the affected eye in another family had a corneal curvature radius of less than 7.1 mm and 15 had a short posterior segment with a thick eye wall and a relatively thick lens. Also steep and small corneas were present.⁷ Spitznas in five cases regarded as posterior microphthalmos; reported curvature radii of 6.6 to 7.1 mm.⁸ Khairallah et al. reported a mean value of 7.1 mm as a corneal curvature in 18 eyes of 10 siblings from five different families and eight sporadic cases with posterior microphthalmos.² In three brothers with nanophthalmic small eyes, corneal curvature ranged from 6.82 to 7.24 mm.⁹

As Fledelius suggested, shallow anterior chambers and thick lenses in the very short eyes are in keeping with the general trends as valid for the short eye tail of the population. Combined with the steep corneas, refractively these anterior segment features may be considered a useful adaptation to the shortened eye. Without such additional myopic power, the extreme hypermetropia in the very short eyes would be even higher. Developmentally, however, we should recall

that the cornea finds its final shape long before the posterior segment.¹

Conclusion

The exact feature of corneal curvature radius in short axial length microphthalmos cannot be determined by this report, but it may add more information about keratometry data and refractive components in very short eyes.

References

1. Verma AS, Fitzpatrick DR. Anophthalmia and microphthalmia. *Orphanet J Rare Dis* 2007;2:47.
2. Khairallah M, Messaoud R, Zaouali S, Ben Yahia S, Ladjimi A, Jenzri S. Posterior segment changes associated with posterior microphthalmos. *Ophthalmology* 2002;109(3):569-74.
3. Kim JW, Boes DA, Kinyoun JL. Optical coherence tomography of bilateral posterior microphthalmos with papillomacular fold and novel features of retinoschisis and dialysis. *Am J Ophthalmol* 2004;138(3):480-1.
4. Nowilaty SR, Mousa A, Ghazi NG. The posterior pole and papillomacular fold in posterior microphthalmos: novel spectral-domain optical coherence tomography findings. *Ophthalmology* 2013;120(8):1656-64.
5. Parish RK. Chapter 33: Nanophthalmos, relative anterior microphthalmos, and axial hyperopia. In: Steinert RF, Chang DF. *Cataract surgery*, Saunders, China, 3rd edition, 2009.
6. American Academy of Ophthalmology. *Basic and Clinical Science Course. Section 8: External Disease and Cornea*. San Francisco: American Academy of Ophthalmology; 2011-2012.
7. Fledelius HC, Fuchs HJ, Rosenberg T. Oculometric characteristics of extreme hypermetropia in two faroes families. *Optom Vis Sci* 2004;81(10):762-8.
8. Spitznas M, Gerke E, Bateman JB. Hereditary posterior microphthalmos with papillomacular fold and high hyperopia. *Arch Ophthalmol* 1983;101(3):413-7.
9. Ryan EA, Zwaan J, Chylack LT Jr. Nanophthalmos with uveal effusion: clinical and embryologic considerations. *Ophthalmology* 1982;89(9):1013-7.