

Effects of Memantine on Visual Functions after Scleral Buckling for Retinal Detachment

Mohammad Riazi Esfahani, MD^{1,2} • Mahsa Khakbaz, MD³ • Zahra Aalami Harandi, MD¹
Ali Abdollahi, MD⁴ • Sasan Moghimi, MD¹ • Morteza Movassat, MD¹

Abstract

Purpose: Evaluating the effects of memantine on visual function after scleral buckling for rhegmatogenous retinal detachment (RRD)

Methods: In a Double blind prospective randomized clinical trial, 61 patients with clinical diagnosis of less than 4 weeks macula-off RRD who had successful scleral buckle surgery had been selected and divided into two randomized groups. Thirty of them received 5 mg/day memantine orally for first week and 10 mg/day for two weeks, while the others (31 patients) received placebo. Best corrected visual acuity (BCVA), macular thickness measured by optical coherence tomography (OCT) and contrast sensitivity test, were measured for all patients at one and three months. Multifocal electroretinography (ERG) was performed for all patients who returned to us at third month postoperatively.

Results: Mean BCVA was 0.74 ± 0.27 logMAR in memantine group versus 0.77 ± 0.21 logMAR in placebo group at one month, and improved respectively to 0.64 ± 0.25 logMAR versus 0.69 ± 0.26 logMAR in memantine and placebo groups. There wasn't significant difference in first month and third month BCVA between two groups. Mean central macular thickness in memantine group was significantly lower than placebo group 215 ± 41 μ m versus 262 ± 101 μ m at first month, respectively and this difference was also significant after three months 204 ± 39 μ m versus 249 ± 57 μ m. Nineteen of 61 patients (31.4%) had persistent subretinal fluid (SRF) at first month (12 of them were in placebo group). P1 wave amplitude of multifocal ERG in $10-15^\circ$ and $>15^\circ$ of central fovea in memantine group were significantly higher than placebo group.

Conclusion: Memantine using as an adjuvant to reattachment surgery may have neuroprotective effects which can rehabilitate the function of macula in RRD patients.

Keywords: Retinal Detachment, Neuroprotection, Scleral Buckling, Optical Coherence Tomography, Multifocal Electroretinography

Iranian Journal of Ophthalmology 2011;23(2):3-10 © 2011 by the Iranian Society of Ophthalmology

1. Associate Professor of Ophthalmology, Eye Research Center, Farabi Eye Hospital, Tehran University of Medical Sciences, Tehran, Iran
2. Noor Ophthalmology Research Center, Noor Eye Hospital, Tehran, Iran
3. Ophthalmologist, Eye Research Center, Farabi Eye Hospital, Tehran University of Medical Sciences, Tehran, Iran
4. Professor of Ophthalmology, Eye Research Center, Farabi Eye Hospital, Tehran University of Medical Sciences, Tehran, Iran

Received: May 27, 2010

Accepted: February 14, 2011

Correspondence to: Zahra Aalami Harandi, MD

Associate Professor of Ophthalmology, Eye Research Center, Farabi Eye Hospital, Tehran University of Medical Sciences, Tehran, Iran, Tel:+98 21 55414941-6, Email: riazifahimi@yahoo.com

None of the authors have any financial/conflicting interests to disclose.

ACTR number: 12609000111279

Introduction

Rhegmatogenous retinal detachment (RRD) is separation of sensory retina from RPE (retinal pigmented epithelium) due to a retinal break and the main part of RRD treatment is closing of break via surgery.^{1,2} Although anatomical retinal reattachment will be gained in almost 90% of patients but because of photoreceptors degeneration, functional improvement won't be accessible in some cases; so a good postoperative visual outcome specially in macula-off RRD patients is an unseemly goal.¹

If macula is off, only 33% to 50% of patients will attain to vision of $20/50$. If the duration of macular detachment (DMD) is less than one week, 75% of patients will gain $20/70$ or better vision postoperatively which decreases to 50% if the duration of RRD is between 1-8 weeks.¹ Henrich and his coworkers have shown that visual recovery was better the earlier the patients underwent surgical repair, but statistically significant results were found only for patients operated after four days from the beginning of the symptoms.³ In another study, Wakabashi has shown that integrity of photoreceptor layer shown on OCT may account for visual restoration in patients with macula-off RRD.⁴

Our knowledge about RRD's neuropathology in experimental models allows us to find out more information about receptors and mediators and gives us more insight about pharmacologic interventions.^{5,6}

We know that detached retina has severe anoxia.⁶ In postmortem CNS or anoxia condition, the principle excitatory neurotransmitter, glutamate, accumulates and causes neurotoxicity and neural cell death.⁷ Glutamate level in vitreous of RRD patients increases significantly compared with controls.⁸ Chronic low doses of glutamate is toxic for retinal ganglion cells; as intravitreal injection of glutamate has killed 42% of the retinal ganglion cells (RGCs) after 3 months.⁹

Memantine is an uncompetitive N-methyl-D-aspartate (NMDA) antagonist which has FDA-approval for moderate to severe Alzheimer's disease.^{10,11} This neuroprotective agent blocks only excessive activity of NMDA-receptor without disrupting normal NMDA activity.¹⁰

Recently, there were some evidences about efficacy of memantine for NAION visual

function,¹² but there is no study about the role of memantine in retinal detachment.

Therefore, we designed a randomized clinical trial to evaluate its effects on visual function following scleral buckling for RRD.

Methods

This study is a prospective double blind randomized clinical trial.

All included eyes had a primary less than four weeks macula-off RRD and visual acuity (VA) of $20/200$ or less. Eyes with proliferative vitreoretinopathy (PVR) of grade C or more, any other macular pathology (such as macular hole or scar), signs of long standing RRD (demarcation line, retinal cysts), renal failure, pregnant and nursing women, and history of using digoxin, dexamethorphan, barbiturates, amantadine and hydrochlorothiazide were excluded. Also cases with failed scleral buckling or redetachment up to 3 months hadn't been entered in our study.

Either spong 505 or encircling band was implanted based on surgical preference. Cryopexy and subretinal fluid (SRF) drainage was performed if needed. The patients were followed for at least three months. Best corrected visual acuity (BCVA) testing, slit-lamp examination, thorough fundus exam, IOP measurement, OCT imaging, visual evoked potentials (VEP), and contrast sensitivity testing were performed in different time points in all of the patients.

For randomizing, we paid attention to the DMD. So, we had two subgroups of patients: 1) Eyes with DMD of less than 2 weeks, 2) Eyes with DMD of more than 2 weeks. In each subgroups we used random blocks to choose the type of treatment (drug versus placebo).

After getting consent, we administered 5 mg/day memantine for the first week beginning just after operation and continued the drug for other two weeks with the dose of 10 mg/day. Follow-up was continued for 1 month and 3 months after surgery. Memantine tablets were placed in capsular coats exactly the same as placebo capsules (150 mg lactose-filled). Capsular coats disappear immediately after entering to stomach and doesn't seem to interfere with drug absorption.

Pre and postoperative BCVA was recorded by ETDRS chart and recorded as LogMAR.

Optical coherence tomography (OCT) (Stratus 3 Carl Zeiss ophthalmic system) was performed in all patients at first month postoperatively to evaluate central macular thickness and persistent SRF. In the case of persistent SRF, we would repeat it at third month postoperatively.

Contrast sensitivity test was done by B-VAT II (Mentor manitor) at three meters distance. The patients were asked if they could see the gradings in 4.8, 7.5, 12 and 15 cycles per degree of spatial frequencies. The lowest contrast which patient could detect, was recorded as contrast threshold.^{25,26}

To assess macular function, at third month, we used multifocal electroretinography (ERG) (Metrovision, France) via m-sequence stimulation technique with 60 local ERG signals in a central visual field. It was done with dilated pupil by using Burian-Allen contact lens electrodes after 15 minutes of light adaptation.

Data were analyzed by using SPSS 15 software. χ^2 test was used for comparing qualitative variables and student T-test was used for comparing quantitative variables.

Results

Scleral buckling was performed in 75 eyes of 75 patients. Fourteen patients were excluded later because of macular hole (2 eyes), missed to follow-up (3 eyes), redetachment within one month (8 eyes) and severe IOP rise (1 eye). Finally, 61 patients (61 eyes) entered the study (30 in memantine group and 31 in placebo group).

Patients' characteristics are shown on table 1.

Preoperative mean VA was 1.86 ± 0.52 logMAR in memantine group and 2.08 ± 0.53 logMAR in placebo group ($p=0.11$).

Mean VA on first month was 0.74 ± 0.27 logMAR in memantine group and 0.77 ± 0.21 logMAR in placebo group ($p=0.98$). After three months mean VA was 0.64 ± 0.25 logMAR in memantine group and 0.69 ± 0.26 logMAR in placebo group. There was significant difference between preoperative and postoperative VA in both groups ($p=0.001$ after 1 month, $p=0.002$ after 3 months).

Mean VA comparing between the two groups based on preoperative VA and age, didn't show significant difference at first ($P=0.98$) and also at third month ($P=0.72$) of follow-up (Figure 1).

In subgroup analysis, we divided the patients regarding to VA into three groups:

- 1) ≤ 0.5 logMAR
- 2) 0.5-1 logMAR
- 3) ≥ 1 logMAR

At first month, nine patients (14.8%) had vision of 0.5 logMAR or better. Among them six patients (66.6%) were in memantine group. Among nine patients with vision of 1 logMAR and worse, only three were in the memantine group. At third month, VA of 14 patients (25.9%) was 0.5 logMAR or better and 6 of them were in memantine group. There was not any significant difference in VA-subgroups between memantine and placebo groups.

Central macular thickness on OCT was significantly lower in memantine group than placebo group ($P=0.02$) at one month. Third month macular thickness on OCT also showed statistically significant difference between the two groups ($P=0.02$) as seen in table 2.

The incidence of persistent SRF on OCT was 31.14% (19 of 61 patients) in first month.

Among the eyes with SRF, only one eye didn't undergo SRF drainage during surgery.

Seven of 30 eyes (23.3%) of memantine group and 12 of 31 eyes of placebo group (38.7%) had subretinal fluid at first month. Memantine group had trend into lower incidence of persistent SRF but there was not statistical difference between the two groups ($P=0.27$, fisher exact test).

Contrast sensitivity on spatial frequency of 4.8 cpd showed significant difference between the two groups on third month ($P=0.05$), but in other frequencies there were no significant improvement in contrast sensitivity in memantine group in first and third month (Figure 2).

In multifocal ERG examination, amplitude of p1 wave (p1 peak + N1 trough) in 10-15° of central fovea and in >15° central fovea, was shown to be significantly greater in memantine group than placebo group ($P=0.04$ and $P=0.009$ respectively) (Table 3).

Table 1. Demographic information shows approximately similar situations before drug administration for two groups (A=placebo, B=memantine)

Variables	n=31 (A)	n=30 (B)	P
Age	55.45±15 y	41.70±15.3 y	0.001
Gender (M)	17 (54%)	23 (76%)	0.07
Laterality OD/OS	16/15	12/18	0.36
History of trauma (+)	5 (16.12%)	8 (26.7%)	0.31
Breaks number (>1)	9 (29%)	8 (26.7%)	0.56
Quadrants of RD (>2 quadrant)	13 (41.9%)	12 (40%)	0.87
Duration of symptoms (>2 weeks)	10 (32.2%)	13 (43.3%)	0.37
Lens status (phakic)	26 (83.8%)	28 (93.3%)	0.36
Surgery			
SRF drainage (+)	27 (87%)	27 (90%)	0.72
Cryopexy (+)	28 (90.3%)	28 (93.3%)	0.66
Sponge (+)	25 (80%)	24 (80%)	0.94
Refractive error			
Plano/astigmatism	15 (48.3%)	10 (33.3%)	0.38
Myopia < 6 Diopter	6 (19.3%)	7 (23.3%)	0.64
Hyperopic	4 (12.9%)	5 (16.6%)	0.57
Myopia ≥ 6 Diopter	6 (19.3%)	8 (26.6%)	0.43

Table 2. Mean of central macular thickness and it's volume in two groups at one month and three months after operation (A=placebo, B=memantine)

	1 month			3 months		
	Group A	Group B	P	Group A	Group B	P
Macular thickness (µm)	101±262	41±215	0.02	58±249	39±204	0.02
Macular volume (mm ³)	1.65±7.58	1.19±7.08	0.19	1.19±7.52	0.74±7.16	0.30

Table 3. Means of P1 wave amplitude of multifocal ERG in two groups at different distances shown by degrees from centre of fovea (A=placebo, B=memantine)

	Mean P1 Amplitude (nV/deg) Group A	Mean P1 Amplitude (nV/deg) Group B	P
< 2 deg	59.33±35.16	63.89±31.83	0.61
2-5 deg	55.83±22.36	63.64 ±19.91	0.17
5-10 deg	43.37±18.54	52.26±16.68	0.06
10-15 deg	35.04±12.92	42.80±14.73	0.04
> 15 deg	28.42±10.37	36.98±13.15	0.009

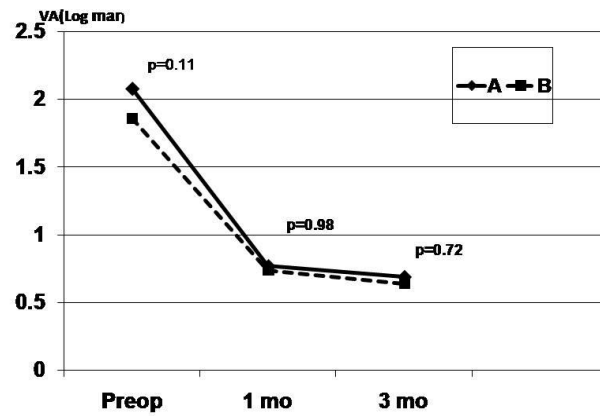


Figure 1. Comparison of preoperative best corrected visual acuity with first and third month best corrected visual acuity between memantine group (B) and placebo group (A)

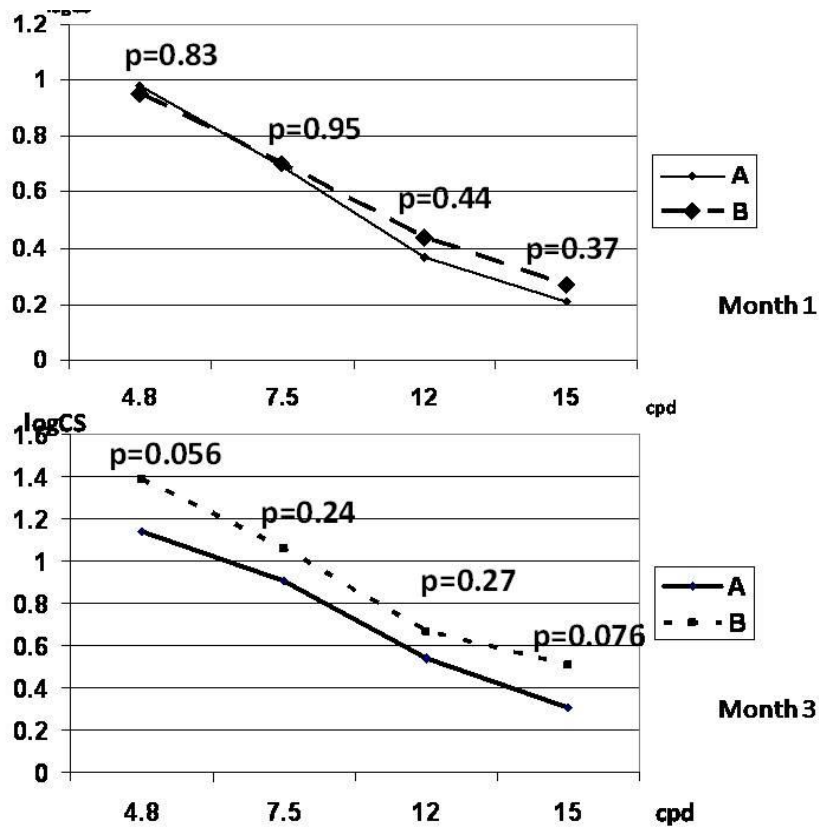


Figure 2. Comparing C.S in frequencies of 4.8, 7.5, 12 and 15 between memantine (B) and placebo (A) groups in first and third month

Discussion

Memantine has been prescribed as an approved neuroprotective drug in Alzheimer's disease and has been used successfully for Parkinson,¹³ NAION¹² and experimental glaucoma.¹⁴⁻¹⁶ Previous studies also revealed safety of memantine.^{14,15} The neuroprotective effects of memantine (1, amino, 3-5 di methyl adamantine) is through glutamate NMDA receptor blockage which inhibits glutamate-associated intracellular calcium accumulation and therefore prevents apoptosis.¹⁰

In a study dexamethorphan (NMDA antagonist) was used in experimental RRD rabbits and showed that decline of b wave amplitude in ERG was more significant in placebo group and concluded beneficial effects of neuroprotective agents in ischemic damages due to detached retina.¹⁷

We have evaluated memantine effects on visual function of operated RRD patients for the first time. Although postoperative BCVA improved significantly compared with preoperative values in both groups, there was no significant difference between the two groups. One of the most important variables which affects visual outcome after scleral buckling, is DMD.¹⁸ However, our patients were selected with less than four weeks macular detachment and distribution of those with less than 2 weeks was approximately similar between the two groups.

Our patients' overall visual rehabilitation was worse than other studies i.e. 25.9% of our patients with less than 4 Weeks DMD gained vision of $20/70$ (0.5 logMAR or better). Also our relatively short-term follow-up can affect the visual acuity results in the two groups.¹

It has been shown that RRD patients with thicker outer nuclear layer in OCT have worse visual outcome than thinner ones.¹⁹ In our study, macular thickness in memantine group was significantly less than placebo group at both first and third month postoperatively. This decrease of macular edema was compatible with recovery in multifocal ERG results, in memantine group. There was marginally significant relation between third month recovery of macular thickness and p1 wave amplitude in >15 degree central fovea (P=0.06). However, in our study, BCVA didn't have a significant difference between the two groups. One reason might be that functional macular recovery might have delay compared

with its structural or electrophysiologic recovery.

Neuroprotective effects on damaged optic nerve ganglion cells have been demonstrated in several studies.^{12,20} Morphologic changes of optic nerve by confocal scanning laser in rabbit model of experimental optic nerve ischemia, has shown no increasing cup in memantine group.²⁰ Also Aalami et al in a human model case series of NAION considered that memantine may have beneficial effects on BCVA, perimetry and VEP.¹²

In a study on visual outcome and macular thickness after scleral buckling or pars plana vitrectomy for RRD, the mean VA was 0.32 logMAR postoperatively. This study also showed normal macular thickness in 60% of patients on first month after RRD reattachment surgery.²¹ This result is compatible with our study's result which 56% of patients had a normal macular thickness (less than 225 μ m) who significantly were in memantine group (P=0.04).

SRF bleb incidence in the macula have been reported up to 9.3% in a study after successful scleral buckling, which was seen until 8.7 ± 5.5 weeks after complete reattachment.²²

In our study the placebo patients had twice likelihood of persistent diffuse SRF in comparison with memantine group. Thus memantine might be effective in decreasing the incidence of persistent SRF after successful scleral buckling. The underlying causes for effects of memantine on reduction of SRF and central macular thickness is not well understood but it may be the result of more viable retinal pigment epithelial cells and more powerful pumps for SRF absorption.

The importance of contrast sensitivity in improvement of vision associated quality of life was indicated in a study after successful reattachment of retina in RRD patients. Visual quality of life was not related to VA before surgery, age, break numbers and quadrants of detachment. Although postoperative VA was in normal limits, but quality of life was related to contrast sensitivity drop out.²³ Our results showed that contrast sensitivity in frequency of 4.8 cpd improved in memantine group three months after scleral buckling. It is known that contrast sensitivity with frequency of 2-6 cpd

is enhanced by retina-brain processing system. Receptor fields, on-off systems, and lateral inhibition are different processes responsible for such enhancement. Some of these mechanisms may be involved by occurrence of RRD and our results show that memantine could help to restore some of these mechanisms after scleral buckling.²⁴

The multifocal ERG will show local topographic information of cone responses. The distribution pattern of mERG activity is the same as pattern of visual field defect.²⁵ Hare indicated that memantine had suitable effect on RGC function in ocular hypertension, measured by multifocal ERG and VEP. The multifocal ERG wave amplitudes had strong relation with RGC loss in experimental glaucoma.¹⁴ Gong showed significant improvement of a and b waves mean amplitude at first month after scleral buckling surgery.²⁶ Our study also showed the same results in P1 amplitude at central 10-15° and >15° of fovea by using memantine after three months.

Some complications have been reported with systemic use of memantine in vascular dementia such as mild dizziness and

occasionally restlessness on higher (40 mg/day) doses.²⁷ None of our patients showed these complications.

There were some limitations in our study. We had a relatively short term follow-up for our patients, and so we could not evaluate long-term effects of memantine on our patients. Moreover, small sample size might lead to smaller subgroups that made analyses difficult. Also, we didn't evaluate quality of life in our patients, and the importance of changes in contrast sensitivity could not be detected. Finally, there was a significant difference in age between 2 groups which could have some effect on results.

Conclusion

In summary, our study showed that using memantine might help us to resolve retinal damage due to RRD, improve contrast sensitivity, and increase amplitudes of multifocal ERG. Although BCVA might not improve significantly, frequency of SRF might be lower after memantine prescription. Finally further studies will be required with longer follow-up and larger sample size to confirm this hypothesis.

References

1. Hilton GF, McLean JB, Brinton DA. Retinal detachment: principles and practice. 2nd ed. Ophthalmology Monograph 1. San Francisco, CA: American Academy of Ophthalmology, 1995.
2. Lewis GP, Charteris DG, Sethi CS, et al. The ability of rapid retinal reattachment to stop or reverse the cellular and molecular events initiated by detachment. *Invest Ophthalmol Vis Sci* 2002;43(7):2412-20.
3. Henrich PB, Priglinger S, Klaessen D, et al. Macula-off retinal detachment--a matter of time? *Klin Monbl Augenheilkd* 2009;226(4):289-93.
4. Wakabayashi T, Oshima Y, Fujimoto H, et al. Foveal microstructure and visual acuity after retinal detachment repair: imaging analysis by Fourier-domain optical coherence tomography. *Ophthalmology* 2009;116(3):519-28.
5. Lewis GP, Charteris DG, Sethi CS, Fisher SK. Animal models of retinal detachment and reattachment: identifying cellular events that may affect visual recovery. *Eye* 2002;16(4):375-87.
6. Kubay OV, Charteris DG, Newland HS, Raymond GL. Retinal detachment neuropathology and potential strategies for neuroprotection. *Surv Ophthalmol* 2005;50(5):463-75.
7. Rothman SM, Olney JW. Glutamate and the pathophysiology of hypoxic--ischemic brain damage. *Ann Neurol* 1986;19(2):105-11.
8. Diederer RM, La Heij EC, Deutz NE, et al. Increased glutamate levels in the vitreous of patients with retinal detachment. *Exp Eye Res* 2006;83(1):45-50.
9. Vorwerk CK, Lipton SA, Zurakowski D, et al. Chronic low-dose glutamate is toxic to retinal ganglion cells. Toxicity blocked by memantine. *Invest Ophthalmol Vis Sci* 1996;37(8):1618-24.

10. Lipton SA. Possible role for memantine in protecting retinal ganglion cells from glaucomatous damage. *Surv Ophthalmol* 2003;48 Suppl 1:S38-46.
11. Lipton SA. Paradigm shift in NMDA receptor antagonist drug development: molecular mechanism of uncompetitive inhibition by memantine in the treatment of Alzheimer's disease and other neurologic disorders. *J Alzheimers Dis* 2004;6(6 Suppl):S61-74.
12. Aalami-Harandi Z, Gholami A, Riazi-Esfahani M. Efficacy of memantine in acute nonarteritic ischemic optic neuropathy. *Iranian Journal of Ophthalmology* 2008;20(3):39-44.
13. Zdanys K, Tampi RR. A systemic review of off-label uses of memantine for psychiatric disorders. *Prog Neuropsychopharmacol Biol Psychiatry* 2008;32(6):1362-74.
14. Hare WA, WoldeMussie E, Lai RK, et al. Efficacy and safety of memantine treatment for reduction of changes associated with experimental glaucoma in monkey, I: Functional measures. *Invest Ophthalmol Vis Sci* 2004;45(8):2625-39.
15. Hare WA, WoldeMussie E, Weinreb RN, et al. Efficacy and safety of memantine treatment for reduction of changes associated with experimental glaucoma in monkey, II: Structural measures. *Invest Ophthalmol Vis Sci* 2004;45(8):2640-51.
16. Lagrèze WA, Knörle R, Bach M, Feuerstein TJ. Memantine is neuroprotective in a rat model of pressure-induced retinal ischemia. *Invest Ophthalmol Vis Sci* 1998;39(6):1063-6.
17. Gotoh T. [Dextromethorphan maintains the function of the detached retina]. *Nippon Ganka Gakkai Zasshi* 1995;99(10):1145-50.
18. Yang CH, Lin HY, Huang JS, et al. Visual outcome in primary macula-off rhegmatogenous retinal detachment treated with scleral buckling. *J Formos Med Assoc* 2004;103(3):212-7.
19. Maruko I, Iida T, Sekiryu T, Saito M. Morphologic changes in the outer layer of the detached retina in rhegmatogenous retinal detachment and central serous chorioretinopathy. *Am J Ophthalmol* 2009;147(3):489-494.
20. Kim TW, Kim DM, Park KH, Kim H. Neuroprotective effect of memantine in a rabbit model of optic nerve ischemia. *Korean J Ophthalmol* 2002;16(1):1-7.
21. Lecleire-Collet A, Muraine M, Menard JF, Brasseur G. Predictive visual outcome after macula-off retinal detachment surgery using optical coherence tomography. *Retina* 2005;25(1):44-53.
22. Kang SW, Kim JH, Shin WJ, Kim JI. Subretinal fluid bleb after successful scleral buckling and cryotherapy for retinal detachment. *Am J Ophthalmol* 2008;146(2):205-210.
23. Okamoto F, Okamoto Y, Hiraoka T, Oshika T. Vision-related quality of life and visual function after retinal detachment surgery. *Am J Ophthalmol* 2008;146(1):85-90.
24. Mainster MA. Contemporary optics and ocular pathology. *Surv Ophthalmol* 1978;23(2):135-42.
25. Kretschmann U. Clinical applications of multifocal electroretinography. *Doc Ophthalmol* 2000;100(2-3):99-113.
26. Gong Y, Wu X, Sun X, et al. Electroretinogram changes after scleral buckling surgery of retinal detachment. *Doc Ophthalmol* 2008;117(2):103-9.
27. Orgogozo JM, Rigaud AS, Stöfler A, et al. Efficacy and safety of memantine in patients with mild to moderate vascular dementia: a randomized, placebo-controlled trial (MMM 300). *Stroke* 2002;33(7):1834-9.