

Orbital Doppler Evaluation of Blood Flow Velocities in Optic Neuritis

Mehdi Karami, MD¹ • Mohsen Janghorbani, PhD²
Alireza Dehghani, MD³ • Maryam Riahinejad, MD⁴

Abstract

Purpose: To evaluate orbital blood flow velocities and optic nerve diameter with Doppler and gray-scale sonography in patients with acute unilateral optic neuritis (ON)

Methods: Orbital Doppler and gray-scale sonography was performed in 46 eyes of 23 patients aged 19-47 with acute unilateral ON. ON was diagnosed by an ophthalmologist on the basis of clinical presentation, presence of decreased visual acuity (VA) and assessment of visual evoked potentials (VEP). The peak systolic (PSV) and end-diastolic (EDV) blood flow velocities and resistance and pulsatile indices (RI, PI) of the ophthalmic artery (OA), central retinal and posterior ciliary arteries (CRA, PCAs) and optic nerve diameter were measured in both eyes. We compared results from affected and unaffected eyes using the paired T-test. The area under the receiver-operating characteristic (ROC) curves was used to assess diagnosis of ON on the basis of measured blood flow parameters of the OA, CRA and PCAs and optic nerve diameter.

Results: Optic nerve diameter in eyes with ON was significantly higher than that of the control eyes ($P < 0.001$). The mean (SD) optic nerve diameter was 4.1 (0.8) mm in affected eyes and 3.0 (0.4) mm in unaffected eyes ($P < 0.001$). There were no differences in average PSV, EDV, RI and PI of OA and CRA between affected and unaffected eyes ($P > 0.05$). The mean RI in the PCAs ($P < 0.05$) was slightly lower in the eyes with ON than in the contralateral eyes. The area under the ROC curves was 0.928 for optic nerve diameter.

Conclusion: Optic nerve diameter was related to ON, but orbital blood flow parameters were not.

Keywords: Blood Flow Parameters, Doppler Sonography, Ophthalmic Artery, Optic Nerve Diameter, Optic Neuritis

Iranian Journal of Ophthalmology 2011;23(2):11-18 © 2011 by the Iranian Society of Ophthalmology

1. Assistant Professor of Radiology, Department of Radiology, School of Medicine, Isfahan University of Medical Sciences, Isfahan, Iran
2. Professor of Epidemiology, Department of Epidemiology and Biostatistics, School of Public Health, Isfahan University of Medical Sciences, Isfahan, Iran
3. Assistant Professor of Ophthalmology, Department of Ophthalmology, Feiz Hospital, Isfahan University of Medical Sciences, Isfahan, Iran
4. Resident in Radiology, Department of Radiology, School of Medicine, Isfahan University of Medical Sciences, Isfahan, Iran

Received: January 6, 2011

Accepted: May 26, 2011

Correspondence to: *Mohsen Janghorbani, PhD*
Professor of Epidemiology, Department of Epidemiology and Biostatistics, School of Public Health, Isfahan University of Medical Sciences, Isfahan, Iran, Tel:+98 311 2334893, Email: janghorbani@yahoo.com

Introduction

Optic neuritis (ON), an immune-mediated inflammatory disorder of the optic nerve, causes loss of vision usually due to the swelling and destruction of the myelin sheath around the optic nerve. It is characterized by sudden partial or complete loss of vision, dyschromatopsia, pain with or without optic disc swelling, and afferent pupillary defect in asymmetric or unilateral cases.

It has been suggested that various vascular factors may be involved in the pathogenesis of ON.¹⁻⁷ Nerve sheath thickening and inflammatory processes may cause changes in blood flow velocity and resistance in orbital vessels. There have also been conflicting reports of impaired hemodynamics in the orbital vessels in patients with ON.^{4,5,7-11} In some studies orbital blood flow velocities were increased^{4,5,7,11}; whereas in others remained unchanged^{8,10} or even decreased.^{9,12} Accurate assessment of orbital blood flow is critical in understanding the dysregulation that occurs during ON.

Blood to the optic nerve is mainly supplied by the ophthalmic artery (OA) via the central retinal artery (CRA) and posterior ciliary arteries (PCAs), both of which divide into multiple branches. The CRA originates in the OA and enters the optic nerve around 7.5 mm behind the ocular bulb. The PCAs are also supplied with blood by the OA and they divide into multiple branches to supply the pial arteries. These arteries have a diameter of around 0.2 mm and form the pial network that adheres to the optic sheath, and also contributes to the vascularization of the optic nerve.¹³

Colour Doppler imaging (CDI) is one of the most widely used and well-established technique for assessing ocular blood flow velocities in the retrobulbar vessels. This is a noninvasive, painless imaging method with highly reproducible procedures. Estimation of orbital blood flow velocity from CDI of the OA, CRA and PCAs is a technique that offers great potential in this field.¹⁴

Given the conflicting results in previous studies, we examined a group of patients with unilateral ON and compared the values for orbital blood flow velocity, resistance index (RI), pulsatile index (PI) and optic nerve diameter in the affected eye with those for the

unaffected eyes using colour Doppler and gray-scale sonography.

Methods

Twenty-three previously untreated consecutive patients with acute unilateral ON were recruited from the ophthalmology outpatient clinics of Isfahan University of Medical Sciences, Iran, between October 2009 and February 2010. These included 4 men and 19 women, with a mean (SD) age of 27.2 (7.0) year, ranging from 19-47 years. The inclusion criterion was typical clinical presentation of acute unilateral ON before the age of 50 years, and exclusion criteria were bilateral ON, recurrent ON and any disease or anomaly of the fellow eye. Pregnant or nursing women were also excluded. No patient had a history of any major systemic diseases, including cardiovascular disease, arterial hypertension, hyperlipidemia, and diabetes mellitus. All patients underwent neurologic and ophthalmologic examination, including assessment of visual acuity (VA), direct ophthalmoscopy, and measurement of visual evoked potentials (VEP).

Ascertainment of optic neuritis

ON was diagnosed by an expert ophthalmologist (AD). Cases of acute unilateral ON were identified according to the degree of decrease in VA, impaired perimetry findings, slight swelling of the optic disc and facultative retro- or parabolbar pain, afferent pupillary defect and delayed VEP responses. The contralateral eye of all patients was unaffected by clinical signs of ON before the study began. However, we cannot exclude the possibility that subclinical damage to the contralateral optic nerve may have occurred, although the VEPs in these eyes were normal. Multiple sclerosis (MS) was presumed to be the cause of ON in 18 patients with no obvious cause in the remaining five.

The best corrected visual acuity (BCVA) of the affected eyes varied from counting fingers to $20/20$; and the BCVA of unaffected eyes was at least $20/20$ in all cases. The systolic and diastolic blood pressure measured during blood flow velocity investigations did not exceed values of 130 mmHg and 85 mmHg, respectively. Estimation of intrabulbar pressure did not exceed 18.3 mmHg.

Sonography

Orbital Doppler and gray-scale sonography was performed within 1-7 days of presentation, before initiation of treatment with corticosteroids. CDI of the eye was performed in all individuals by two expert sonographers (MK and MR) using a color Doppler unit and a 7.5-10 MHz linear-array transducer (model G-60; Siemens, Germany). The nerve diameter was measured on both sides, with the unaffected nerve serving as a control. A difference in nerve diameter of 0.3 mm or more, compared with the contralateral side, was defined as a sign of nerve thickening.¹⁵ The sonographers were blinded to the side of involvement of each patient. The patients were examined in the supine position in order to avoid any pressure on the eye. Sterile coupling gel was applied to closed eyelids, with examiner's hand resting on the orbital margin to minimize pressure on the globe, and real-time gray-scale and color-flow images were obtained.¹⁶ Both orbits of all patients were examined. We obtained peak systolic (PSV) and end-diastolic (EDV) velocities measurements in the OA, CRA and PCAs of both orbits and used these to calculate the vascular resistance (expressed by the RI and PI) using the formula $RI = (PSV - EDV) / PSV$ ¹⁷ and PI using the formula $PI = (PSC - EDV) / V_{mean}$, where $V_{mean} = 1/3(PSV - EDV) + EDV$ ¹⁸, in all patients. Signals from short PCAs can be located in the lateral and medial sections of an eyeball and as numerous branches of short PCAs were available for assessment, only the medial branch was chosen for analysis in this study.

The tenets of the Declaration of Helsinki were followed, institutional ethics committee approval was obtained, patients were informed about the Doppler method; and an informed consent form was signed by each participant.

Statistical analysis

On the basis of an estimated standard deviation of 1.5; and accounting for pairwise comparisons, we calculated that 23 patients would be required to provide the study with 80 percent power to detect (with a two-sided alpha of 0.05) a mean difference in optic nerve diameter of 1.0 mm. Comparisons between PSV, EDV, RI and PI obtained from the OA, CRA and PCAs and optic nerve diameter in

the orbit with ON and the contralateral orbit without ON were calculated with a paired Student's T-test. The ability of optic nerve diameter, PSV, EDV, RI and PI to diagnose ON was examined by receiver-operating characteristic (ROC) curve and the respective areas under the curve, in which sensitivity is plotted as a function of 1-specificity. Areas under the ROC curves were compared by the algorithm developed by DeLong et al.¹⁹ The analyses were undertaken on a PC using SPSS version 18 for Windows (SPSS Inc., Chicago, IL, USA). All tests for statistical significance were two-tailed, and performed assuming a type I error probability of <0.05.

Results

ON involved the right eye in 12 patients (52.2%) and the left eye in the remaining 11 (47.8%). Of the 23 eyes with ON, 20 (86.9%) showed a thickening of the affected optic nerve. Only 3 eyes with ON displayed a difference in nerve diameter of less than 0.3 mm. The increase in diameter of the affected nerve compared with the unaffected contralateral nerve averaged (SD) 1.1 (0.6) mm (range 0.1-2.2 mm). When a cut-off value for nerve pathology was set at a nerve diameter of ≥ 4 mm, 15 (65.2%) of the affected nerves and 100% of the unaffected nerves were correctly assessed. The means (SD) values of parameters obtained from CDI measurements in the OA, CRA, PCAs and optic nerve in the 23 pairs of eyes with and without ON are shown in Table 1. As expected, those eyes with ON had higher mean optic nerve diameter. The mean (SD) optic nerve diameter was 4.1 (0.8) mm for eyes with ON and 3.0 (0.4) mm for eyes without ON ($P < 0.001$). There were no statistically significant differences between eyes with and without ON in PSV, EDV, RI and PI in OA and CRA. The mean RI in the PCAs was slightly lower in eyes with ON than in control eyes ($P < 0.05$).

The areas under the ROC curves for the occurrence of ON for orbital blood flow velocities and resistance indices of OA, CRA, PCAs and optic nerve diameter are shown in figure 1 and table 2. The area under the ROC curve was 0.928 (95% CI: 0.843, 0.101) for optic nerve diameter.

Table 1. Means (SD) of characteristics obtained in the ophthalmic, central retinal, posterior ciliary arteries and optic nerve in 23 pairs of eyes with and without optic neuritis

Variables	With optic neuritis	Without optic neuritis	Difference (95% CI)
Optic nerve diameter (mm)	4.1 (0.8)	3.0 (0.4)	1.1 (0.83, 1.39)**
Ophthalmic artery			
Peak systolic velocity (cm/second)	31.09 (13.1)	32.07 (16.8)	-0.98 (-8.8, 6.8)
End-diastolic velocity (cm/second)	11.52 (15.1)	10.98 (14.1)	0.54 (-1.7, 2.8)
Resistance index	0.74 (0.09)	0.73 (0.09)	0.01 (-0.03, 0.05)
Pulsatile index	1.72 (0.6)	1.88 (0.7)	-0.16 (-0.5, 0.2)
Central Retinal Artery			
Peak systolic velocity (cm/second)	13.48 (6.7)	12.56 (3.6)	0.92 (-2.11, 3.96)
End-diastolic velocity (cm/second)	5.26 (3.8)	4.77 (4.7)	0.49 (-0.98, 1.94)
Resistance index	0.66 (0.08)	0.69 (0.07)	-0.03 (-0.07, 0.01)
Pulsatile index	1.30 (0.4)	1.25 (0.3)	0.05 (-0.20, 0.31)
Posterior ciliary artery			
Peak systolic velocity (cm/second)	16.27 (6.51)	18.69 (8.80)	-2.42 (-7.34, 2.48)
End-diastolic velocity (cm/second)	8.32 (4.89)	8.03 (10.00)	0.29 (-2.91, 3.48)
Resistance index	0.60 (0.08)	0.64 (0.07)	-0.4 (-0.07, -0.004)*
Pulsatile index	1.02 (0.34)	1.06 (0.24)	-0.04 (-0.023, 0.15)

The difference in the mean of the variables between optic neuritis and no optic neuritis.

*: P<0.05

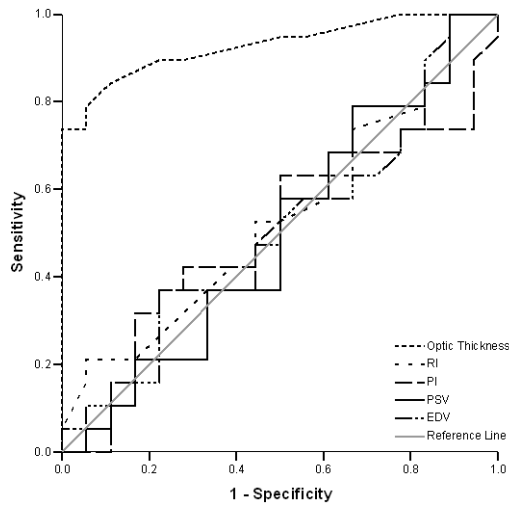
** : P<0.001

CI: Confidence interval

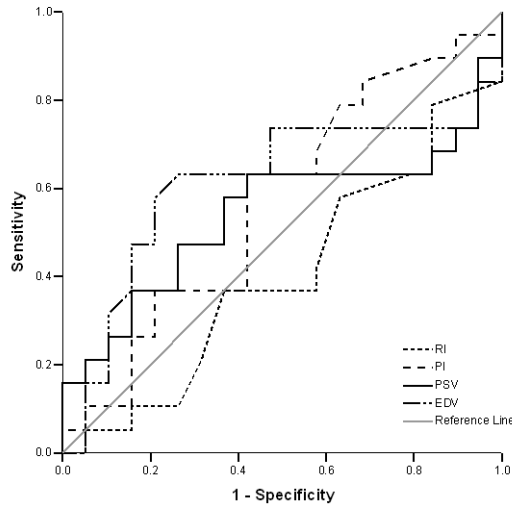
Table 2. Area under the ROC curve (95% confidence interval) of optic nerve diameter and blood flow parameters of ophthalmic, central retinal and posterior ciliary arteries

Variables	Area under the ROC curve (95% CI)
Optic nerve diameter (mm)	0.928 (0.843, 1.013)
Ophthalmic artery	
Peak systolic velocity (cm/second)	0.497 (0.306, 0.688)
End-diastolic velocity (cm/second)	0.504 (0.314, 0.695)
Resistance index	0.503 (0.311, 0.695)
Pulsatile index	0.611 (0.541, 0.680)
Central retinal artery	
Peak systolic velocity (cm/second)	0.540 (0.346, 0.735)
End-diastolic velocity (cm/second)	0.609 (0.416, 0.803)
Resistance index	0.402 (0.220, 0.584)
Pulsatile index	0.569 (0.384, 0.755)
Posterior ciliary artery	
Peak systolic velocity (cm/second)	0.446 (0.257, 0.635)
End-diastolic velocity (cm/second)	0.604 (0.417, 0.791)
Resistance index	0.350 (0.173, 0.528)
Pulsatile index	0.461 (0.272, 0.650)

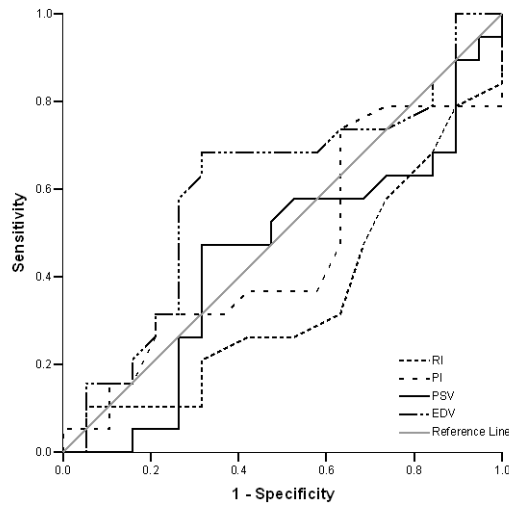
ROC: Receiver operating characteristic
CI: Confidence interval



Ophthalmic Artery



Central Retinal Artery



Posterior Ciliary Artery

ROC: Receiver operating characteristic
PSV: Peak systolic velocity
EDV: End-diastolic velocity
RI: Resistance index
PI: Pulsatile index

Figure 1. Receiver operating characteristic curves for peak systolic velocity, end-diastolic velocity, and resistance index and pulsatile index of ophthalmic, central retinal and posterior ciliary arteries and optic nerve diameter for diagnosis of optic neuritis.

The estimated area under the receiver operating characteristic curves and their 95% confidence intervals are shown in Table 2.

Optic nerve diameter was a significant predictor for ON ($P < 0.001$). The areas under the ROC curves were 0.497 (95% CI: 0.306, 0.688) for PSV, 0.504 (95% CI: 0.314, 0.695) for EDV, 0.534 (95% CI: 0.345, 0.722) for RI, and 0.503 (95% CI: 0.311, 0.695) for PI in OA. None of the blood flow parameters were significantly higher in ON. PSV, EDV, RI and PI of OA, CRA and PCAs covered a similar area. EDV of CRA and PCAs had areas slightly but not significantly larger than that of other blood flow parameters.

Discussion

In this study we found no significant difference in PSV, EDV, RI and PI of OA, CRA and PCAs between eyes with and without ON. The study confirms the reliability of optic nerve diameter for diagnosis of ON. Thickening of the optic nerve results from the inflammation in ON and has been described before^{4,20} and this is likely to be the major cause of the initial loss of visual acuity.⁴ The OA enters through the optic canal, together with the optic nerve. The enlarged optic nerve compresses the OA within the optic canal and this compression may contribute to decreased vascular resistance distal to the optic canal.

Few studies have performed CDI to assess orbital blood flow velocities and optic nerve diameter in ON; these were usually of limited sample size and the results produced were inconsistent. The inconsistency may be explained in part by differences in patients characteristics, the cause of ON, definitions of ON, blood flow velocity measurements, and the amount of time elapsed between the acute attack and examination. While differences in hemodynamic parameters over the course of the disease may partly account for the range of results seen in the literature, it is much more likely that the main component of variance in ON Doppler studies results from differences in instrumentation and technique. Large foot-print transducers, in the 7.5-10.0 MHz range, with poor lateral resolution, placed directly on the closed eyelid at the orbital ridge and were specifically avoiding the lens is not going to give optimal measurements. Elvin et al⁴ evaluated only the resistive indices of the CRA; they found resistive indices increased in the affected side

and attributed the increased resistive indices to nerve swelling and the resultant resistance to flow. The velocities were not measured and the OA was not evaluated. Our findings also differ from those of Karaali et al, who found that PSV, EDV and RI in the OA are increased in patients with acute ON,⁵ although the velocities and resistive indices of the CRA in affected and normal eyes did not differ significantly. In patients with MS, Akarsu et al⁸ suggest that the mean retrobulbar blood flow velocities and mean resistivity index in the OA in the eyes with ON were not significantly different from those in unaffected fellow eyes and healthy control eyes. The mean EDV in the CRA was lower and mean resistivity indices in the CRA and PCAs were higher in eyes with ON than in control eyes. They did not observe any differences in the blood flow velocities and resistivity indices of the OA in eyes with ON when compared with the unaffected eyes. Orbital blood flow velocity studies were performed several months after onset of ON. Hradílek et al¹¹ also reported that PSV, PI and RI in the OA are increased in patients with acute ON although EDV in affected and normal eyes does not differ significantly. However, these changes do not persist over longer period. Furthermore, Pache et al⁹ reported a significant reduction in PSV and EDV of the OA, PCAs and CRA in patients with MS compared with healthy controls. Modrzejewska et al¹² also reported statistically significant diminishing blood flow velocity parameters in eyeball arteries in patients with both MS and ON. They did not observe any changes in vascular resistance indices when compared with the control group. Orbital blood flow velocities were measured several months after onset of ON. The absence of abnormalities in vascular resistance could be due to comparatively long passage of time between clinical manifestation of ON and the study. Goh et al¹⁰ reported results similar to ours. They found that orbital hemodynamics in all retrobulbar vessels did not significantly differ from normal controls in patients with compressive, inflammatory, toxic or hereditary optic neuropathy. On the basis of our findings, optic nerve diameter was found to be the most

reliable and simultaneously most practical predictor of ON.

PSV and EDV are both dependent on the Doppler angle. The RI is angle-independent and provides a good measurement by which to qualify vascular resistance in circulation, particularly in tortuous vessels like the PCAs. The anterior optic nerve derives its blood supply from the PCAs. In this study, we observed lower RI in PCAs.

The characteristics of the pathophysiology of ON not fully described, but thickening of the nerve in association with demyelination and inflammation may compress the blood vessels within the optic canal. Alternatively, vasospasm due to an increased plasma level of endothelin-1,⁹ a potent vasoconstrictor, may result in vasospasm and vascular dysregulation. This could be causing an increase in resistance to flow in the artery and lead on through ischemia to eventual exoplasmic stasis and visual loss.²¹ Evaluation with gray-scale sonography of the optic nerve and CDI of orbital hemodynamics in patients with acute ON combined with proof of decreased RI in PCAs may contribute to assessment of the diagnosis.

Our study has both strengths and limitations. One strength is that CDI measurements of the eye vessels²² and between the right and left eyes²³ have been shown to be reproducible over time. One limitation of the study is that blood flow measurements were only performed in the fellow eyes of the patients and not including healthy cases. However, as values of orbital blood flow velocity are variables within the healthy population, any differences in values between the orbit affected with ON and unaffected orbit are highly significant. Use of the contralateral eye as an internal control therefore seems practical since CDI measurement is known to be influenced by cardiac output and stress level of the patient.²⁴ Moreover, ON swelling may influence CDI readings to an unknown degree independent

of changes in blood flow, due to the altered scattering properties of tissue. Additionally, Akarsu et al⁸ demonstrated that there was a similarity in blood flow velocities between contralateral, unaffected eyes and healthy control eyes. Further studies will be required to fully clarify the issue. None of the patients were on treatment with systemic or topical corticosteroids. The patients in our series were under 50 years, an age at which glaucoma is uncommon and intraocular pressure (IOP) was normal in all patients. An experimental study by Guthoff et al²² has shown that an increase in intraorbital pressure leads to a decrease in CRA flow. Great care was thus taken to apply as little pressure as possible to the patient's eye during CDI examination. Even though the study included the thorough examination of 23 pairs of eyes, the findings should be considered with caution due to the relatively small sample size.

Conclusion

In conclusion, our study indicates that gray-scale sonography as a noninvasive and repeatable diagnostic method showed significant optic nerve thickening on side affected by ON and could play a role in diagnosis of the disease. No unilateral differences were seen in the average PSV, EDV, RI and PI of the OA and CRA. The reduced RI in PCAs may indicate disturbances of retinal and choroidal circulation in patients with ON. Further studies with larger groups of patients are needed with age and gender matched control groups in order to better understand the role of retrobulbar hemodynamics in the pathogenesis of ON.

Acknowledgments

We thank Professor RB Jones, K Shashok and Sarah Griffin-Mason (Author AID in the Eastern Mediterranean) for improving the use of English in the manuscript. The authors report no conflict of interest.

References

1. Acevedo AR, Nava C, Arriada N, et al. Cardiovascular dysfunction in multiple sclerosis. *Acta Neurol Scand* 2000;101(2):85-8.
2. Flachenecker P, Wolf A, Krauser M, et al. Cardiovascular autonomic dysfunction in multiple sclerosis: correlation with orthostatic intolerance. *J Neurol* 1999;246(7):578-86.

3. Speciale L, Sarasella M, Ruzzante S, et al. Endothelin and nitric oxide levels in cerebrospinal fluid of patients with multiple sclerosis. *J Neurovirol* 2000;6 Suppl 2:S62-6.
4. Elvin A, Andersson T, Söderström M. Optic neuritis. Doppler ultrasonography compared with MR and correlated with visual evoked potential assessments. *Acta Radiol* 1998;39(3):243-8.
5. Karaali K, Senol U, Aydin H, et al. Optic neuritis: evaluation with orbital Doppler sonography. *Radiology* 2003;226(2):355-8.
6. Akarsu C, Bilgili MY. Color Doppler imaging in ocular hypertension and open-angle glaucoma. *Graefes Arch Clin Exp Ophthalmol* 2004;42(2):125-9.
7. Hradílek P, Zapletalova O, Dolezil D, Skoloudik D. Acute optic neuritis in multiple sclerosis: evaluation of haemodynamics in the ophthalmic artery with colour Doppler imaging. *Neuroophthalmology* 2005;29:161-4.
8. Akarsu C, Tan FU, Kendi T. Color Doppler imaging in optic neuritis with multiple sclerosis. *Graefes Arch Clin Exp Ophthalmol* 2004;42(12):990-4.
9. Pache M, Kaiser HJ, Akhalbedashvili N, et al. Extraocular blood flow and endothelin-1 plasma levels in patients with multiple sclerosis. *Eur Neurol* 2003;49(3):164-8.
10. Goh KY, Kay MD, Hughes R. Orbital color Doppler imaging in nonischemic optic atrophy. *Ophthalmology* 1997;104(2):330-3.
11. Hradílek P, Stourac P, Bar M, et al. Colour Doppler imaging evaluation of blood flow parameters in the ophthalmic artery in acute and chronic phases of optic neuritis in multiple sclerosis. *Acta Ophthalmol* 2009;87(1):65-70.
12. Modrzejewska M, Karczewicz D, Wilk G. Assessment of blood flow velocity in eyeball arteries in multiple sclerosis patients with past retrobulbar optic neuritis in color Doppler ultrasonography. *Klin Oczna* 2007;109(4-6):183-6.
13. Erdogmus S, Govsa F. Topography of the posterior arteries supplying the eye and relations to the optic nerve. *Acta Ophthalmol Scand* 2006;84(5):642-9.
14. Baxter GM, Williamson TH. Color Doppler imaging of the eye: normal ranges, reproducibility, and observer variation. *J Ultrasound Med* 1995;14(2):91-6.
15. Dees C, Buimer R, Dick AD, Atta HR. Ultrasonographic investigation of optic neuritis. *Eye (Lond)* 1995;9(Pt 4):488-94.
16. Williamson TH, Harris A. Color Doppler ultrasound imaging of the eye and orbit. *Surv Ophthalmol* 1996;40(4):255-67.
17. Planiol T, Pourcelot L, Itti R. [The Carotid and cerebral circulations. Advances in its study by external physical methods. Principles, normal recordings, adopted parameters]. *Nouv Presse Med* 1973;2(37): 2451-6.
18. Gosling RG, King DH. Arterial assessment by Doppler shift ultrasound. *Proc R Soc Med* 1974;67(6 Pt 1):447-9.
19. DeLong ER, DeLong DM, Clarke-Pearson DL. Comparing the areas under two or more correlated receiver operating characteristic curves: a nonparametric approach. *Biometrics* 1988;44(3):837-45.
20. Gerling J, Janknecht P, Hansen LL, Kommerell G. Diameter of the optic nerve in idiopathic optic neuritis and in posterior ischemic optic neuropathy. *Int Ophthalmol* 1997;21(3):131-5.
21. McLeod D, Marshall J, Kohner EM. Role of axoplasmic transport in the pathophysiology of ischaemic disc swelling. *Br J Ophthalmol* 1980;64(4):247-61.
22. Guthoff RF, Berger RW, Winkler P, et al. Doppler ultrasonography of the ophthalmic and central retinal vessels. *Arch Ophthalmol* 1991;109(4):532-6.
23. MacKenzie F, De Vermette R, Nimrod C, et al. Doppler sonographic studies on the ophthalmic and central retinal arteries in the gravid women. *J Ultrasound Med* 1995;14(9):643-7.
24. Mostbeck GH, Gössinger HD, Mallek R, et al. Effect of heart rate on Doppler measurements of resistive index in renal arteries. *Radiology* 1990;175(2):511-3.