

A Missed Intraorbital Wooden Foreign Body Presented as Soft Tissue Mass

Naser Owji, MD¹ • Mohammad Reza Razeghinejad, MD¹
Mohammad Hosein Nowroozadeh, MD²

Abstract

Purpose: To present a case of missed intraorbital wooden foreign body presented as soft tissue mass

Case report: We introduce a case of intraorbital wooden foreign body which presented with orbital soft tissue mass two years after trauma. A plain CT was requested which revealed a foreign body in the right orbit.

Conclusion: It is frequently difficult to identify and localize organic intraorbital foreign bodies despite modern day high-resolution imaging studies.

Keywords: Intraorbital Foreign Body, Soft Tissue Mass, Wooden Foreign Body

Iranian Journal of Ophthalmology 2011;23(2):65-68 © 2011 by the Iranian Society of Ophthalmology

Introduction

An orbital foreign body may lead to variety of signs, symptoms and clinical findings according to its size, location, velocity and composition. The patient may not recall a history of foreign body penetration.¹ Often the entrance site of an organic foreign body is small and self-sealing,² and a quiescent period of days to years may pass before the patient becomes symptomatic.¹ In this report, we present an interesting case of a large wooden intraorbital foreign body (IOFB) retained for 2 years without symptoms and present with orbital soft tissue mass.

Case report

A two-year-old boy was involved in a fall that resulted in an injury of the right orbit with a wooden stick. He visited the emergency

department in our hospital on the same day. Physical examination revealed a cut wound on the right upper lid. There was 2+ relative afferent pupillary defect in the right eye. At that time the computed tomography (CT) was requested which showed a low density object mimicking intraorbital air in the superomedial of orbit (Figure 1 A-C). The patient was admitted to the hospital to receive pulses of intravenous methylprednisolone for traumatic optic neuropathy, but the parents refused to complete the course of treatment and left the hospital against medical advice and did not come back for follow-up visits. Two years later, the patient presented with intermittent swelling in the right upper lid for the past six months.

-
1. Associate Professor of Ophthalmology, Poostchi Ophthalmology Research Center, Shiraz University of Medical Sciences, Shiraz, Iran
 2. Fellowship in Vitreoretinal Surgery, Poostchi Ophthalmology Research Center, Shiraz University of Medical Sciences, Shiraz, Iran

Received: December 22, 2010

Accepted: May 26, 2011

Correspondence to: Naser Owji, MD

Associate Professor of Ophthalmology, Poostchi Ophthalmology Research Center, Shiraz University of Medical Sciences, Shiraz, Iran, Tel:+98 711 2302830, Email: owjin@sums.ac.ir

On examination, visual acuity (VA) was $\frac{3}{6}$ in the right eye and $\frac{6}{6}$ in the left. There were moderate proptosis and restricted right eye movements, most notably on upward gaze. There was also a soft tissue swelling of the upper eyelid. Fundus examination was normal except for optic atrophy of the right eye. With impression of soft tissue mass, a plain CT was requested, which revealed right-sided periorbital and orbital edema, proptosis, and a foreign body in the right orbit (Figure 1 D-F). During the history taking, his parents recalled

the trauma with wooden stick. Comparing to the CT which was performed at the time of injury, the foreign body showed substantial increase in density. These findings led to the assumption that the foreign body was made of wood. Under general anesthesia, orbital exploration was done and a wood stick 2.5 cm in length was surgically removed (Figure 2), and the sinus tract was irrigated with gentamicin sulfate. The postoperative course was uneventful and his ocular motility and cellulitis have been improved.

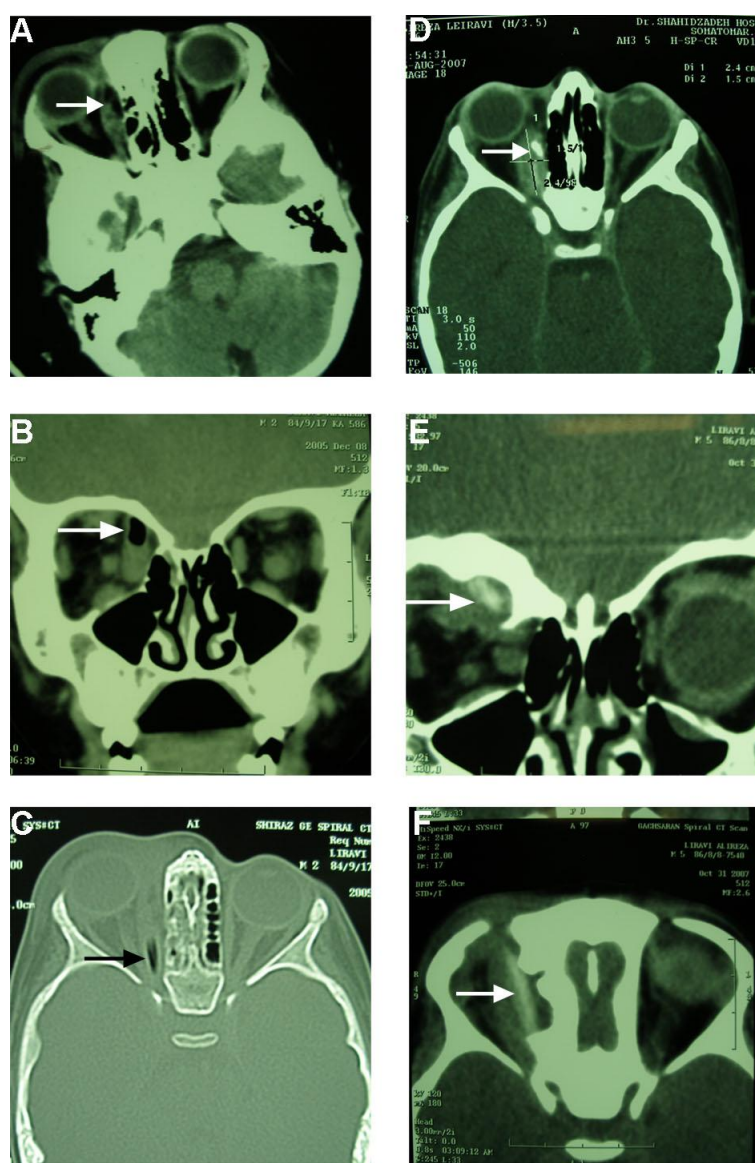


Figure 1. Left column (A-C): Axial and coronal CT of the orbit obtained at several hours after the accident shows the low-density IOFB (arrows). In acute phase the foreign body is more recognizable at bony window setting (C) comparing to soft tissue window (A). Right column (D-F): Axial and coronal CT taken two years after trauma show significant increase in density of IOFB.

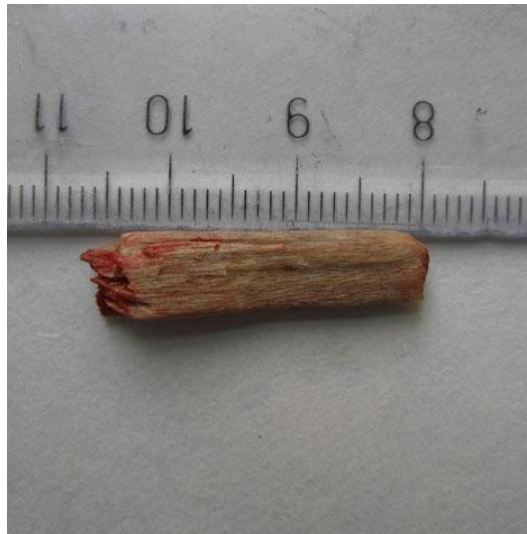

Figure 2. Image of the extracted wood

Discussion

The orbital cavity can host a foreign body for a significant length of time without causing any symptoms¹; however, the retention of wooden foreign body often causes problems.³ They must be removed as they serve as a nidus for orbital infection. It is important to note that wooden foreign bodies often break during attempted removal.¹ Thus, if there is recurrence of clinical symptoms the possibility of a retained foreign body should be considered.

Diagnosis of an impacted wooden substance is often difficult even with the use of advanced investigative procedures.⁴ The patient may present with various complications like granuloma, abscess or chronic discharging sinus through the palpebral skin.¹ Moreover, the CT and histopathologic characteristics may mimic the features of chronic inflammatory disorders such as tuberculosis, sarcoidosis and idiopathic orbital inflammation.⁵

CT is generally considered to be the gold standard for IOFBs.^{3,6} Despite improved resolution of CT scanners; however, wood and other organic IOFBs still present a diagnostic challenge. They could only be described as "probable intraocular foreign bodies" when reported by neuroradiologists experienced in reporting CT.⁷

It is known that wooden foreign bodies can show minus Hounsfield unit (HU) due to their air-filled porous microstructure.⁸ Accordingly,

they may mimic air in CT; a finding occasionally encountered in orbital trauma. However, the radiodensity of wood is variable and may be similar to that of the orbital structures specially fat and muscle.^{9,10}

It has also been reported that the HU of a wooden foreign body increases over the course of time.^{8,9} In the acute stage, the very low density of wood can mimic air bubbles. In this stage, intraorbital air may represent organic IOFB, orbital emphysema associated with sinus fracture, or inserted air during primary trauma; however, a single well defined radiolucency in the absence of sinus fracture should raise the possibility of wooden IOFB specially when there is a history of trauma with wood stick. In the subacute stage, wood assumes a moderate density and may be difficult to distinguish from surrounding orbital fat, which may account for the potential difficulty of recognition. In the chronic stage, the density of wood can become higher than that of extraocular muscles. Moreover, it may be associated with a foreign body reaction, which appears as a homogenous mass surrounding the foreign body, with a density similar to the orbital muscle. The temporal changes of the HU of wooden foreign bodies have been attributed to the replacement of the air within the foreign body by fluid. There have also been a few other proposed mechanisms for the HU change, including absorption of exudates, hematoma,¹¹ and ossification.⁹

In addition to CT, suspected IOFB and associated injuries may also be investigated with plain radiographs, ultrasound, and magnetic resonance imaging (MRI), depending on local expertise, facilities available, and the probable constitution of the IOFB. MRI can distinguish between air and wood and is more helpful in cases of organic IOFBs when CT is negative.¹² MRI is, however, more expensive, less accessible, and requires preMRI imaging (plain radiographs and CT) to exclude metallic IOFBs in cases of orbital trauma. Regarding that bone windows of CT are more sensitive than soft tissue windows for detecting wooden foreign bodies (Figure 1C), they should be requested if we do not access to MRI or it was contraindicated.

Conclusion

In summary, a situation of orbital trauma and secondary orbital inflammatory syndrome must raise the suspicion of a foreign body of the orbit and motivate emergency imaging for optimal management of the disorder. Occasionally, the patient may not recall the trauma, and the role of precise history taking can not be overemphasized. The possibility of a wooden IOFB should be strongly suspected when there is intraorbital density below that of the surrounding intraorbital fat on CT. The follow-up CT several weeks later can make the wooden foreign body visible through increase in HU.¹³ However, MRI is more precise and time-honored and is recommended in this setting. Nonetheless, in some situations all of the current imaging modalities fail to confine a foreign body and surgical exploration is considered necessary.^{12,14}

References

1. Goldberg MF, Paton D. Ocular emergencies. In: Peyman GA, Sanders Dr, Goldberg MF, eds. Philadelphia: WB Saunders, 1980;142-3.
2. Banerjee A, Das A, Agarwal PK, Banerjee AR. Late spontaneous extrusion of a wooden intraorbital foreign body. *Indian J Ophthalmol* 2003;51(1):83-4.
3. Fulcher TP, McNab AA, Sullivan TJ. Clinical features and management of intraorbital foreign bodies. *Ophthalmology* 2002;109(3):494-500.
4. Mandelcorn MS, Brown M. Computed axial tomography localization of intra-orbital foreign body. *Can J Ophthalmol* 1978;13(3):213-5.
5. John SS, Rehman TA, John D, Raju RS. Missed diagnosis of a wooden intra-orbital foreign body. *Indian J Ophthalmol* 2008;56(4):322-4.
6. Rubinstein A, Riddell CE, Kafil-Hussain N, Assaf A. Self-inserted intraorbital foreign bodies. *Ophthal Plast Reconstr Surg* 2005;21(2):156-7.
7. Dass AB, Ferrone PJ, Chu YR, et al. Sensitivity of spiral computed tomography scanning for detecting intraocular foreign bodies. *Ophthalmology* 2001;108(12):2326-8.
8. Hansen JE, Gudeman SK, Holgate RC, Saunders RA. Penetrating intracranial wood wounds: clinical limitations of computerized tomography. *J Neurosurg* 1988;68(5):752-6.
9. Boncoeur-Martel MP, Adenis JP, Rulfi JY, et al. CT appearances of chronically retained wooden intraorbital foreign bodies. *Neuroradiology* 2001;43(2):165-8.
10. Specht CS, Varga JH, Jalali MM, Edelstein JP. Orbitocranial wooden foreign body diagnosed by magnetic resonance imaging. Dry wood can be isodense with air and orbital fat by computed tomography. *Surv Ophthalmol* 1992;36(5):341-4.
11. Ochiai H, Yamakawa Y, Fukushima T, Yamada H. Neuroimaging of a wooden foreign body retained for 5 months in the temporalis muscle following penetrating trauma with a chopstick--case report. *Neurol Med Chir (Tokyo)* 1999;39(11):744-7.
12. Karcioğlu ZA, Nasr AM. Diagnosis and management of orbital inflammation and infections secondary to foreign bodies: a clinical review. *Orbit* 1998;17(4):247-69.
13. Uchino A, Kato A, Takase Y, Kudo S. Intraorbital wooden and bamboo foreign bodies: CT. *Neuroradiology* 1997;39(3):213-5.
14. Cartwright MJ, Kurumety UR, Frueh BR. Intraorbital wood foreign body. *Ophthal Plast Reconstr Surg* 1995;11(1):44-8.