

# Central Retinal Artery Occlusion in Churg-Strauss Syndrome

Mir Naghi Mousavi, MD<sup>1</sup> • Mojtaba Abrishami, MD<sup>2</sup> • Mohammad Khalife, MD<sup>2</sup>

---

## Abstract

**Purpose:** Churg-Strauss syndrome (CSS) is a rare form of small vessel necrotizing vasculitis. Retinal artery and vein occlusion are very rare findings in these patients and they are treated by high-dose corticosteroids and cytotoxics. We describe a rare case of CSS under high-dose corticosteroids and cytotoxic treatment, presenting central retinal artery occlusion (CRAO).

**Case report:** A 45-year-old man with a history of CSS, who had been admitted in the rheumatology ward to receive high-dose pulse corticosteroids, was presented with sudden loss of vision in his left eye four days after admission. He was receiving high doses of oral and intravenous prednisolone and a pulse of cyclophosphamide. Visual acuity (VA) was poor light perception and relative afferent papillary defect was present (3-4 +). A CRAO was diagnosed by the fundusoscopic appearance of retinal whitening, macular thinning, and mild optic disc paleness. In fluorescein angiogram, retinal filling and normal choroidal filling were absent.

**Conclusion:** CSS-associated CRAO should be considered when acute visual loss occurs. Although taking corticosteroids and cytotoxics is the main treatment of patients with CCS, patients may progress to CRAO under this treatment.

**Keywords:** Central Retinal Artery Occlusion, Churg-Strauss Syndrome, Corticosteroids, Vasculitis, Visual Loss

*Iranian Journal of Ophthalmology 2012;24(2):61-64 © 2012 by the Iranian Society of Ophthalmology*

---

## Introduction

Churg-Strauss syndrome (CSS) is a small vessel necrotizing vasculitis characterized by asthma, hypereosinophilia, and vasculitis. It involves multiple organs and systems.<sup>1</sup> Ocular involvements include scleritis, panuveitis, corneal ulcerations, conjunctivitis, conjunctival granuloma, retinal infarctions, orbital inflammatory pseudotumor, ischemic optic neuropathy, retinal artery, and vein occlusion.

However, ocular findings are rare.<sup>2</sup> We present a patient with CSS who developed unilateral central retinal artery occlusion (CRAO) under high-dose intravenous methyl prednisolone. The case was registered at the Ethics Committee of Mashhad University of Medical Sciences. The patient was informed and the consent was signed by him.

---

1. Associate Professor of Ophthalmology, Vitreoretinal Research Center, Khatam-al-Anbia Hospital, Mashhad University of Medical Sciences, Mashhad, Iran

2. Resident in Ophthalmology, Eye Research Center, Khatam-al-Anbia Hospital, Mashhad University of Medical Sciences, Mashhad, Iran

Received: February 27, 2012

Accepted: July 8, 2012

Correspondence to: Mojtaba Abrishami, MD

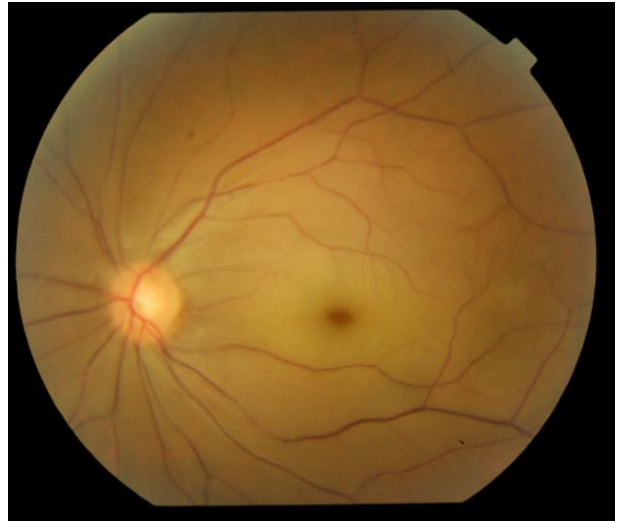
Resident in Ophthalmology, Eye Research Center, Khatam-al-Anbia Hospital, Mashhad University of Medical Sciences, Mashhad, Iran, Email: mojtaba\_abrishami@yahoo.com

Conflict of interest: None of the authors has conflict of interest with the submission.

Financial support: No financial support was received for this submission.

## Case report

A 45-year-old man was admitted to the Rheumatology/Immunology ward for the flare up of his respiratory system complaints. His chief complaint was flare up of asthma, nausea, and extreme pain. He had a confirmed diagnosis of CSS, as he had asthma (being treated by the combination of fluticasone propionate and salmetrol, 500/100 µg inhalation spray for 6 months), eosinophilia (12%), mononeuritis multiplex (pain in all digits of his left hand and digits 1-3 in his right hand and right foot), and pulmonary infiltrates in his first chest X ray. He had a biopsy of left lower extremity nerve showing schwann cell proliferation, mononuclear inflammation, and perivascular eosinophilic aggregation. The patient had been treated with oral prednisolone (25 mg/day) and spray since he was diagnosed, and he was not referred for follow-ups. After admission, intravenous methyl prednisolone (1 g/day) and oral prednisolone (100 mg/day) were prescribed for the patient. In the second day of admission, a 2 g cyclophosphamide was added to his regimen. In his fourth day of admission, an ophthalmology consultation was asked for him. The patient complained of a sudden visual loss since 2 days after hospitalization which manifested as a sudden visual loss of the left eye after waking up. As it was assumed neurologic, a brain vasculitis and brain CT scan and neurology consultation were asked for him. No obvious neurologic finding was reported. Ophthalmologic consultation revealed that his visual acuity (VA) was poor LP in his left eye. Relative afferent pupillary defect was present in his left eye (3-4 +). Anterior segment was within normal limits. In posterior segment, retinal paleness and mild edema was noted. Retinal vessels were narrow. Mild optic disc paleness was obvious. No vasculitis and no vessel involvement were seen. A CRAO was diagnosed by the fundoscopic appearance of retinal whitening, macular thinning, and mild optic disc paleness (Figure 1). Diagnosis was confirmed by a fluorescein angiogram showing absence of retinal filling and normal choroidal filling. He was receiving high doses oral and intravenous prednisolone. Ocular massage was performed as well as breathing in a bag to increase CO<sub>2</sub> content of the inspired air, but these efforts were in vain.



**Figure 1.** Fundus photograph of the left eye of the patient

The patient had no history of systemic arterial hypertension, no obvious cardiac disease and no other specific connective tissue diseases. However, cardiology and rheumatology consultations were requested to evaluate the other known causes of CRAO during his admission in the Immunology/Rheumatology ward. Echocardiographies, both trans-thoracic and trans-esophageal were negative for structural cardiac abnormalities. Carotid Doppler ultrasonography results were within normal limits. The patient had no other metabolic and cardiovascular diseases like hypertension and hyperlipidemia. Rheumatology consultation also revealed no related connective tissue disease, except the CSS; as he has fulfilled the 4 items of criteria completely. Although all routine coagulation laboratory tests were within normal limits, to rule out any coagulopathies, we also requested hematologic consultation, the result of which was normal. Three peripheral blood smears, done by the hematologist, were normal. We reviewed his possible use of any drug, medication (either chemical or herbal) trauma, smoking, and familial history of such diseases again. They were all negative, except the CSS. Although the use of corticosteroids and CRAO has been reported after intravenous application of corticosteroids but this very rare event occurs very early after initiation of the drug. No report of CRAO after cyclophosphamide therapy was found.

The patient was discharged 3 weeks after his disease was controlled. He has been followed carefully ever since. One year later, he was referred to the ophthalmologist. His VA was finger count 0.5 meter in his left eye. The retina was pale and atrophied. Arteries of the retina were narrow. His right eye's VA was within normal limits.

## Discussion

Here, we report a 45-year-old man presented with sudden visual loss. He was under pulse methyl prednisolone (1 gr/day), oral prednisolone therapy (50 mg/day) and received 2 g cyclophosphamide pulse therapy due to flare up of CSS. Two days after admission, he complained that he had a sudden visual loss, but it was considered to be related to CNS vasculitis by the physician. Therefore, urgent ophthalmology consultation was not asked. However, it was asked the day after. As he was examined by an ophthalmologist, CRAO was obvious and as more than 24 hours had passed, the endeavors for saving the eye were in vain.

CSS is a small vessels vasculitis. The American College of Rheumatology developed a criteria for CSS as 1) asthma, 2) eosinophilia greater than 10% on differential white blood cell count, 3) mononeuropathy (including multiplex) or polyneuropathy, 4) non-fixed pulmonary infiltrates on chest X ray, 5) paranasal sinus abnormality, and 6) biopsy containing a blood vessel with extravascular eosinophils. The presence of 4 or more of these 6 criteria yielded a sensitivity of 85% and a specificity of 99.7%. CSS has been reported to be predominantly common in middle aged individuals with a history of new onset or worsened asthma. The condition has a male predilection. Prior to the advent of steroid therapy, this condition invariably led to death, but since the introduction of prednisolone therapy and other immunosuppressive therapies, the outlook has improved for the sufferers so that long-term survival has been seen.<sup>1</sup>

Ocular manifestations of CSS include conjunctival granuloma, orbital inflammatory pseudotumor, ischemic vasculitis, cranial neuropathy, optic neuropathy, retinal artery, and vein occlusion; however, these complications are rare. The ocular manifestations in CSS can be classified into

two groups: pseudotumour-type or orbital inflammatory syndrome, and ischemic vasculitis-type. The first type typically involves a chronic onset, a red eye, orbital abnormalities on imaging, and a negative ANCA, whereas the latter type is characterized typically by sudden onset loss of vision, a quiet-looking eye, lack of orbital imaging abnormalities, and a positive ANCA.<sup>3</sup> The likely cause for a CRAO (with or without ophthalmic or ciliary artery involvement) is the underlying vasculitis associated with the systemic condition and secondary localized thrombosis under the hypercoagulable state, which was assumed to be present by the elevated fibrin degradation products.<sup>4</sup>

Udono et al reported a case of CSS receiving corticosteroids with bilateral CRAO. He was well until the oral prednisolone was tapered, then respiratory system symptoms, and bilateral CRAO occurred. By increasing the corticosteroids dose and adding cyclophosphamide and anticoagulant therapy, his systemic problems were solved but not his ocular ones.<sup>4</sup> Asako et al reported a patient with CSS with CRAO, whose VA was partially improved by anticoagulant, high-dose corticosteroids, and steroid pulse therapy. He proposed this treatment for CSS patients with CRAO.<sup>2</sup>

De Salvo et al reported branch retinal vein occlusion (BRVO) followed by CRAO in a patient with CSS. He was treated by high-dose corticosteroids and cyclophosphamide, too. Although his general condition was improved, his visual loss was not resolved.<sup>5</sup> Hamman et al reported a case of combined central retinal artery and vein occlusion in CSS. They had used high-dose corticosteroids therapy. Although they had not reached an improvement in the vision, they suggested corticosteroids should be instigated promptly in order to prevent further systemic or ocular vasculitis.<sup>6</sup>

There are several reports of CRAO in CSS. All of them propose prompt application of corticosteroids. Here we report a patient, who was not correctly diagnosed in the beginning of the symptoms. As far as we have searched, it is the first case that a patient with CSS undergoes CRAO under high-dose steroid and cytotoxic treatment. It should be noted that although ocular complications are rare, physicians should keep it in minds that

devastating irreversible complications may happen. On the other hand, in patients younger than 65 years with an occlusive retinal vessel episode and lung disease, we strongly suggest always to check systemic vasculitis such as CSS. This is to avoid a delayed diagnosis which can lead to more severe or non resolving complications. A novel finding in this case is that although the preferred treatment for these patients is corticosteroids and cytotoxic, our patient developed CRAO under high-dose

corticosteroids and cytotoxic treatment.

### **Conclusion**

CRAO can occur during the course of CSS even under treatment a prompt and extensive treatment and management could save the vision.

### **Acknowledgement**

The authors thank Dr Mostafa Kamandi, resident in Internal Medicine, Mashhad University of Medical Sciences, for his kind help.

### **References**

1. Borke ME, Nwagu MU, Obaseki D, Bazuaye NO. Churg Strauss syndrome: a review. *Niger J Med* 2010;19(2):136-9.
2. Asako K, Takayama M, Kono H, Kikuchi H. Churg-Strauss syndrome complicated by central retinal artery occlusion: case report and a review of the literature. *Mod Rheumatol* 2011;21(5):519-23.
3. Takanashi T, Uchida S, Arita M, et al. Orbital inflammatory pseudotumor and ischemic vasculitis in Churg-Strauss syndrome: report of two cases and review of the literature. *Ophthalmology* 2001;108(6):1129-33.
4. Uono T, Abe T, Sato H, Tamai M. Bilateral central retinal artery occlusion in Churg-Strauss syndrome. *Am J Ophthalmol* 2003;136(6):1181-3.
5. De Salvo G, Li Calzi C, Anastasi M, Lodato G. Branch retinal vein occlusion followed by central retinal artery occlusion in Churg-Strauss syndrome: unusual ocular manifestations in allergic granulomatous angiitis. *Eur J Ophthalmol* 2009;19(2):314-7.
6. Hamann S, Johansen S. Combined central retinal artery and vein occlusion in Churg-Strauss syndrome: case report. *Acta Ophthalmol Scand* 2006;84(5):703-6.