

Evaluation of Topical Phenytoin Eye Drop 1% Therapeutic Effects on Corneal Alkali Burns in Rabbit Model

Mohammad Naeim Aminifard, MD¹ • Hamid Reza Barkhordari Yazdi, MD²
Shabnam Pahlavanzadeh, MD²

Abstract

Purpose: Studies show that phenytoin is effective in improvement of different chronic ulcers such as venous stasis ulcers, and diabetic ulcers. The exact mechanism is yet not clear; investigators thought that phenytoin might help to heal intractable corneal ulcers by reducing inflammation, differentiating limbal fibroblasts, and promoting the invasion of the cornea with new blood vessels as shown in animal and in vitro studies. Given the importance of healing process of corneal alkali burns which are common and always problematic, the need for finding strategies that can help improve this process is always felt. This study investigated the effect of topical phenytoin 1% in corneal epithelial defects healing in rabbit model.

Methods: A chemical corneal epithelial defect was created in one eye of albino rabbits in animal house of Al-Zahra eye center. Rabbits were randomly assigned into two groups of ten. The case group was treated using soluble phenytoin 1% eye drop and the control group received normal saline eye drop. Clinical assessment and epithelial defect size were evaluated daily for 14 days using slit-lamp biomicroscopy. Data were analyzed using Independent t-test and ANOVA on repeated observations.

Results: The difference between the first and the last day of follow-up in each group was significant ($P < 0.05$). Topical phenytoin 1% induced a significantly faster epithelial healing in comparison with the control group ($P < 0.05$).

Conclusion: Topical phenytoin 1% can help in improvement of epithelial defect caused by alkali burns as a supplement treatment.

Keywords: Phenytoin, Corneal Alkali Burn

Iranian Journal of Ophthalmology 2012;24(3):33-38 © 2012 by the Iranian Society of Ophthalmology

-
1. Professor of Ophthalmology, Department of Ophthalmology, Al-Zahra Eye Hospital, Zahedan University of Medical Sciences, Zahedan, Iran
 2. Assistant Professor of Ophthalmology, Department of Ophthalmology, Al-Zahra Eye Hospital, Zahedan University of Medical Sciences, Zahedan, Iran

Received: December 5, 2011

Accepted: May 24, 2012

Correspondence to: Hamid Reza Barkhordari Yazdi, MD

Assistant Professor of Ophthalmology, Department of Ophthalmology, Al-Zahra Eye Hospital, Zahedan University of Medical Sciences, Zahedan, Iran, Email: barkhordariyazdi@yahoo.com

No external funding

This information has not been presented at any meeting.

None of the authors have any proprietary or commercial interest in any way related to this project.

Introduction

Chemical injuries to the eye are common and represent one of the “true” ophthalmic emergencies. Severe ocular damage is most commonly associated with strong alkaline or acidic compounds. Bilateral chemical exposure is specially devastating, often resulting in complete visual disability. Immediate, prolonged irrigation, followed by aggressive early management and close long-term monitoring, is essential to promote ocular surface healing and to provide the best opportunity for visual rehabilitation.¹⁻³

The severity of the injury correlates directly to exposure duration and the causative agent. Treatment of such injuries requires medical and surgical intervention, both acutely and in the long-term. Regardless of the underlying chemical involved, the common goals of management include removing the offending agent, controlling inflammation and promoting ocular surface healing with maximal visual rehabilitation.⁴ Various medical therapies have been used to achieve these objectives, including topical and systemic ascorbate, citrate, tetracycline, progesterone and steroids. Recent studies have evaluated the therapeutic effect of metalloproteinase inhibitors,⁵⁻⁷ anti-coagulant agents,⁸ oxygen,⁹ and immune inhibiting agents,^{10,11} all of which have failed to show promising results.

Despite advances in medical and surgical treatment modalities, the consequences of severe ocular chemical burns can have profound psychological, economic, and social consequences for the patient.

The 5.5-diphenyl-2-4-imidazolidione, sodium (phenytoin), was synthesized in 1908, and has been used as an anticonvulsant, since 1937. It was later noticed that half the patients treated with phenytoin developed gingival overgrowth.¹² This apparent stimulatory effect of phenytoin on connective tissue suggested an exciting possibility for its use in wound healing. Studies have shown topical phenytoin to promote healing of decubitus ulcers,¹³ venous stasis ulcers,¹⁴ diabetic ulcers,¹⁵ traumatic wounds, burns, and leprosy trophic ulcers.¹⁶ Subsequently, phenytoin was found to promote the healing and to increase the tensile strength of experimental skin and corneal wounds.¹⁷

Given the importance of accelerated corneal healing after chemical injuries and the

challenges that still remain, as mentioned above, the authors of this article anticipated the use of topical phenytoin in corneal wound healing after induced chemical burn.

Methods

In this experimental study, corneal epithelial defect was created in a single eye of 20 albino rabbits (Razi institute). Sedation was given with intramuscular injection of ketamine 37.5 mg and lidocaine 10 mg/kg (body weight), and topical eye drop Tetracaine 0.5% (SINA daroo- Tehran, Iran) instilled, then disinfected with povidone iodine solution 5%. An 8 mm central corneal epithelial defect was created using a trephine with instillation of 0.4 cc of NaOH one molar for 35 seconds. The defect was washed with 20 ml normal saline 0.9%. Exclusion criteria were primary epithelial defect larger than 8 mm or corneal perforation (two rabbits with epithelial defects larger than 8 mm were excluded).

Rabbits were randomly assigned to one of two groups. This study was blinded, as the researcher was unaware of treatment solution until completion of study. After creating a chemical burn group one was treated by topical soluble phenytoin 1% and the other group with saline drops 4 times a day. Isotonic phenytoin eye drop was made with 20 mg phenytoin sterile powder (merck. germany) in 1 cc sterile distilled water with 3.67 mg NaCl up to 100 cc sterile distilled water in the balloon which was sterilized in autoclave for 15 minute (Concentration 1%).

Daily examination of epithelial defect size was conducted using (Haag-Streit Bern Swiss made) slit-lamp biomicroscopy. During the study period, researcher also monitored eye irritation and corneal infection. Examination was continued until 14 days. Data were analyzed by Independent t-test and ANOVA on repeated observations using SPSS version 16.

Results

Normal distribution of data in each group was proved with Kolmogorov-Smirnov test ($P > 0.05$). Mean and standard deviation of corneal epithelial defects in 14 days follow-up in both phenytoin and normal saline therapy groups are shown in Table 1. Because the diameter of epithelial defects induced in both

groups was 8 mm in the first day data reported in this table start at day 2. Highest corneal epithelial defect was recorded on the first day and the lowest in day 14 in both groups.

Given that this study compared the mean corneal epithelial defect between two groups at different times and treatment groups and time effect be measured. Therefore, analysis of variance method repeatedly was used to test results during 14 days. The difference in corneal epithelial defect size was significant in

both groups when comparing day one and the following 14 days of investigation ($P < 0.05$).

None paired student t-test was used to compare mean corneal epithelial defects size in 14 days follow-up between the two groups. There was no statistically difference between corneal epithelial defect size between the two groups on the first day ($P = 0.914$). But the difference in corneal epithelial defect size between the two groups was statistically significant on the second day to day 14 of follow-up ($P < 0.05$) (Figures 1 and 2).

Table 1. Comparison table of mean and standard deviation in corneal epithelial defects for 14 days follow-up in saline and phenytoin therapy groups

	Day 1 Epithelial defect Size	Day 2	Day 3	Day 4	Day 5	Day 6	Day 7	Day 8	Day 9	Day 10	Day 11	Day 12	Day 13	Day 14
Normal saline group														
Rabbit 1	7.96	7.94	6.85	6.55	5.25	4.58	3.21	2.98	1.56	1.01	.98	.68	.45	.28
" 2	7.66	7.64	7.55	6.45	5.01	4.03	3.32	2.05	1.06	1.00	.98	.87	.76	.65
" 3	7.88	7.86	6.55	5.55	4.87	3.66	2.99	1.99	1.65	1.33	.89	.66	.33	.18
" 4	7.87	7.86	6.44	5.55	4.53	3.55	2.56	1.77	1.34	1.20	.99	.76	.53	.44
" 5	7.84	7.83	6.71	5.55	4.31	3.66	2.76	1.56	1.43	1.00	.89	.56	.33	.22
" 6	7.88	7.86	6.66	5.55	4.64	3.08	2.65	1.99	1.65	1.11	.99	.66	.23	.13
" 7	7.69	7.66	6.50	5.55	4.87	3.66	2.89	1.87	1.65	1.22	.99	.56	.23	.20
" 8	7.99	7.96	6.31	5.55	4.89	3.32	2.34	1.45	1.22	1.00	.79	.46	.37	.18
" 9	7.95	7.93	6.64	5.55	4.87	3.54	2.65	1.43	1.00	.87	.69	.46	.20	.16
" 10	7.94	7.94	6.71	5.55	4.92	3.66	2.99	1.77	1.55	1.11	.89	.66	.25	.18
Total														
Mean	7.8660	7.8480	6.6920	5.7400	4.8160	3.6740	2.8360	1.8860	1.4110	1.0850	.9080	.6330	.3680	.2620
Std. Deviation	.11118	.11331	.33862	.40125	.26243	.40275	.30215	.44433	.24651	.13591	.10163	.12789	.17313	.16199
Minimum	7.66	7.64	6.31	5.55	4.31	3.08	2.34	1.43	1.00	.87	.69	.46	.20	.13
Maximum	7.99	7.96	7.55	6.55	5.25	4.58	3.32	2.98	1.65	1.33	.99	.87	.76	.65
Phenytoin group														
Rabbit 1	7.69	7.55	5.85	3.55	2.25	1.58	1.21	.98	.56	.45	.20	.13	.05	.00
" 2	7.99	7.90	5.55	6.45	2.01	1.53	1.32	.85	.68	.45	.11	.05	.00	.00
" 3	7.95	6.86	4.55	3.14	2.87	1.66	1.14	.99	.65	.22	.15	.11	.03	.00
" 4	7.94	6.88	5.44	3.64	3.53	1.55	1.32	.77	.34	.23	.16	.12	.07	.06
" 5	7.84	6.94	4.88	3.10	2.45	1.10	.95	.77	.68	.44	.19	.11	.08	.00
" 6	7.88	6.80	5.34	4.08	3.12	2.12	1.76	.97	.55	.32	.21	.13	.05	.02
" 7	7.88	7.55	5.00	4.12	2.87	1.66	1.89	1.04	.77	.54	.23	.16	.05	.00
" 8	7.93	7.00	5.31	3.12	2.89	1.32	1.44	1.05	.94	.80	.70	.28	.22	.18
" 9	7.75	7.70	5.64	3.55	3.87	2.54	1.65	.77	.55	.33	.21	.11	.05	.00
" 10	7.86	7.80	5.77	3.99	2.20	1.55	1.06	.99	.77	.44	.24	.12	.06	.00
Total														
Mean	7.8710	7.2980	5.3330	3.8740	2.8060	1.6610	1.3740	.9180	.6490	.4220	.2400	.1320	.0660	.0260
Std. Deviation	.09267	.43901	.41376	.98450	.59692	.40314	.30942	.11526	.16292	.16851	.16633	.05884	.05835	.05739
Minimum	7.69	6.80	4.55	3.10	2.01	1.10	.95	.77	.34	.22	.11	.05	.00	.00
Maximum	7.99	7.90	5.85	6.45	3.87	2.54	1.89	1.05	.94	.80	.70	.28	.22	.18

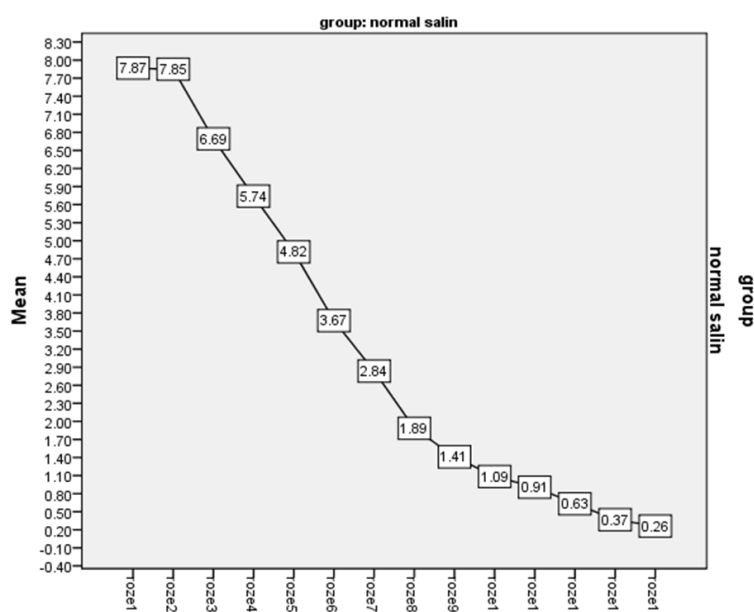


Figure 1. Mean corneal epithelial defects size in 14 days follow-up in saline therapy group

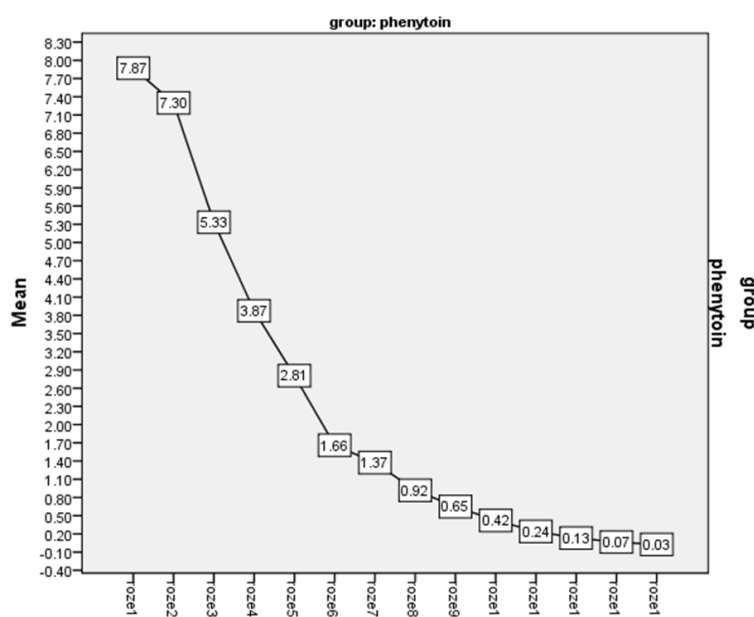


Figure 2. Mean corneal epithelial defects size in 14 days follow-up in phenytoin therapy group

Discussion

Chemical injuries of the eye are true emergencies requiring a good history, prompt clinical evaluation, and treatment. The severity of the injury relates directly to the duration, the type of the chemical, and the deviation of the corrosive substance from the physiological pH. Treatment of chemical injuries to the eye requires medical and surgical intervention,

both promptly and in the long term, for maximal visual rehabilitation.

Regardless of the underlying chemical involved, common goals of management include the following; 1) removing the offending agent, 2) promoting ocular surface healing, 3) controlling inflammation, 4) preventing infection, and 5) controlling IOP.

These goals can be accomplished using immediate copious irrigation, ascorbate, therapeutic bandage contact lens, amniotic membrane transplants, topical steroids, topical antibiotics and aqueous suppressants.^{18,19}

Phenytoin (diphenylhydantoin) was introduced into therapy in 1937 for the effective control of convulsive disorders. In 1939 Kimball first observed that gingival hyperplasia occurred in some patients treated with phenytoin; this stimulated the study regarding the potential use of phenytoin in wound healing.²⁰ Shapiro carried out the first controlled clinical trial in 1958, finding that periodontal patients with surgical wounds who were pretreated with oral phenytoin had less inflammation, less pain, and accelerated healing compared with controls.²¹ Subsequently, phenytoin was found to promote the healing and to increase the tensile strength of experimental skin and corneal wounds.¹⁷

In this study we evaluated the therapeutic effect of topical phenytoin drop on chemically induced corneal epithelial defects in the rabbit model. To our knowledge this is the first study using phenytoin drops on cornea. One study demonstrating the effect of topical powder phenytoin in non-healing corneal ulcers, but itching sensation was a major problem leading to corneal perforation in one case. This study also showed that ocular pain decreased within 10 to 15 minutes with topical phenytoin treatment.²² In our study the group receiving topical phenytoin also showed significant benefit in comparison with the control group but the comfort; regarding pain and itching sensations should be evaluated in further studies on human cases.

The mechanism by which phenytoin accelerates wound healing is unknown. Clinical, animal, and in vitro studies suggest

that phenytoin may be involved in the healing process at several levels including stimulating fibroblast proliferation, enhancing the formation of granulation tissue, decreasing collagenase activity (by reducing its production or secretion or both), promoting deposition of collagen and other connective tissue components, decreasing bacterial contamination, and decreasing wound exudate.²³⁻²⁴ Biopsies of phenytoin treated open wounds show neovascularization, collagenization, and decreased polymorphonuclear and eosinophil cell infiltration.²⁵⁻²⁷ A number of clinical studies indicate that phenytoin decreases the bacterial load of wounds.^{25,26,28} Topical phenytoin was reported to eliminate *Staphylococcus aureus*, *E. coli*, *Klebsiella* spp. and *Pseudomonas* spp. from wounds within 7-9 days. It is unknown if phenytoin has intrinsic antibacterial activity, or if the effect of phenytoin on the bacterial load of wounds is mediated indirectly by effects on inflammatory cells and neovascularization.^{28,29} Local pain relief has also been observed with topical phenytoin therapy, which can be explained by its membrane-stabilizing action; the reduced inflammatory response may also contribute.^{12,13} Facilitation of nerve regeneration has also been reported with phenytoin.²⁹ All of the mechanisms mentioned above can facilitate the healing effect of phenytoin on corneal epithelial defects. Further studies on human cases should be conducted to confirm these findings in the cornea.

Conclusion

Topical phenytoin 1% compare to normal saline significantly improved corneal epithelial defect size at the second day up to day 14 follow-up.

References

1. Merle H, Gérard M, Schrage N. [Ocular burns]. *J Fr Ophtalmol* 2008;31(7):723-34.
2. Hodge C, Lawless M. Ocular emergencies. *Aust Fam Physician* 2008;37(7):506-9.
3. Spector J, Fernandez WG. Chemical, thermal, and biological ocular exposures. *Emerg Med Clin North Am* 2008;26(1):125-36, vii.
4. Sheha H, Hashem H, Liang L, et al. Amniotic membrane extract for acute ocular chemical burns. *Journal of American Science* 2010;6(11):427-33.
5. Pfister RR, Sommers CI. L-arginine-threonine-arginine (RTR) tetramer peptide inhibits ulceration in the alkali-injured rabbit. *Cornea* 2006;25(10):1187-92.

6. Paterson CA, Wells JG, Koklitis PA, et al. Recombinant tissue inhibitor of metalloproteinases type 1 suppresses alkali-burn-induced corneal ulceration in rabbits. *Invest Ophthalmol Vis Sci* 1994;35(2):677-84.
7. Sangwan VS, Akpek EK, Voo I, et al. Krill protease effects on wound healing after corneal alkali burn. *Cornea* 1999;18(6):707-11.
8. Haddox JL, Pfister RR, Slaughter SE. An excess of topical calcium and magnesium reverses the therapeutic effect of citrate on the development of corneal ulcers after alkali injury. *Cornea* 1996;15(2):191-5.
9. Sharifipour F, Zamani M, Idani E, Hemmati AA. Oxygen therapy for severe corneal alkali burn in rabbits. *Cornea* 2007;26(9):1107-10.
10. Liu L, Li YP, Huang SQ, et al. [Mechanism of keratinocyte growth factor-2 accelerating corneal epithelial wound healing on rabbit alkali burned cornea]. *Zhonghua Yan Ke Za Zhi* 2005;41(4):364-8.
11. Liu L, Li Y, Huang S, et al. Keratinocyte growth factor-2 on the proliferation of corneal epithelial stem cells in rabbit alkali burned cornea. *Yan Ke Xue Bao* 2007;23(2):107-16.
12. Talas G, Brown RA, McGruther DA. Role of phenytoin in wound healing—a wound pharmacology perspective. *Biochem Pharmacol* 1999;57(10):1085-94.
13. Rhodes RS, Heyneman CA, Culbertson VL, et al. Topical phenytoin treatment of stage II decubitus ulcers in the elderly. *Ann Pharmacother* 2001;35(6):675-81.
14. Castañeda-Vázquez MA, Castañeda-Vázquez H, Garzón de la Mora P, Flores-Martínez N. [Cicatrización de úlceras venosas con difenilhidantoin sodio]. *Rev Biomed* 2001;12(3):148-56.
15. El-Nahas M, Gawish H, Tarshoby M, State O. The impact of topical phenytoin on recalcitrant neuropathic diabetic foot ulceration. *J Wound Care* 2009;18(1):33-7.
16. Bhatia A, Nanda S, Gupta U, et al. Topical phenytoin suspension and normal saline in the treatment of leprosy trophic ulcers: a randomized, double-blind, comparative study. *J Dermatolog Treat* 2004;15(5):321-7.
17. Kolbert GS. Oral diphenylhydantoin in corneal wound healing in the rabbit. *Am J Ophthalmol* 1968;66(4):736-8.
18. Huang Y, Meek KM, Ho MW, Paterson CA. Analysis of birefringence during wound healing and remodeling following alkali burns in rabbit cornea. *Exp Eye Res* 2001;73(4):521-32.
19. Bazan HE, Tao Y. PAF antagonists as possible inhibitors of corneal epithelial defects and ulceration. *J Ocul Pharmacol Ther* 1997;13(3):277-85.
20. Kimball OP, Horan TN. The use of Dilantin in the treatment of Epilepsy. *Ann Intern Med* 1939;13(5):787-93.
21. Shapiro M. Acceleration of gingival wound healing in non-epileptic patients receiving diphenylhydantoin sodium (dilantin, epanutin). *Exp Med Surg* 1958;16(1):41-53.
22. Desai NC, Desai S, Assie S, Desai R. Topical application of phenytoin in the treatment of chronic corneal ulcers. *Personal Communication* 1993.
23. McAnally LE, Thompson D. Use of phenytoin for wound healing. *Hospital Pharmacy* 1992;27:649-50.
24. Anstead GM, Hart LM, Sunahara JF, Liter ME. Phenytoin in wound healing. *Ann Pharmacolther* 1996;30(7-8):768-75.
25. Lodha SC, Lohiya ML, Vyas MC, et al. Role of phenytoin in healing large abscess cavities. *Br J Surg* 1991;78(1):105-8.
26. Muthukumarasamy MG, Sivakumar G, Manoharan G. Topical phenytoin in diabetic foot ulcers. *Diabetes Care* 1991;14(10):909-11.
27. Mendiola-González JF, Espejo-Plascencia I, Chapa-Alvarez JR, Rodriguez-Noriega E. Sodium diphenylhydantoin in burns: effects on pain and healing (letter). *Invest Med Int* 1983;10:449-51.
28. el Zayat SG. Preliminary experience with topical phenytoin in wound healing in a war zone. *Mil Med* 1989;154(4):178-80.
29. Modaghegh S, Salehian B, Tavassoli M, et al. Use of phenytoin in healing of war and non-war wounds. A pilot study of 25 cases. *Int J Dermatol* 1989;28(5):347-50.