

# Branch Retinal Vein Occlusion as A Coincident Ocular Sign of Systemic Primary Cytomegalovirus Infection in An Immunocompetent Status: A Case Report

Fedra Hajizadeh, MD<sup>1</sup> • Hooshang Faghihi, MD<sup>1,2</sup> • Mohammad Riazi Esfahani, MD<sup>1,2</sup>

---

---

## Abstract

**Purpose:** To report a patient with branch retinal vein occlusion (BRVO) and serologic evidence of primary Cytomegalovirus (CMV) infection

**Case report:** We have reported a 27-year-old male with a complaint of sudden decrease in right eye vision starting a few days before.

**Results:** Immunoglobulin G (IgG) seroconversion indicated primary CMV infection.

**Conclusion:** Involvement and obstruction of small retinal veins may occur in association with primary CMV infection and should be considered in the differential diagnosis of BRVO in healthy young adults. An appropriate assay for CMV infection should be done for young patients with retinal vascular occlusion to rule out the diagnosis.

**Keywords:** Branch Retinal Vein Occlusion, Cytomegalovirus, Immunocompetent

*Iranian Journal of Ophthalmology 2012;24(3):62-64 © 2012 by the Iranian Society of Ophthalmology*

---

---

## Introduction

Cytomegalovirus (CMV) can cause severe ocular disease in immunocompromised patients (retinitis).<sup>1</sup> Symptomatic CMV infection in immunocompetent hosts has traditionally been considered to have a benign, self-limited course. Although medical literature contains a considerable number of reports on severe clinical manifestations of CMV infection in immunocompetent patients, there are limited reports concerning ocular involvement in such cases.<sup>2,3</sup> In immunocompetent patients CMV infection can

result in limited uveitis and/or cystoid macular edema.<sup>3</sup>

We report a patient with branch retinal vein occlusion (BRVO) and serologic evidence of primary CMV infection.

## Case report

The presenting case is a healthy looking 27-year-old male with a complaint of acute decrease in the right eye vision, starting a few days before; 3 weeks after a severe episode of common cold (myalgia, rhinorrhea, neck lymphadenopathy, fever).

---

1. Noor Ophthalmology Research Center, Noor Eye Hospital, Tehran, Iran

2. Eye Research Center, Farabi Eye Hospital, Tehran University of Medical Sciences, Tehran, Iran

Received: November 14, 2011

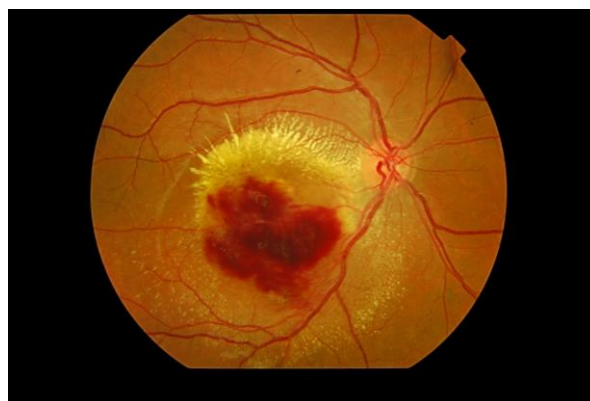Accepted: August 9, 2012

Correspondence to: Fedra Hajizadeh, MD

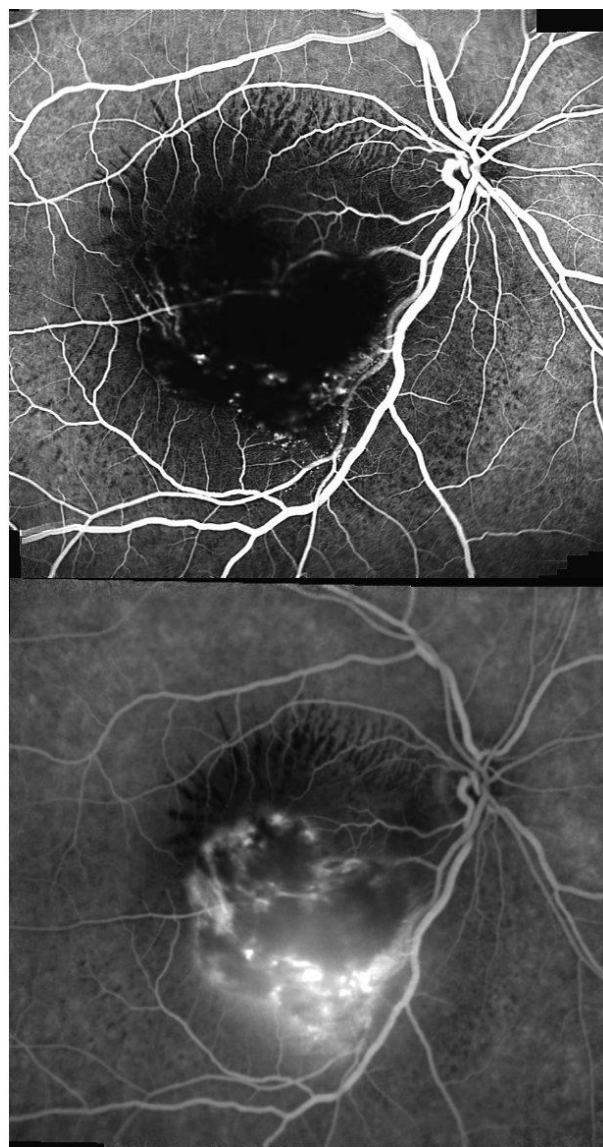
Noor Ophthalmology Research Center, Noor Eye Hospital, Tehran, Iran, Email: fhajizadeh@noorvision.com

Visual acuity (VA) in his right eye was  $20/80$ , and in fundoscopy, signs of inferotemporal BRVO (flame shape hemorrhages and hard exudates accumulation, retinal vein engorgement, retinal edema in the inferior part of macula, and macular thickening in distribution of inferotemporal retinal vein, with delayed vascular filling in fluorescein angiography) were notable. There was a small hemorrhagic preretinal patch at the site of retinal vein bifurcation. History of any previous inflammatory or vascular disease was negative. Primary laboratory work-up for coagulative disorders, vasculitis, and autoimmune disorders were negative. Three weeks later, the patient's symptoms progressed and VA decreased to  $20/160$ , while in fundoscopy, the hemorrhagic patch extended to the inferior macula (Figures 1 and 2) with increased macular edema and thickness (central foveal thickness was  $450 \mu$ ). Extensive works up for other etiologies, infectious [(tuberculosis, syphilis, lyme disease, brucellosis, CMV, herpes simplex virus, varicella zoster virus, Epstein-Barr virus, hepatitis, acquired immunodeficiency syndrome, Toxoplasmosis], autoimmune [Bechet's disease, systemic lupus erythematosus, sarcoidosis, Wegener's granulomatosis, Polyarteritis nodosa, Churg-Strauss syndrome, Relapsing polychondritis, Rheumatoid arthritis, HLA-B27-associated uveitis, Crohn's disease] were performed.

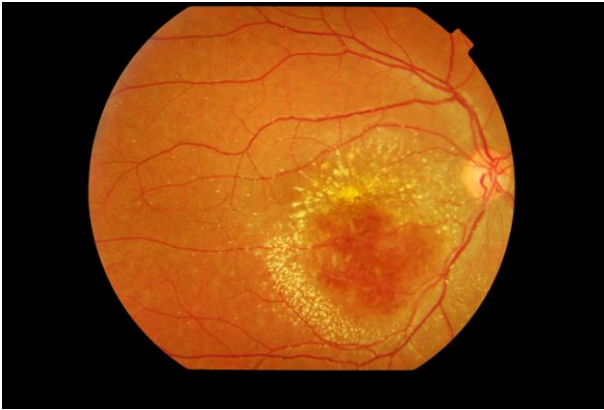The laboratory examination revealed anti-CMV IgM antibody levels of 57 AU/ml using the electro-chemiluminescence method (normal  $<30$  AU/ml) with low levels of IgG antibody (0.2 IU/ml). The CD4 count was checked and was within normal limits. HIV antibody evaluation tested twice 6 months apart with the ELISA technique was also negative. There was no inflammation or positive findings for progressive retinitis in serial fundoscopy and examination. Four weeks later both IgM and IgG were high; 47.5 AU/ml and 8.3 IU/ml (normal IgG level  $<0.6$  IU/ml). Six months after the first appearance of symptoms, VA increased to  $20/40$  and retinal hemorrhages and foveal thickness considerably decreased and reached to the near normal value (central foveal thickness reach to  $285 \mu$ ) (Figure 3).



**Figure 1.** Color fundus photograph of the right eye (OD) 3 weeks after the beginning of visual symptoms. Note the arcuate preretinal hemorrhages in inferotemporal arcade with surrounding hard exudates and severe localized macular edema.



**Figure 2.** Fluorescein angiography in arteriovenous phase (A) and 7 minutes after dye injection (B) revealed collateral vessel dilation as hyperfluorescence dots at the inferior temporal arcade with late staining of vascular walls.



**Figure 3.** Color fundus photograph of the right eye 6 months after visual symptoms. Note the significant decrease in the preretinal hemorrhages and edema that was associated with improved visual acuity to  $20/40$ .

### Discussion

IgG seroconversion indicated primary CMV infection<sup>4</sup> in our patient and it may be considered as one of the underlying etiologies of retinal vein occlusion in healthy young adults. Serious CMV ocular infection is seen almost exclusively in immunocompromised patients and reports of ocular involvement in immunocompetent adult are very limited.<sup>2,3</sup> However endothelial cells are common targets of CMV infection and carotid intimal-medial

thickening,<sup>5</sup> deep vein thrombosis, pulmonary embolism<sup>6</sup> and portal vein thrombosis<sup>7</sup> have been observed in cases of active primary CMV infection in healthy persons. However a group of patients with proved primary CMV infection are needed to establish CMV as an etiologic factor for retinal vein occlusion. Therefore involvement and obstruction of small retinal veins may be a coincident finding with primary CMV infection but it might be considered in the differential diagnosis of BRVO in healthy young adults, and appropriate assay for CMV infection might be added to the list of laboratory examination for healthy young patient with retinal vascular occlusion. The necessity of starting antiviral therapy for such patients is the question that must be answered in the future with detection of more patients with such etiology for BRVO.

### Conclusion

Primary CMV infection should be considered in the differential diagnosis of BRVO in healthy young adults. Concomitant signs of systemic CMV infection could raise the possibility of this viral infection as an etiologic factor for BRVO.

### References

1. Wilson RJ. Cytomegalovirus retinitis in AIDS. *J Am Optom Assoc* 1992;63(1):49-58.
2. Markomichelakis NN, Canakis C, Zafirakis P, et al. Cytomegalovirus as a cause of anterior uveitis with sectoral iris atrophy. *Ophthalmology* 2002;109(5):879-82.
3. Rafailidis PI, Mourtzoukou EG, Varbobitis IC, Falagas ME. Severe cytomegalovirus infection in apparently immunocompetent patients: a systematic review. *Virology* 2008;5:47.
4. Revello MG, Gerna G. Diagnosis and management of human cytomegalovirus infection in the mother, fetus, and newborn infant. *Clin Microbiol Rev* 2002;15(4):680-715.
5. Hirabayashi Y, Ishii T, Kadera T, et al. Acute cytomegalovirus infection and transient carotid intimal-medial thickening in a young, otherwise healthy woman. *J Clin Microbiol* 2003;41(8):3978-80.
6. Welinder JG, Orholm MK, Böttiger B. [Primary cytomegalovirus infection and thrombophlebitis/pulmonary embolism]. *Ugeskr Laeger* 2006;168(44):3824-5.
7. Estival JL, Debourdeau P, Zammit C, et al. [Spontaneous portal vein thrombosis associated with acute cytomegalovirus infection in an immunocompetent patient]. *Presse Med* 2001;30(38):1876-8.