

Brief report

Axenfeld-Rieger Syndrome Associated with Subdural Hematoma

Behrooz Koucheki, MD¹

1- Noor Ophthalmology Research Center, Noor Eye Hospital, Tehran, Iran

Correspondence to: Behrooz Koucheki, MD; bkouchaki@noorvision.com

Abstract

Purpose: In this report a patient with concomitant Axenfeld-Rieger syndrome and glaucoma is presented.

Results: New symptoms of a recent traumatic subdural hematoma were being attributed to his previously diagnosed conditions for several months.

Conclusion: Appropriate imaging saved the patient from more dangerous complications.

Keywords: Axenfeld-Rieger Syndrome, Glaucoma, Subdural Hematoma

Introduction

Patients with abnormal ocular development and glaucoma may have various complaints such as blurred vision, glare, and visual field defects. In the presence of such symptoms, a patient's complaints arising from new simultaneous disease may be underrated. Thorough review of history and new complaints could help to make a timely diagnosis.

Methods

A 28-year-old male patient presented with "blurry vision". The patient was a confirmed case of Axenfeld-Rieger syndrome and glaucoma, and had been using Xalatan and Timolol for several years. On the first examination, the visual acuity (VA) of the right eye was 1 meter CF, reaching $\frac{2}{10}$ with -6.00 diopter correction. Intraocular pressure (IOP) in the right eye was 14 mmHg. The left eye was NLP due to glaucomatous optic neuropathy.

Anterior segment examination showed large iris holes in the right eye, and posterior embryotoxon, corectopia and iris atrophy in both eyes (Figures 1 and 2). Gonioscopy showed high iris insertion and abnormal anterior chamber angle structure which was closed in most areas.

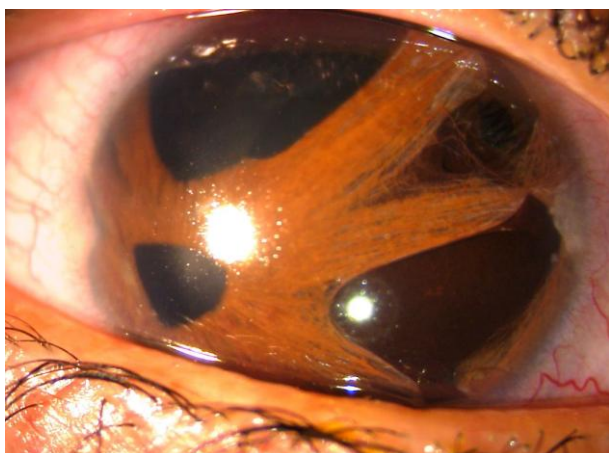


Figure 1. Slit photograph of anterior segment of the right eye, shows large iris holes, posterior embryotoxon and corectopia

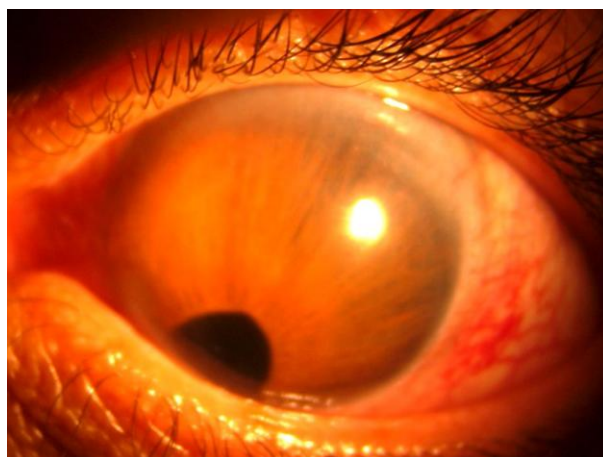


Figure 2. Slit photograph of anterior segment of the left eye, shows corectopia and posterior embryotoxon

Examination of the posterior segment indicated a pale optic disc with a vertical C/D ratio of 0.5 and chorioretinal atrophy in the right eye and total cupping in the left eye. Central corneal thickness in the right eye was 492 μ and visual field testing indicated quadrantanopia (Figure 3). The patient gave no history of headache, brain disease, or trauma. Brain MRI revealed a large subdural hematoma (Figure 4). During the second interview with an emphasis on head trauma or any previous problems, the patient recalled a mild head trauma about 4 months before. The patient was sent to the neurosurgery department for hematoma evacuation, after which, his vision was still $2/10$, but less blurry. One month later, his visual field was still the same as that before hematoma evacuation.




Figure 3. Visual field of the right eye shows quadrantanopia

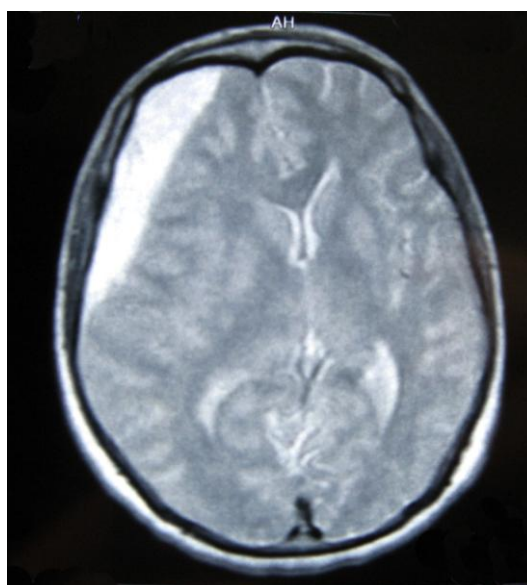


Figure 4. CNS imaging shows a large subdural hematoma

Discussion

Axenfeld-Rieger syndrome consists of a group of congenital anomalies characterized by abnormal development of the angle, iris, and trabecular meshwork. Ocular findings include anteriorly displaced Schwalbe's line (posterior embryotoxon), iridocorneal adhesions to Schwalbe's line, iris hypoplasia ranging from mild stromal thinning to atrophic holes, corectopia, and ectropion uvea. Glaucoma may develop in about 50% of cases.¹ In most cases, it is inherited in an autosomal dominant pattern.²

In the presented case, the patient was already diagnosed with Axenfeld-Rieger syndrome and glaucoma, but the visual field defect was not consistent with glaucomatous nerve fiber layer loss. Neuroimaging should be considered whenever the visual field defect is uncharacteristic for glaucoma,³ such as this case, in which it respected the vertical midline.

Patients with Axenfeld-Rieger syndrome should have periodical examinations for timely diagnosis of glaucoma and any coincident disorder. Encountering a distorted anterior segment and a diagnosis of glaucoma may distract clinicians from possible concomitant problems; they may relate new symptoms to anatomical abnormalities and miss associated problems in a busy clinic. For example, the new visual symptom in this patient was accounted for on the basis of his previous conditions. Detailed clinical examination, visual field testing, and brain MRI helped diagnose the underlying pathology and saved the patient from dangerous consequences.

Conclusion

Patient with glaucoma and abnormal eye structure, are more susceptible to underdiagnosis of other concurrent problems.

For instance, in the presented case underlying subdural hematomas signs and symptoms were camouflaged by concurrent Axenfeld-Rieger syndrome and glaucoma.

*: Financial support: None

References

1. Shields MB, Buckley E, Klintworth GK, Thresher R. Axenfeld-Rieger syndrome. A spectrum of developmental disorders. *Surv Ophthalmol* 1985;29(6):387-409.
2. Chisholm IA, Chudley AE. Autosomal dominant iridogoniodysgenesis with associated somatic anomalies: four-generation family with Rieger's syndrome. *Br J Ophthalmol* 1983;67(8):529-34.
3. Greenfield DS, Siatkowski RM, Glaser JS, et al. The cupped disc: who needs neuroimaging. *Ophthalmology* 1998;105(10):1866-74.