

Evaluation of Therapeutic Effect of Rifampin for Acute Central Serous Chorioretinopathy

Mohammad Rasoul Sabouri, MD¹ • Ehsan Kazemnezhad, MD²

Abstract

Purpose: Rifampin which is an anti-tuberculosis (TB) drug, can increase metabolism and thus reduce endogenous steroid. So it is mentioned as a probable drug for acute central serous chorioretinopathy (CSCR) treatment. Therefore we have decided to evaluate its beneficial effects in CSCR treatment.

Methods: A non-randomized clinical trial involving 39 patients with acute CSCR (less than two weeks) were studied. Initially, complete visual examinations including determination of spectacle best corrected visual acuity (SBCVA) using Snellen chart, anterior and posterior segment examinations were performed on all patients. Fundus fluorescein angiography (FA) and ocular coherence tomography (OCT) were performed to confirm the diagnosis. Twenty-three patients were treated with 600 mg rifampin per day up to maximum 4 to 6 weeks (treatment group) and 17 patients did not receive any treatment (control group). In the treatment group, one of the patients suffered from severe headache a few days after using the drug. So the drug was discontinued and the patient was excluded from the study. The patients were examined once in two weeks and totally up to fourth or sixth weeks. In each time of examination, the best clear visual acuity determination and funduscopy were done, and if necessary (cases of obvious macular edema) OCT was performed at the end of 4th to 6th week. Primary gain was reduction in macular thickness (MT) and secondary gain was the SBCVA during the study.

Results: The mean age of patients was 38.5±6.7 years. The mean age of the treatment group (37.7±6.2 years) was not significantly different from control group (39.7±7.3). Gender distribution shows that 76.9% of samples were male. In the treatment group, the average MT changed from 339.9±44.36 µm at the beginning of treatment to 297.4±29.09 µm at the end of treatment and this reduction in MT was equal to 12.58% (p<0.001) and in the control group, the initial and final thickness were 310.06±20.31 and 296.71±17.22, µm respectively. The reduction was equals to 4.3% (p<0.003). In the treatment group MT reduction was significantly more than the control group (p<0.018). In the treatment group, average of SBCVA before and after treatment was 0.2±0.18 and 0.6±0.34 Snellen visual acuity (SV), respectively (p<0.0001) and in the control group, this average was 0.2±0.1 before and 0.37±0.35 SV after treatment (p<0.024). The difference in SBCVA between two groups was more or less important (p=0.055). At the end of study, macula in 45.5% of the treatment group and 29.4% of control group had dried out Odd's Ratio (OR)=2 (0.52-7.6, CI: 95%) (p<0.307).

Conclusion: Rifampin has beneficial effects in the treatment of acute CSCR. These early findings suggest a novel treatment of CSCR and warranted further study.

Keywords: Rifampin, Central Serous Chorioretinopathy

Iranian Journal of Ophthalmology 2014;26(2):102-7 © 2014 by the Iranian Society of Ophthalmology

-
1. Assistant Professor of Ophthalmology, Amiralmomenin Hospital, Guilan University of Medical Sciences, Rasht, Iran
 2. Assistant Professor of Biostatistics, Amiralmomenin Hospital, Guilan University of Medical Sciences, Rasht, Iran

Received: March 8, 2014

Accepted: July 23, 2014

Correspondence to: *Mohammad Rasoul Sabouri, MD*

Assistant Professor of Ophthalmology, Eye Research Center, Amiralmomenin Hospital, Guilan University of Medical Sciences, Rasht, Iran, Email: r_sabouri2002@yahoo.com

Introduction

Central serous chorioretinopathy (CSCR) which will be called CSCR thereafter is a disease of young and middle aged people and is seen mainly in 20-50 year old men that some people are suffering from it and it is serous and regional detachment of retina in the posterior pole. Commonly, clinical manifestation is in one eye but in 18% of cases both eyes are involved. Even in some reports 30% of bilaterality has been reported.¹ Studies have shown that the lesion is diffusible and includes a bilateral retinochoroidal disorder although its clinical manifestation is observed in one eye. The etiology of the disease is unknown but it is postulated that the choroidal circulation disorder, would cause interference in surface pigmented epithelium layer function.² Fluorescein angiography (FA) shows one or some points of leakage in pigmented layer that leads to sensory retina detachment. Blocking the leakage by laser spots results in resolving of sensory retinal detachment. The angiographic findings indicate that defect in cellular tight junctions of pigmented layer leads the choroidal leakage to the subretinal space.³

Treatment of acute CSCR, except for limited cases, is follow-up of the patient for a period of 2-3 months that about which there is a consensus.³ But in some cases there is necessity for therapy such as use of laser therapy, acetazolamide, beta-blockers, Photodynamic therapy, ketoconazole, anecortave acetate, 577 nm yellow laser and Avastin and recently rifampin, all because of their anti-corticosteroid effects. The therapeutic impacts on CSCR have been known accidentally.

In 2010, Ravage group at the annual meeting of the American Society of Retina Specialist, in Chicago, presented a patient who had widespread chorioretinal lesions and serous macular detachment that it could be either due to chronic CSCR or latent tuberculosis (TB). Therefore, the patient underwent anti-TB standard multi-drug treatment and it was observed that the macular edema subsided, but when medication therapy was discontinued, the edema recurred and when the treatment resumed with the previously used drugs, the edema subsided again and by discontinuing

medication therapy once again, recurrent edema took place. On the basis of this fact, it was thought that serous retinopathy didn't result from TB in the patient but it could be from the chronic CSCR and one of the anti TB drugs involved in the treatment must have positive and independent anti serous retinopathy effects. So anti-TB drugs list was considered and it was concluded that rifampin is the only drug of this group that has ability to reduce endogenous corticosteroid and could decrease serous retinopathy. Consequently, this group (Packo) treated several patients with rifampin with the dosage of 600 mg/day in the period of 1-4 weeks that led to recovery and so it was concluded that rifampin may be helpful in treatment of CSCR especially its chronic form.⁴

According to above-mentioned report and a few conducted studies, it was decided that a clinical study on therapeutic effects of rifampin on acute CSCR to be performed which is presented here.

Methods

In a non-randomized clinical trial, 39 patients with acute CSCR (less than 2-3 weeks) were studied. Initially, complete visual examinations including determination of spectacle best corrected visual acuity (SBCVA) using Snellen Chart, anterior and posterior segment examinations were performed on all patients. Then the disease was confirmed by conducting FA and ocular coherence tomography (OCT) with spectral domain HD-CIRROUS (Carl Zeiss Meditec). The patients were voluntarily divided into treatment and control groups. Treatment group included 23 patients treated with 600 mg rifampin per day within 4-6 weeks and 17 patients did not receive any treatment (control group). It is clear that evaluation of hepatic enzymes, serum bilirubin, serum creatinine, corpuscular and platelet count have been performed before prescribing drug. In the treatment group, one of the patients got severe headache a few days after therapy that led to discontinuation of the drug, and the patient was excluded from the study. The patients were examined once in two weeks and totally up to fourth to sixth weeks. In each time of examination, the best corrected visual acuity (BCVA) determination and funduscopy was

done. If any macular edema was observed in funduscopy, OCT was performed, otherwise OCT was done at the end of 4th to 6th week. Primary and secondary gain was reduction in thickness of macula and the BCVA, respectively in the end of the study.

Statistical analysis

In this work, study quantitative variables [SBCVA & macular thickness (MT)] were considered in the light of following normal distribution on the basis of Kolmogorov-Smirnov test initially. Then, paired *t*-tests were used in order to studying SBCVA and MT quantitative variations and the group separation. Independent *t*-test was used for comparing variation means between two groups. χ^2 test compared sub-fovea residues in the end of the study in two groups.

Significance level of the tests in statistical difference was determined with $p < 0.05$ and the tests were done as two-tailed.

Results

Twenty-three and 17 patients were studied in the treatment and control group, respectively. The mean age of patients was 38.5 ± 6.7 with range of variation of 25 years (28-53 years). Seventy-five percent of samples were under 44-year-old.

The mean age of the treatment group (37.7 ± 6.2 years) wasn't significantly different from control group (39.7 ± 7.3). Gender distribution showed that 76.9% (N=30) and 23.1% (N=9) of samples were males and females, respectively. Gender distribution in two groups had no significant difference (in the treatment group, 82.4% and in the control group, 72.7% of the samples were males).

In the light of assessing MT area change, the study results showed that in the treatment group, initial MT average changed from

$339.9 \pm 44.36 \mu\text{m}$ to $297.4 \pm 29.09 \mu\text{m}$ at the end of treatment and this reduction in MT (42.77 ± 51.78) was equal to 12.58% that is statistically significant ($p < 0.001$). In the control group, they were 310.06 ± 20.31 and $296.71 \pm 17.22 \mu\text{m}$, respectively and this reduction (13.35 ± 15.44) was equal to 4.3% which was also significant ($p < 0.003$).

Comparing mean MT changes in two groups, 12.58% reduction in the treatment and 4.3% in control group, (equals to $\frac{1}{3}$ of change in the treatment group), the difference was statistically significant ($p < 0.018$) (Figure 1).

In the treatment group, evaluating visual acuity changes, statistical analysis showed that SBCVA mean at the beginning and end (4-6 weeks later) of the study was 0.2 ± 0.18 Snellen visual acuity (SV) and 0.6 ± 0.34 SV, respectively, i.e. which had increased 0.4 ± 0.3 ($p < 0.0001$). In the control group, these variations mean has been 0.2 ± 0.1 SV and 0.37 ± 0.35 SV ($p < 0.024$) (Figure 2), showing that visual improvement was significant in both groups, but comparing variations mean of SBCVA in both groups with regard to 0.4 ± 0.3 increase in the treatment group mean and 0.2 ± 0.1 increase in the control group and 0.2 ± 0.1 SV difference between these two groups, the improvement was more in the treated group ($p = 0.055$).

In the evaluation of macular conditions at the end of our study to determine whether there was any residual fluid (RF) or no fluid (NF), χ^2 statistical analysis showed that macula in 45.5% (N=9) of treatment and 29.4% (N=5) of control group was dry (NF). Odd's Ratio (OR)=2 (with CI=95%, 0.52-7.6) and ($p < 0.307$) (Figure 3).

In the treatment group, all the patients with dry macula at the end of study were followed for nine months and no recurrence of the lesion was observed.

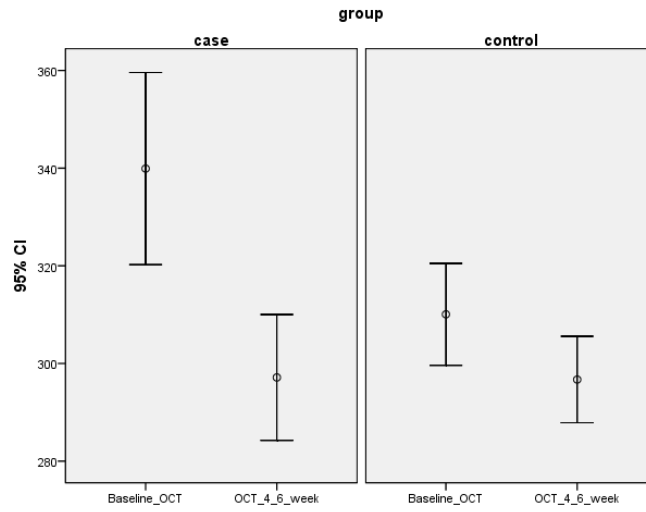


Figure 1. Mean macular thickness change in each and between two group ($p<0.018$)

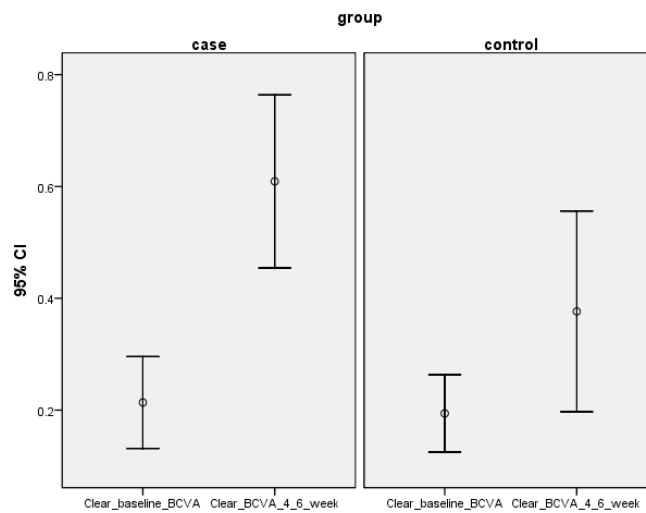


Figure 2. Mean best corrected visual acuity change in each and between two group ($p=0.055$)

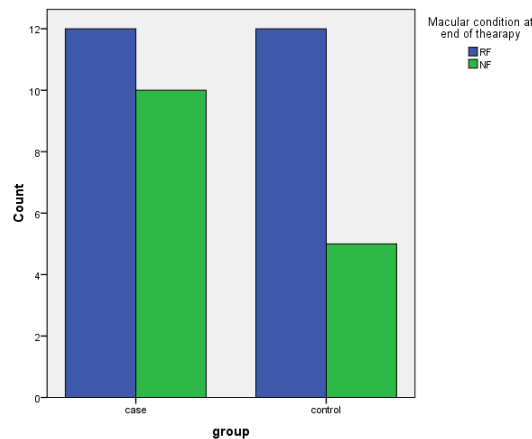


Figure 3. Macular condition at end of therapy

Discussion

CSCR is an acquired disease with serous detachment of sensory retina or pigmented layer at the macular area and its pathogenesis is not elucidated well,⁵ however, in recent years, ICG (Indocyanin angiography) threw light on CSCR theory. ICG has shown some changes in permeability of choroidal vessel walls.⁶ In other word, the patients with CSCR may show some increase in fragility of choroidal vessels and pigmented layer to steroid or epinephrine that leads to vessel contraction and ischemia and increasing permeability resulted from these substances. In these conditions, increasing protein exudates leakage into outside vascular space due to vessel walls permeability change, causes increase oncotic pressure and this interferes with intercellular junctions of pigmented layer that results in exudates leakage from this layer.⁷

CSCR has been shown to be associated with stress and its related hormones (epinephrine and corticosteroids). People with Type A personalities who are subjected to tension are more susceptible to CSCR. Also, there is numerous evidence that suggested that people receiving corticosteroid even in the topical form, and patients having high level of corticosteroid (like cushing syndrome), and individuals having excessive epinephrine such as patients with obstructive sleep apnea and hypertension are vulnerable to CSCR.⁷ Therefore, with regard to possible role in pathogenesis of CSCR, the use of inhibitor drugs has been suggested as a probable solution in treatment⁸ like ketoconazole and anecortave acetate and rifampin.

There is not enough information about ketoconazole. In a report on four patients with chronic CSCR, due to limitations of the study, the results were not conclusive and therefore further studies are needed. This medicine is a corticosteroid antagonist. The reason for using the drug is that it is thought CSCR is associated with hypercorticism. Therefore, it is suggested that cortisol-lowering drugs such as ketoconazole be used in order to treat CSCR.⁹

Regarding anecortave acetate that is an anti-glucocorticoid drug, a study is underway and so far the results have not been reported.¹⁰ The reason for using the drug is nearly similar to ketoconazole. On the basis of that it is said that increased cortisol levels are

associated with pathogenesis of CSCR. Hypercorticism whether exogenous like oral taking and intravenous injection and even spray inhalation or endogenous like Cushing's syndrome, increase the risk of CSCR. So anecortave acetate that is the derivative of cortisol but with changes in the its composition and structure by removing 1 β -hydroxyl group and adding to the C9-11 bond and also acetate groups in C21, its corticosteroid effects are eliminated and its stability and intraocular penetration increases, thereby it can be useful in the treatment of chronic CSCR. However, as noted, the studies results on using this drug have not yet published.¹⁰

Rifampin whose effects in the treatment of CSCR revealed accidentally⁴ is an anti-TB drug. Its primary mechanism of action is inhibition of DNA-dependent RNA polymerase, blocking RNA transcription. It is a cytochrome P450, 3A4 inducer. Cytochrome P450, 3A4 is a member of the cytochrome P450 superfamily of enzymes, which catalyse many reactions involved in drug metabolism and synthesis of cholesterol, steroids, and other lipids. Thus, it is postulated that induction of cytochrome P450, 3A4 increases metabolism of endogenous steroids, leading to improvement of CSCR manifestations.⁸

Concerning rifampin effects on CSCR treatment that were reported as a case report for the first time by Packo et al at the American Society of Retina Specialist Annual Meeting in 2010, sufficient studies have not been performed and reports have been more around case reports or around a few patients and so, present study is the largest and most extensive report all over the world that has experienced the effects of rifampin in 22 patients.

Steinle et al have reported a 65 year old patient who was referred after cataract surgery due to lack of adequate vision. It was found in the examination that the patient was suffering from chronic CSCR in both eyes from two preceding years. Therefore, the patient was treated with rifampin in a period of one month and sub-foveal fluid was absorbed completely in both eyes.⁸

Ravage et al studied the therapeutic effects of the drug on four patients. CSCR active time in these patients ranged from less than a month to more than a year, all patients were

male with a mean age of 50 years. The patients were treated for four weeks. The average thickness change of CMT was -99 ($167 \pm \text{SD}$) in the first week, and -102 ($215 \pm \text{SD}$) in the eighth week- 93 ($91 \pm \text{SD}$) in the twelfth week and the visual gain has been from zero to ≥ 3 lines.⁴

In this study, sub-foveal fluid absorption in both groups took place significantly comparing the initial and final results. This means that in all conditions, whether with the help of therapy or without it, the fluid absorption happens, but with regard to significant absorption rate (MT variations) in the treatment group that was three times as much as control group ($p < 0.018$), this result indicated that rifampin caused fluid absorption to accelerate and caused more rapid recovery. Also, visual acuity increases significantly in both groups comparing the initial and end results. In treated and non-treated cases visual acuity changed, however, the recovery in the treatment group was twice as much as the control group which was more or less significant ($p = 0.055$).

At the end of the study (weeks 4-6) in the treatment group near by in half of the patients, macula was dry and considering the Odd's $R=2$ in the treatment group, the patients number with dry macula was twice as many as the control group; however, not being statistically significant ($p < 0.307$). In regard to significant alteration in MT and slight alteration in SBCVA the results could be considered positive. Longer duration of treatment may give better results.

All the patients with dry macula (in the treatment group) showed stability and no relapse of the lesion was reported after nine months of follow-up.

Conclusion

Limitations of this study are lack of random selection of samples. It is recommended that a randomized study with a larger sample is accomplished. Rifampin accelerates

sub-foveal fluid absorption and increases anatomical and functional success. It has beneficial effects in the treatment of acute CSCR. So it is advised if there is no any contraindication, rifampin may be used for management of acute CSCR.

References

1. Taban M, Boyer DS, Thomas EL, Taban M. Chronic central serous chorioretinopathy: photodynamic therapy. *Am J Ophthalmol* 2004;137(6):1073-80.
2. Mehany SA, Shawkat AM, Sayed MF, Mourad KM. Role of Avastin in management of central serous chorioretinopathy. *Saudi J Ophthalmol* 2010;24(3):69-75.
3. Klais CM, Ober MD, Ciardella AP, Yannuzzi LA. Central serous chorioretinopathy. In: Ryan SJ, Hinton DR, Schachat AP, Wilkinson P, editors. *Retina*. 4th Edition. Vol. 2. Philadelphia, Pa, USA: Elsevier Mosby; 2006:1135-61.
4. Ravage ZB, Packo KH, Catherine C, Pauline MT. Chronic central serous chorioretinopathy responsive to rifampin. *RETINAL Cases & Brief Reports* 2012;6(1):129-32.
5. Forooghian F, Meleth AD, Cukras C, Chew EY, Wong WT, Meyerle CB. Finasteride for chronic central serous chorioretinopathy. *Retina* 2011;31(4):766-71.
6. Li XJ, Zhang JS. Intravitreal bevacizumab injection for chronic central serous chorioretinopathy. *Chin Med J (Engl)* 2010;123(15):2145-7.
7. Colucciello M. Central serous retinopathy. *Retinal Physician* 2010. Available from url: <http://www.retinalphysician.com/articleviewer.aspx?articleID=104009>.
8. Steinle NC, Gupta N, Yuan A, Singh RP. Oral rifampin utilisation for the treatment of chronic multifocal central serous retinopathy. *Br J Ophthalmol* 2012;96(1):10-3.
9. Meyerle CB, Freund KB, Bhatnagar P, Shah V, Yannuzzi LA. Ketoconazole in the treatment of chronic idiopathic central serous chorioretinopathy. *Retina* 2007;27(7):943-6.
10. Manhattan Eye, Ear & Throat Hospital. NewYork. Treatment of chronic central serous chorioretinopathy with open-label anecortave acetate (CSC-AA). 2012. available at <http://clinicaltrials.gov/show/NCT00489840>.